

Picture of the Month

Alfredo Salinas, MS; Cesar Escamilla, MD; Gerardo Rivera, MD; Hector R. Martinez, MS

A 16-YEAR-OLD GIRL PRESENTED WITH A 3-week history of gingival pain and inflammation; mastication exacerbated the pain. She denied having experienced bleeding, rash, or fever. At the age of 1 year, the patient had a developmental hip dislocation that required surgical treatment.

Physical examination revealed a generalized tan pigmentation of the skin, micrognathia, microcephaly, the absence of the fifth finger on both hands, and growth retardation (height, 138 cm; weight, 26 kg; below the third percentile). An oral examination revealed prolonged retention of deciduous teeth and noneruption of permanent teeth, patchy brown discoloration of the tongue (**Figure 1**), and brown gums with smooth surface texture and generalized inflammation (**Figure 2**). Laboratory studies revealed a hemoglobin level of 8 g/dL (normal range, 11.0-16.0 g/dL [to convert to grams per liter, multiply by 10.0]), a mean corpuscular volume of 100 μm^3 or more (to convert to femtoliters, multiply by 1.0), a neutrophil count of 1100/ μL (normal range, 2000-

8030/ μL [to convert to $\times 10^9/\text{L}$, multiply by 0.001]), and a platelet count of $35\,000 \times 10^3/\mu\text{L}$ (normal range, $150\,000\text{-}300\,000 \times 10^3/\mu\text{L}$ [to convert to $\times 10^9/\text{L}$, multiply by 1.0]). A panoramic dental radiographic scan shows the noneruption of permanent teeth (**Figure 3**). The bone marrow biopsy confirmed marrow hypoplasia.

What is your diagnosis?

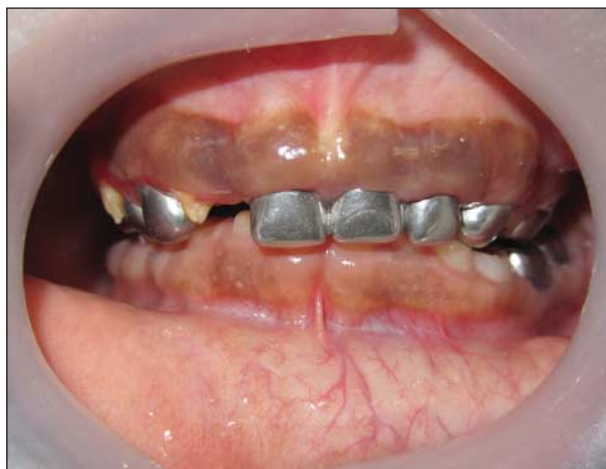

Figure 2. Photograph showing brown abnormalities of the gums of a 16-year-old girl.

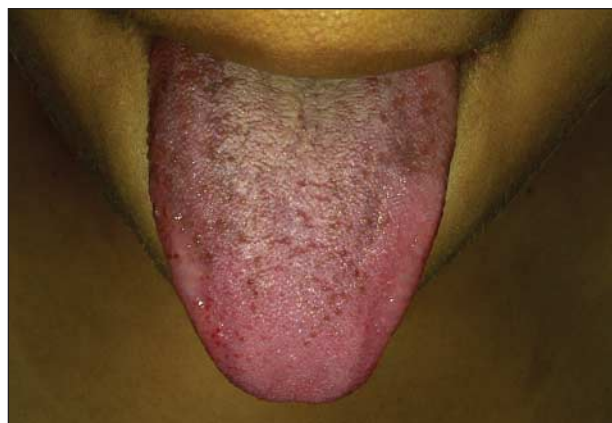


Figure 1. Photograph revealing small pigmented areas of the tongue of a 16-year-old girl.

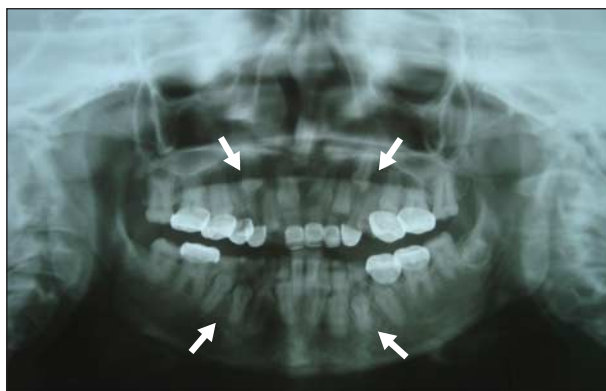


Figure 3. Panoramic dental radiographic scan showing the unerupted teeth of a 16-year-old girl.