

# Denouement and Discussion

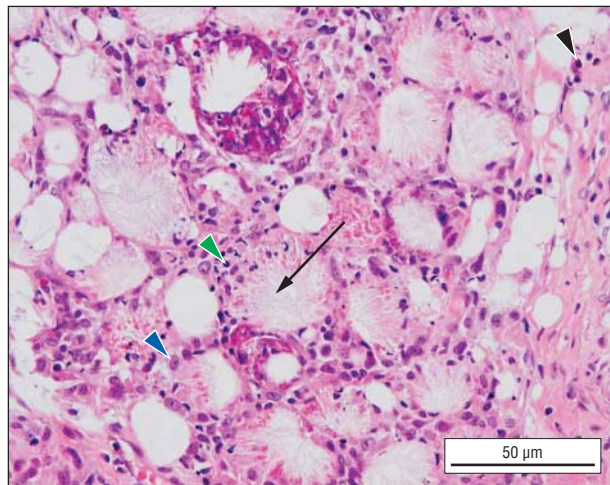
## Subcutaneous Fat Necrosis of the Newborn

**H**istologic examination of the skin biopsy revealed septal and lobular inflammatory infiltrate of lymphocytes, plasma cells, histiocytes, and a few eosinophils wedged in between the subcutaneous fat cells. The fat cells contain fine eosinophilic cytoplasmic strands forming clefts (**Figure 2**). These findings were diagnostic of subcutaneous fat necrosis of the newborn (SCFN). The clinical features in this patient also supported the diagnosis. Subcutaneous fat necrosis of the newborn is either single or multiple well-circumscribed, erythematous, indurated, nodular areas of fat necrosis. It is usually painless but occasionally tender. The common sites of occurrence include the cheeks, back, buttocks, arms, and thigh.

Subcutaneous fat necrosis of the newborn is a rare disorder. Predisposing factors include (1) maternal gestational diabetes mellitus, preeclampsia, or cocaine or calcium blocker use; (2) delivery complications including hypothermia, hypoxemia, infections, or cutaneous trauma; and (3) newborn anemia or thrombocytosis.<sup>1</sup> The most frequently recognized possible etiologic factor in a series of 11 patients by Burden and Krafchik<sup>2</sup> was birth asphyxia and meconium aspiration.

The pathogenesis of SCFN is still unknown. Owing to its composition, neonatal fat has a greater propensity to undergo crystallization during cold stress, with consequent adipocyte necrosis. Other proposed mechanisms include immaturity of the enzymatic systems involved in fatty-acid metabolism and hypoxic injury to subcutaneous fat owing to local trauma during delivery.<sup>3</sup>

Subcutaneous fat necrosis of the newborn occurs during the first few days to weeks of life.<sup>1</sup> Definitive diagnosis is made by skin biopsy, which shows needle-shaped clefts within fat cells and foamy histiocytes, fat necrosis and granulomatous infiltrate of lymphocytes, and histiocytes and multinucleated giant cells.<sup>4</sup>(pp215-216) Sometimes the clinical features and examination findings are adequate for a diagnosis of SCFN. However several conditions appear clinically similar to SCFN such as sclerema neonatorum, cellulitis, histiocytosis, and sarcoma.



**Figure 2.** Skin biopsy specimen showing septal and lobular inflammatory infiltrate of lymphocytes (green arrowhead), plasma cells, histiocytes (blue arrowhead), and a few eosinophils (black arrowhead) wedged in between the fat cells in subcutaneous fat. Fat cells contain fine, eosinophilic cytoplasmic strands forming clefts (arrow) (hematoxylin-eosin, original magnification  $\times 40$ ).

If the diagnosis of SCFN is in doubt, histological diagnosis is mandatory.<sup>5</sup>

Subcutaneous fat necrosis of the newborn is usually self-limited. Rare life-threatening complications include hypercalcemia. The mean time from the development of SCFN lesions to the diagnosis of hypercalcemia is 24 days, and it resolves within 6 weeks after diagnosis. The hypercalcemia is mostly moderate ( $<3$  mmol/L) and without clinical symptoms. However, kidney calcium deposits occur. High blood calcium levels can be detected up to 3 months after diagnosis. Therefore, the authors recommend systematic monitoring of calcium levels for 2 to 3 months in newborns with SCFN. The pathogenesis of hypercalcemia may include extrarenal production of 1,25-dihydroxyvitamin D3 by macrophages stimulating intestinal calcium uptake,<sup>2,3</sup> elevated prostaglandin E stimulating bone resorption,<sup>6</sup> and calcium released from the resolving subcutaneous plaque.<sup>3</sup> Other complications include dyslipidemia, thrombocytopenia, hypoglycemia, and, rarely, progression to subcutaneous atrophy.

Treatment is aimed at prevention and management of the complications. Parents should be warned of the early signs of hypercalcemia such as lethargy, irritability, hypotonia, vomiting, polyuria, polydipsia, and dehydration. Analgesia is given if the lesion is painful. If the fat liquefies, aspiration of fluctuant material is done for decompression, but this is seldom required.<sup>7</sup> Treatment of hypercalcemia includes intravenous hydration and furosemide. Corticosteroids, calcitonin, and bisphosphonate may be needed.<sup>7,8</sup>

Accepted for Publication: August 3, 2010.

Correspondence: Ng Su Yuen, MRCPch, Paediatric Dermatology Unit, Institute Pediatrik, Hospital Kuala Lumpur, Jalan Pahang, Kuala Lumpur, Wilayah Persekutuan, Malaysia 50586 (ngsy2002@yahoo.com).

Author Contributions: Study concept and design: Yuen and Ibrahim. Acquisition of data: Yuen. Analysis and interpretation of data: Yuen. Drafting of the manuscript: Yuen. Critical revision of the manuscript for important intellectual content: Yuen and Ibrahim. Administrative, technical, and material support: Yuen. Study supervision: Yuen and Ibrahim. Financial Disclosure: None reported.

## REFERENCES

1. Mahé E, Girszyn N, Hadj-Rabia S, et al. Subcutaneous fat necrosis of the newborn. *Br J Dermatol*. 2007;156(4):709-715.
2. Burden AD, Krafchik BR. Subcutaneous fat necrosis of the newborn: a review of 11 cases. *Pediatr Dermatol*. 1999;16(5):384-387.
3. Borgia F, De Pasquale L, Cacace C, Meo P, Guarneri C, Cannavo SP. Subcutaneous fat necrosis of the newborn: be aware of hypercalcaemia. *J Paediatr Child Health*. 2006;42(5):316-318.
4. Rapini RP. *Panniculitis in Practical Dermatopathology*. St Louis, MO: 2005.
5. López V, Alonso V, Rayón JM, Monteagudo C, Jordá E. Usefulness of fine-needle aspiration in subcutaneous fat necrosis of the newborn diagnosis. *Pediatr Dermatol*. 2010;27(3):317-318.
6. Sharata H, Postellon DC, Hashimoto K. Subcutaneous fat necrosis, hypercalcemia, and prostaglandin E. *Pediatr Dermatol*. 1995;12(1):43-47.
7. Tran JT, Sheth AP. Complications of subcutaneous fat necrosis of the newborn: a case report and review of the literature. *Pediatr Dermatol*. 2003;20(3):257-261.
8. Rice AM, Rivkees SA. Etidronate therapy for hypercalcemia in subcutaneous fat necrosis of the newborn. *J Pediatr*. 1999;134(3):349-351.