Denouement and Discussion

Ewing Sarcoma

Plain radiographs of the right hip showed a large, round, soft-tissue density overlying the right iliac bone. Pelvic magnetic resonance imaging demonstrated heterogeneous signal enhancement within the right iliac bone extending into the sacroiliac joint and lateral aspect of the right sacrum with associated irregular periosteal reaction and destructive lesions. The soft-tissue component extended into the surrounding tissues, including L5 to S1, without invading the spinal canal and measured approximately 17 × 9.4 × 9.0 cm (**Figure 2**). Because primary bone malignancy was suspected, a biopsy of the right iliac lesion was performed; pathology revealed Ewing sarcoma. Subsequent evaluation to determine the extent of disease included a bone marrow biopsy, full-body bone scan, and a chest computed tomography. The bone marrow biopsy specimen showed normocellular marrow without evidence of tumor. Bone scan showed an active osteoblastic process isolated to the right iliac bone and sacroiliac joint, without evidence of metastatic bone disease. The computed tomograph of the chest showed mediastinal lymphadenopathy with multiple pulmonary nodules consistent with hematogenous spread of malignancy.

Primary bone tumors are the sixth most common neoplasm in children, with Ewing sarcoma being the second most common bone tumor in children.[1] Median age of presentation is 15 years, but Ewing sarcoma has been reported in all age groups. Ewing sarcoma is slightly more common in males.[2] This malignancy may affect any bone, with those of the lower extremity being the most common sites of origin (45%) followed by pelvic involvement in 20% to 27% of cases.[1] At the time of diagnosis, 26% to 28% of patients have metastatic disease, most commonly to the lungs, bones, and bone marrow.[3]

Patients typically present with localized pain and swelling and occasionally a palpable soft-tissue mass. Up to 28% of patients will have constitutional symptoms (ie, fever, weight loss, and malaise).[1] Patients with large pelvic tumors may have bowel or bladder dysfunction, while paraspinal tumors may cause back pain and neurologic impairment, and thoracopulmonary tumors (Askin tumors) usually present with respiratory symptoms.[4] A delay in diagnosis is common with Ewing sarcoma, as symptoms are nonspecific and physical examination findings are often limited until tumor bulk is significant.

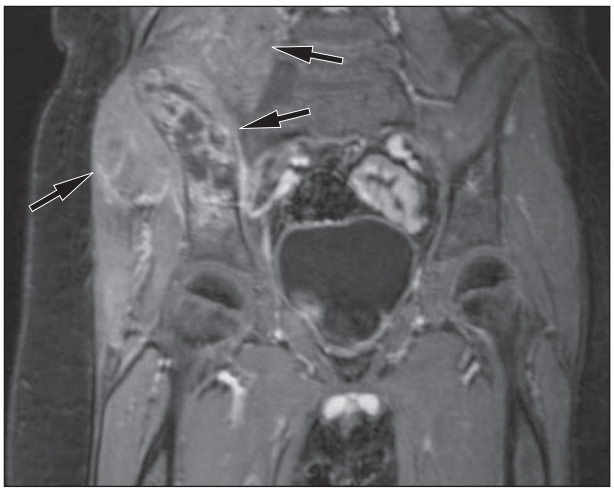

Figure 2. Magnetic resonance T2-weighted coronal image of the pelvis demonstrating a large heterogeneous destructive mass of the right iliac bone with significant soft tissue extension, without invasion of vertebral bodies. Arrows indicate heterogeneous destructive mass of the right iliac bone with significant soft-tissue extension.

Laboratory study evaluation is also nonspecific; patients may have elevations of the erythrocyte sedimentation rate, lactate dehydrogenase levels, or white blood cell count. On plain radiographs, Ewing sarcoma appears as an ill-defined, mottled, moth-eaten, destructive bone lesion, with periosteal reaction resembling an onion skin, and an associated soft-tissue mass.[5] All patients require thorough evaluation for additional tumor burden to guide appropriate intervention. Magnetic resonance imaging evaluation helps to assess tumor size. Computed tomography of the chest is the best method to evaluate for metastatic disease, while a full-body bone scan assists in detection of skin lesions near the primary lesion and distant bone metastases. Bone marrow biopsy is recommended to exclude widespread metastatic disease of the bone marrow.

Metastatic disease is the most unfavorable prognostic feature of Ewing sarcoma. Patients with isolated pulmonary metastases have a slightly better outcome than those with bone or bone marrow metastases at initial diagnosis.[3] Due to the high rate of metastatic disease at diagnosis, most patients are initially treated with neoadjuvant systemic multidrug chemotherapy, followed by local surgical resection, radiotherapy, or both. At 5 years after diagnosis, overall survival for patients with localized disease is 82%, while it is only 39% in those with metastases.[4]

This article highlights the importance of including oncologic processes in the differential diagnosis of children with limb pain, limp, or both to allow for prompt diagnosis and initiation of therapy given the potential morbidity and mortality of advanced disease.

Accepted for Publication: July 22, 2010.
Correspondence: Eron Y. Friedlaender, MD, MPH, Division of Emergency Medicine, The Children's Hospital of Philadelphia, 34th and Civic Center Blvd, Philadelphia, PA 19104 (friedlaender@email.chop.edu).
Financial Disclosure: None reported.
Additional Contributions: Victor Ho, MD, Department of Radiology at the Children's Hospital of Philadelphia, assisted with the radiographic images.

REFERENCES

1. Grier HE. The Ewing family of tumors: Ewing's sarcoma and primitive neuroectodermal tumors. *Pediatr Clin North Am*. 1997;44(4):991-1004.
2. Gurney JG, Swensen AR, Bulterys M. Malignant bone tumors. In: Ries LAG, Smith MA, Gurney JG, et al, eds. *Cancer Incidence and Survival Among Children and Adolescents: United States SEER Program 1975-1995*. Bethesda, MD: National Cancer Institute, SEER Program; 1999:99-110. NIH Publication 99-4649.
3. Esiashvili N, Goodman M, Marcus RB Jr. Changes in incidence and survival of Ewing sarcoma patients over the past 3 decades: Surveillance Epidemiology and End Results data. *J Pediatr Hematol Oncol*. 2008;30(6):425-430.
4. Maheshwari AV, Cheng EY. Ewing sarcoma family of tumors. *J Am Acad Orthop Surg*. 2010;18(2):94-107.
5. Morrissy R, Weinstein S. *Lovell and Winter's Pediatric Orthopaedics*. 6th ed. Philadelphia, PA: Lippincott Williams & Wilkins; 2006:530-531.

©2011 American Medical Association. All rights reserved.
Downloaded From: http://archpedi.jamanetwork.com/ on 04/27/2017