

Picture of the Month

Risa M. Small, MD; Eron Y. Friedlaender, MD, MPH

A PREVIOUSLY HEALTHY 6-YEAR-OLD BOY PRESENTED to the emergency department (ED) with 2 weeks of progressive right leg pain and a limp. He reported pain only when bearing weight or with extension of his right knee, although his parents noted he had been waking from sleep in pain. He denied a history of trauma and had not experienced joint swelling or erythema. He had not had fever, weight loss, or recent infections and confirmed normal voiding patterns. Our patient saw his pediatrician for this same concern 3 days before our evaluation and was found to have a minimally elevated

erythrocyte sedimentation rate and normal lower extremity plain radiographs. In the ED, he was well-appearing and afebrile with normal vital signs for age. He held his right knee in mild flexion and refused to ambulate secondary to pain. The findings of a physical examination confirmed a full range of motion of the right hip and ankle. No joint instability, deformity, or swelling of his leg was noted, although he had mild swelling and tenderness over his right posterior iliac crest. Laboratory results were significant for C-reactive protein, 2.2 mg/L (to convert to nanomoles per liter, multiply by 9.524), erythrocyte sedimentation rate, 30 mm/h, and normal complete blood cell count with a normal manual differential cell count.

Plain radiographs of the hip and right femur were obtained. (**Figure 1**)

What is your diagnosis?

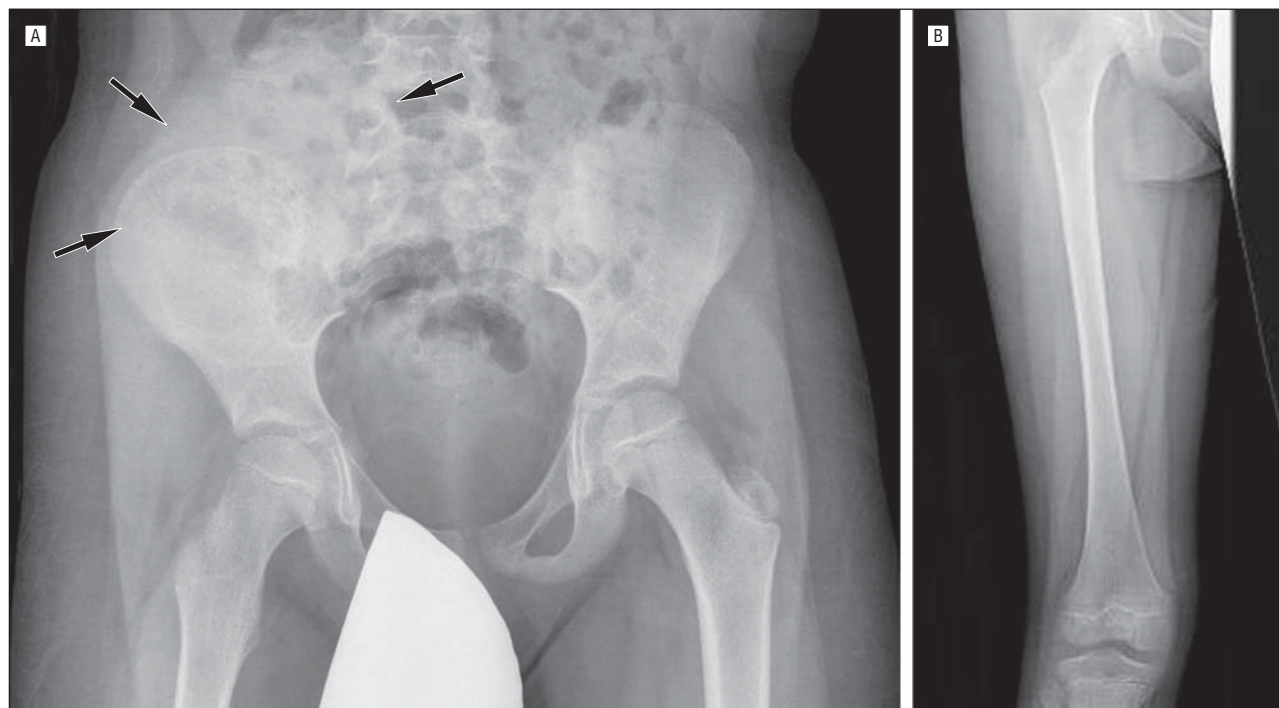


Figure 1. Anteroposterior views of the pelvis (A) and right femur (B). Arrows indicate soft-tissue density overlying the right iliac bone.