

## Picture of the Month

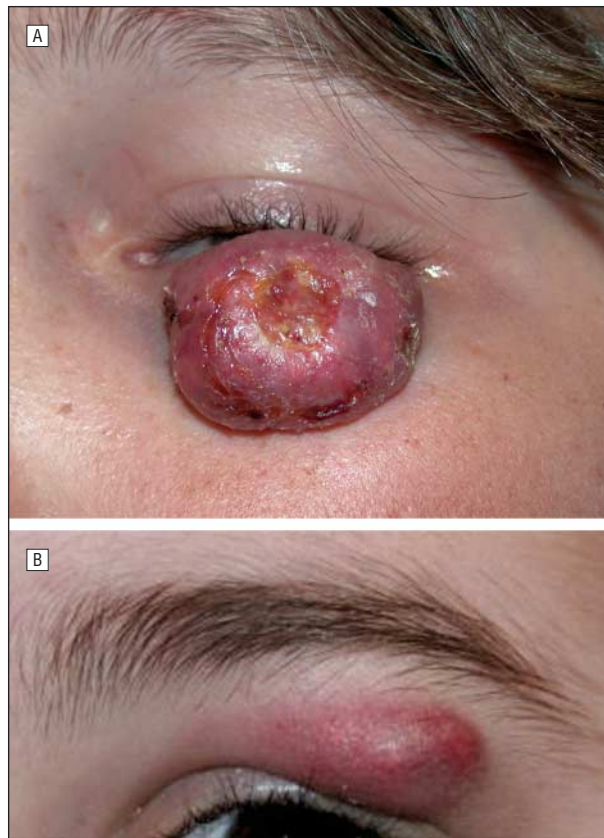
Leslie Castelo-Soccio, MD, PhD; William R. Katowitz, MD; James A. Katowitz, MD;  
Kara N. Shah, MD, PhD; James R. Treat, MD; Albert C. Yan, MD

**A** PREVIOUSLY HEALTHY 14-YEAR-OLD GIRL HAD a large but asymptomatic lesion on the left lower eyelid margin (**Figure 1 A**). She had first noted a small papule that gradually and progressively grew over 5 months. She also noticed that the lesion had grown after minor trauma. On physical examination, the lower eyelid lesion was a firm, pink,  $28 \times 19 \times 15$ -mm nodule with central ulceration and crust. The remainder of the skin examination results were normal.

An otherwise healthy 10-year-old boy had a large and growing asymptomatic lesion on the left upper eyelid (**Figure 1B**). He had noted a small, bluish papule 2 months previously; the lesion had grown following trauma when he was hit in the ipsilateral eye by a dodgeball. On physical examination, the upper eyelid lesion was a firm, pink,  $25 \times 12 \times 6$ -mm nodule with overlying telangiectasias. He had smaller but similar-appearing lesions on his right foot and left upper arm. The remainder of the skin examination results were normal.

**Author Affiliations:** Section of Dermatology (Drs Castelo-Soccio, Shah, Treat, and Yan) and Division of Ophthalmology (Drs W. R. Katowitz and J. A. Katowitz), Children's Hospital of Philadelphia, University of Pennsylvania School of Medicine, Philadelphia.

See <http://www.archpediatrics.org> for the Picture of the Month Web Quiz: What is your diagnosis?



**Figure 1.** Nodules involving eyelids. A, Patient 1, a 14-year-old girl, with a large ulcerated nodule involving the left lower eyelid. B, Patient 2, a 10-year-old boy, with an inflamed nodule involving the left upper eyelid.