

Thyroid Nodules and Cancer in Children and Adolescents Affected by Autoimmune Thyroiditis

Andrea Corrias, MD; Alessandra Cassio, MD; Giovanna Weber, MD; Alessandro Mussa, MD; Malgorzata Wasniewska, MD; Anna Rapa, MD; Roberto Gastaldi, MD; Silvia Einaudi, MD; Federico Baronio, MD; Maria Cristina Vigone, MD; Maria Francesca Messina, MD; Milva Bal, MD; Gianni Bona, MD; Carlo de Sanctis, MD; for the Study Group for Thyroid Diseases of the Italian Society for Pediatric Endocrinology and Diabetology (SIEDP/ISPED)

Objective: To investigate the association between juvenile autoimmune thyroiditis (JAT) and thyroid cancer in pediatric patients.

Design: We conducted a retrospective study among children and adolescents affected by JAT.

Settings: Data from 6 Italian pediatric endocrinology centers were collected.

Participants: Three hundred sixty-five children and adolescents affected by JAT diagnosed at 3.6 to 17.0 years of age.

Interventions: All patients underwent clinical examination and thyroid function test every 6 to 12 months and thyroid echography every 12 to 24 months. Fine-needle aspiration biopsy was performed in 39 patients with nodule diameter of 1 cm or larger, as well as in 4 patients with nodule diameter of less than 1 cm and echographic findings suspicious for neoplasm. Twenty-three patients underwent surgery.

Main Outcome Measures: Thyroid function, echographic pattern, nodule diameter, the presence of lymph-

adenopathy, and cytologic and histologic diagnoses were considered.

Results: Thyroid nodules were found in 115 patients; findings in 11 of these were consistent with papillary carcinoma, with 5 exhibiting lymph node metastasis. The prevalence of male sex among patients with cancer was greater than that among patients with JAT (odds ratio [OR], 2.95; 95% confidence interval [CI], 1.44-6.20). The growth of nodules during levothyroxine sodium therapy (OR, 15.60; 95% CI, 1.87-181.90) and the finding of lymphadenopathy (OR, 5.44; 95% CI, 1.05-30.50) were statistically significantly associated with the presence of cancer, while uninodularity and hypoechogenicity were not.

Conclusions: The observed prevalences of thyroid nodules and thyroid cancer in our JAT case series were 31.5% and 3.0%, respectively. Papillary carcinoma was the only histotype detected. The finding of lymphadenopathy, a lack of response to levothyroxine therapy, and nodule hypoechogenicity suggested malignancy. Fine-needle aspiration biopsy was reliable in selecting patients for referral to surgery.

Arch Pediatr Adolesc Med. 2008;162(6):526-531

JUVENILE AUTOIMMUNE THYROIDITIS (JAT) is a chronic disorder with an occurrence prevalence of 1.3% to 9.6%.¹⁻³ Although unusual in children and adolescents, thyroid nodules are more often malignant in children than in adults. The overall incidence of thyroid cancer among childhood thyroid nodules was estimated to be 26.4% in a recent review by Niedziela⁴; however, the prevalence of nodular JAT and thyroid cancer among pediatric patients with JAT is unclear. The literature contains few studies^{5,6} specifically about children with nodular JAT, owing to the lack of case series in the pediatric age group.

The prevalence of thyroid cancer among patients with JAT is a matter of controversy. After Dailey et al⁷ reported 35 cases of autoimmune thyroiditis among 288 patients with malignant thyroid disease, postulating that the disorder was a precancerous lesion, other investigators looked for an association between autoimmune thyroiditis and thyroid cancer. Subsequent studies^{8,9} reported a prevalence range of 1% to 30%. Differences in patient selection contributed to this variability that was associated with geographic and ethnic diversity in the prevalences of JAT and thyroid cancer. Based on the observation of a more favorable course of thyroid cancer in the presence of JAT and on the sup-

Author Affiliations are listed at the end of this article

Group Information: The SIEDP/ISPED members are listed at <http://www.siedp.it/gds/sezione/cat/24/page/comitato>.

position that lymphocytic infiltration may represent an immune reaction to control proliferation of cancerous cells, JAT has also been described as a protective factor,¹⁰ a hypothesis unsupported by more recent evidence.⁴ However, data on the occurrence of thyroid cancer in JAT refer almost exclusively to adults.

In this study, we retrospectively investigated the occurrence of thyroid nodular disease and thyroid cancer in a large case series of patients with JAT diagnosed in childhood. Furthermore, based on cytologic and histologic findings, we describe the clinical, laboratory, and diagnostic characteristics of patients having thyroid cancer compared with those of patients having autoimmune thyroiditis and benign lesions.

METHODS

We conducted a retrospective study among 365 children and adolescents (308 female and 57 male) diagnosed as having JAT at 3.6 to 17.0 years of age. The JAT diagnosis was based on positive findings of antithyroid antibodies and a dishomogeneous hypoechoic ultrasound pattern. None of the patients were affected by chromosomopathy or underwent radiation therapy for a neoplasm involving thyroid fields. All patients had been followed up for at least 1 year (mean [SD] follow-up period, 4.7 [3.9] years) except for 3 patients in whom cancer discovery and JAT diagnosis coincided. The study involved 6 Italian pediatric endocrinology centers that provided data on consecutive patients in whom a JAT diagnosis was made between January 1997 and April 2006. Patients were diagnosed as having JAT based on the following clinical findings: goiter (290 patients), signs or symptoms of hypothyroidism (48 patients) or thyrotoxicosis (11 patients), visible or palpable nodule (11 patients), and family history of thyroid diseases or autoimmune disease (5 patients).

At JAT diagnosis, 96 patients (26.3%) were prepubertal, and 269 patients (73.7%) were pubertal. When initially seen, 195 patients (53.4%) had euthyroidism, 159 patients (43.6%) had hypothyroidism, and 11 patients (3.0%) had thyrotoxicosis. Among the patients with euthyroidism, 192 had goiter, and 3 had a family history of thyroid diseases or autoimmune disease. Clinical examination and assessment of thyroid function were performed every 6 to 12 months. Thyroid echography was performed every 12 to 24 months and every 6 to 12 months in patients with a suspicious thyroid nodule.

We reported the finding of lymphadenopathy, the thyroid function at nodule discovery, the number of patients with nodular disease (specifying patient sex and age), the echographic pattern (echogenicity, nodule diameter, and uninodular or multinodular disease), and the numbers of patients who underwent fine-needle aspiration biopsy (FNAB) for cytologic study and subsequent surgery. In patients who received levothyroxine sodium treatment before cancer diagnosis, we investigated the change in nodule diameter. In patients with thyroid cancer, we considered the thyroid function at cancer detection; the histologic diagnosis of the surgical specimen; the timing of JAT, nodule, and cancer detection; the correlation between cytologic and histologic findings; and the cytologic diagnosis based on FNAB findings (except for 5 patients who directly underwent surgery because of symptoms of compression on adjacent organs or because of echographic features of a lymph node suspicious for malignancy).

We also compared the following characteristics in patients with thyroid cancer vs patients with a benign nodule (defined by cytologic or histologic findings): sex, age at nodule discov-

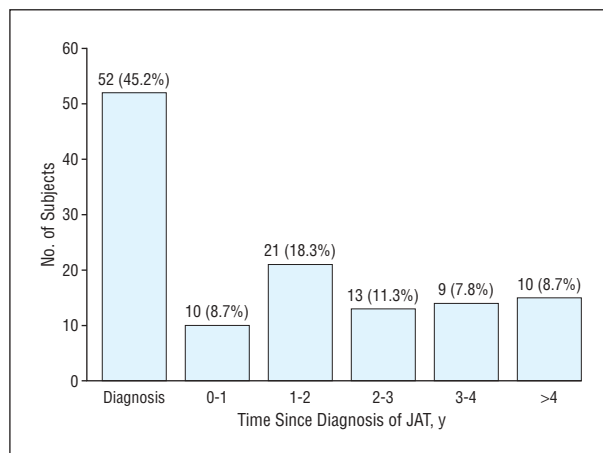


Figure 1. Timing of nodule discovery relative to diagnosis of juvenile autoimmune thyroiditis (JAT).

ery, nodule hypoechoogenicity, age at diagnosis of thyroiditis, changes in nodule diameter during levothyroxine therapy, prevalence of uninodular and multinodular disease, and prevalence of clinically detectable lymphadenopathy. The Fisher exact test and *t* test were used to compare these variables.

RESULTS

Thyroid nodules were found in 115 of 365 patients with JAT (31.5%), 69 (60.0%) of whom had a solitary nodule and 46 (40.0%) of whom had multiple nodules. Thirty-eight nodules were palpable at clinical examination, and the presence of all of them was confirmed by echography. At diagnosis, the patient age range was 8.5 to 18.0 years, and the size range of the single or dominant nodule was 0.3 to 3.0 cm. **Figure 1** shows the timing of nodule discovery relative to JAT diagnosis.

Of 52 patients in whom a nodule was present at JAT diagnosis, 26 (50.0%) had euthyroidism, 25 (48.1%) had hypothyroidism, and 1 (1.9%) had thyrotoxicosis. Of 63 patients in whom a nodule was detected 0.5 to 6.9 years following JAT diagnosis, 55 (87.3%) had euthyroidism, 20 (31.7%) had received levothyroxine therapy, and 8 (12.7%) had hypothyroidism.

Figure 2 shows the numbers of patients with thyroid nodules, the numbers of patients who underwent FNAB and surgery, and the numbers of patients with papillary carcinoma. Four patients with a nodule diameter of less than 1 cm underwent FNAB on the basis of clinical and echographic findings suggestive of cancer (rapid increase in nodule diameter or echographic features of a lymph node suspicious for malignancy), and 1 was found to have papillary carcinoma. Among 35 patients with a cytologic diagnosis of a benign lesion, 10 patients underwent surgery, 1 of whom was found to have papillary carcinoma. Among the 10 patients, 3 were referred for surgery because of clinical evidence of persistent lymphadenopathy with a hypoechoic nodule, 3 were referred because of cosmetic or discomfort concerns or the presence of compression symptoms (cough, dysphagia, or upper airway obstruction), and 4 were referred because of persistent growth of the nodule (despite irregular margins of the lesion, high intranodular Dop-

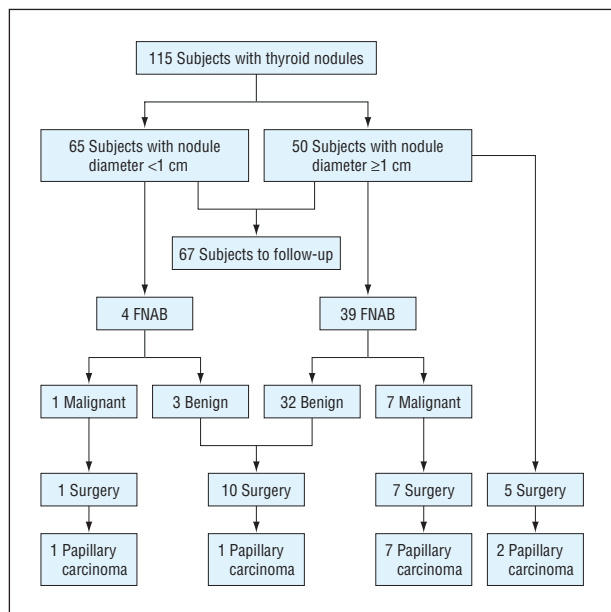


Figure 2. Numbers of patients with thyroid nodules, numbers of patients who underwent fine-needle aspiration biopsy (FNAB) and surgery, and numbers of patients with papillary carcinoma.

pler flow with a normal thyrotropin level, or levothyroxine therapy associated with echographic finding such as nodule hypoechoogenicity).

Eight patients with a malignant or suspicious lesion on cytologic examination underwent surgery, which revealed in all cases the presence of papillary carcinoma (1 case with a follicular variant). At surgery, 5 patients were also found to have metastasis to locoregional lymph nodes.

Eleven cases of papillary carcinoma were detected on histologic examination after total thyroidectomy. Eight patients had multifocal cancer, and 3 patients had single-focal cancer.

In 8 of 9 patients who underwent FNAB, the cytologic diagnosis revealed a malignant lesion; the cytologic diagnosis in the other patient was Hashimoto thyroiditis. In all patients, the histologic diagnosis was papillary carcinoma, with the diagnosis of a follicular variant of papillary carcinoma in 1 patient. Diagnostic accuracy of FNAB was 94.4%, sensitivity was 88.9%, and specificity was 100.0%.

The main clinical, laboratory, and diagnostic characteristics of 11 patients with thyroid cancer are listed in **Table 1** and **Table 2**. Seven were female, and 4 were male. The time between nodule discovery and JAT diagnosis ranged from 0.0 to 5.3 years, whereas the time between nodule discovery and the diagnosis of thyroid cancer ranged from 0.0 to 7.1 years. The nodule was clinically palpable in 4 patients. Locoregional lymphadenopathy was detected in 7 patients.

A solitary nodule was found in 4 patients, and 2 or more nodules were found in 7 patients. The nodules ranged in diameter from 0.9 and 3.0 cm. Eight patients had received levothyroxine sodium treatment for 1 to 6.5 years at dosages ranging from 0.5 to 2.6 $\mu\text{g}/\text{kg}/\text{d}$. The nodule diameter remained unchanged in 1 patient and increased in 7 patients (the nodule diameter increased by 50% over the baseline measurement in 2 patients). In the

other 3 patients, the diagnosis of the nodule coincided with the diagnosis of tumor; therefore, they went directly to surgery to undergo total thyroidectomy and no information could be given about nodule modification. The nodules were hypoechoogenic in 8 patients, isoechoogenic in 1 patient, and mixed isoechoechoogenic in 2 patients (Table 2).

At JAT diagnosis, 6 patients had hypothyroidism, 4 patients had euthyroidism, and 1 had thyrotoxicity. At nodule discovery, thyroid function was consistently found to be normal (6 patients had been receiving levothyroxine therapy). Lymph node washout, performed in 2 patients, resulted in an elevated thyroglobulin level exceeding 3000 ng/mL (to convert thyroglobulin level to micrograms per liter, multiply by 1.0).

Table 3 compares data among the 11 patients with thyroid cancer with that of those with a benign lesion at cytologic examination (25 patients) and at histologic examination (12 patients). Statistically significant differences were found between patients with a benign lesion vs those with cancer based on the clinical finding of lymphadenopathy (odds ratio [OR], 5.44; 95% confidence interval [CI], 1.05-30.50) and based on echographic evidence of the growth of nodules during levothyroxine therapy (OR, 15.60; 95% CI, 1.87-181.90).

Male sex was noted in 15.1% of the patients with JAT and 26.1% of the patients with thyroid nodules. A statistically significantly higher prevalence of male sex (36.7%) was observed among patients with cancer compared with that among patients with JAT (OR, 2.95; 95% CI, 1.44-6.20).

COMMENT

Among our pediatric patient series, we found a prevalence of thyroid nodular disease of 31.5%; however, this finding is difficult to compare with the rates reported in the literature because few studies^{4,11} published to date have evaluated the occurrence of thyroid nodules specifically in children, among whom case series of patients with JAT often comprise no more than 50 patients. However, in our series, the prevalence of nodular disease in JAT may be underestimated for 2 reasons. First, we considered 25 patients as having benign nodules on the basis of FNAB cytologic findings. Second, 67 patients with nodules did not undergo FNAB because of the well-known diagnostic criteria and flowsheet for adult populations.^{5,6,12,13} However, our study group consisted of patients with clinical signs or symptoms of JAT, excluding asymptomatic patients who would be evaluated by routine screening tests. In this setting, the prevalence of nodular disease in JAT that we reported may be overestimated. With these limitations, thyroid cancer was present in at least 3.0% of patients with JAT and in 9.6% of the subset with thyroid nodules. This is equal to or higher than reported in some studies^{3,8} and much lower than reported in other case series^{9,12,14} consisting primarily or only of adults. Because of the well-known high prevalence of benign nodules in JAT among healthy populations, the incidence of cancer among JAT nodules is unlikely comparable to the incidence of cancer among isolated nodules in childhood,

Table 1. Clinical Data Among 11 Patients With Thyroid Cancer

Patient No./Sex	Age at Diagnosis of Juvenile Autoimmune Thyroiditis, y	Age at Thyroid Nodule Discovery, y	Age at Diagnosis of Thyroid Tumor, y	Lymphadenopathy	Palpable Nodule
1/F	9.9	10.9	11.9	Yes	Yes
2/F	13.5	16.0	20.0	Yes	No
3/F	5.0	6.3	6.3	Yes	Yes
4/M	6.0	8.4	8.4	Yes	No
5/M	12.0	13.3	13.8	No	No
6/F	13.9	13.9	21.0	No	No
7/F	9.2	9.7	11.4	Yes	No
8/M	11.7	11.7	13.5	No	No
9/F	10.8	16.1	20.0	Yes	Yes
10/F	12.2	16.8	17.1	No	No
11/M	7.9	7.9	7.9	Yes	Yes

Table 2. Echographic Findings Among 11 Patients With Thyroid Cancer

Patient No.	No. of Thyroid Nodules	Thyroid Nodule Diameter at Discovery, cm	Levothyroxine Sodium Therapy	Thyroid Nodule Diameter at Tumor Diagnosis, cm ^a	Echographic Pattern
1	2	1.5	Yes	1.7	Hypoechogetic
2	1	0.9	Yes	1.4	Hypoechogetic
3	2	1.5	No	...	Mixed
4	1	1.2	No	...	Hypoechogetic
5	1	1.1	Yes	2.2	Mixed
6	2	1.1	Yes	1.7	Hypoechogetic
7	2	1.5	Yes	1.6	Hypoechogetic
8	2	1.0	Yes	1.4	Isoechogetic
9	2	1.6	Yes	2.0	Hypoechogetic
10	1	1.3	Yes	1.3	Hypoechogetic
11	2	3.0	No	...	Hypoechogetic

^aEllipses indicate patients who directly underwent surgery at nodule discovery.

estimated to be 26.4%.⁴ If we consider only nodules with diameters of 1 cm or larger (commonly considered palpable and viewed with a higher degree of suspicion), we can report an occurrence of thyroid cancer of 20.0%, an estimate that closely parallels that reported in non-JAT nodules.⁴ This consideration highlights the importance of a careful workup of thyroid nodules with diameters of 1 cm or larger, even when occurring in patients with JAT.

It is well known that a moderate degree of iodine deficiency may be responsible for an increased prevalence of thyroid nodules. Italy is a country with mild to moderate iodine deficiency,¹⁵ leading to a high incidence of goiter, with considerable differences among various areas.^{15,16} Because no control group was available to demonstrate the prevalence of thyroid nodules among children with normal iodine intake, our data may not be applicable to iodine-sufficient populations. Nevertheless, decreases in iodine deficiency and in goiter prevalence were recently reported,¹⁷ and an Italian study¹⁸ among a large cohort of patients living in an iodine-deficient area reported that thyroid nodules are exceptional among children younger than 14 years (prevalence, 0.5%) and are rare among patients aged 15 to 25 years (prevalence, 2.1%). Therefore, even if an assessment of iodine status in our study group had been performed, iodine deficiency may have had only a marginal effect on these results.

Table 3. Clinical and Echographic Findings Among Patients With Juvenile Autoimmune Thyroiditis (JAT) by Lesion Type

Variable	Benign Lesions (n=37)	Malignant Lesions (n=11)
Clinical findings		
Age at diagnosis of JAT, mean (SD), y	11.2 (2.4)	10.2 (2.9)
Age at thyroid nodule discovery, mean (SD), y	12.5 (2.5)	11.9 (3.6)
Lymphadenopathy, No. (%) ^a	9 (24.3)	7 (63.6)
Echographic findings		
Growth of nodule during levothyroxine sodium therapy ^a	5/26	6/8
Multinodularity/uninodularity	14/23	7/4
Hypoechogeticity	20	8

^aStatistically significantly associated with the presence of cancer.

In all 11 patients with a malignant neoplasm, the histologic diagnosis was papillary carcinoma, 1 of which was a follicular variant. This finding is in agreement with published data from studies^{4,19,20} that report this lesion as the type most frequently occurring in patients with thyroid

cancer in JAT, but it contrasts with other studies that report a lower frequency of papillary carcinoma compared with other types of histologically determined lesions.^{5-8,21-26} There are well-documented cases affected by follicular lesions and undifferentiated and squamous cell carcinomas.^{5-8,21,22} Unlike other studies,²³⁻²⁶ we found no cases of lymphoma in our series.

Among our patients, the diagnostic accuracy of FNAB in differentiating benign from malignant nodules in JAT was high and was in agreement with the rates reported by some investigators^{6,12,21} and was higher than rates reported by others.^{5,8,24} This suggests that in our series FNAB had a high predictive value that permitted patients to be appropriately selected for referral to surgery. However, surgery was performed in 10 patients with a cytologically benign lesion for symptoms of compression on adjacent organs, an increase in nodule diameter during levothyroxine therapy, or echographic features of a nodule or lymph node that were strongly suggestive of malignancy. In 9 patients, histologic examination confirmed the presence of a benign lesion; in the patient in whom cytologic examination revealed Hashimoto thyroiditis, a papillary carcinoma was detected. The discrepancy between cytologic and histologic findings has been discussed elsewhere.^{5,24}

A comparison of data among 11 patients with papillary carcinoma vs 37 patients with cytologically or histologically confirmed benign lesions was notable relative to the finding of lymphadenopathy and the increases noted in nodule diameter during levothyroxine therapy. The finding of lymphadenopathy confirms the importance of clinical examination given that thyroid cancer in children is characterized by locoregional lymphadenopathy in 35% to 83% of cases, which is much higher than in adults.^{11,27} Papillary carcinoma has a marked tendency to early lymph node metastasis; it is estimated that about half of the patients with papillary carcinoma have cervicofacial lymphadenopathy.⁵ Based on findings among children with nodular disease, including those unaffected by JAT, the presence of lymphadenopathy ranks second after FNAB in accurate detection of malignancy.²⁸

The therapeutic efficacy of reducing a thyroid nodule diameter in thyroiditis has rarely been studied, although some investigators claim that a lack of reduction in nodule diameter during levothyroxine therapy is prognostic of a malignant nature of the nodule.^{13,29,30} Evidence for this claim seems to be statistically confirmed by our study, which showed that levothyroxine therapy reduced nodule diameters in 0 of 8 treated patients affected by cancer but in 15 of 26 patients (57.7%) without cancer.

A comparison between 11 patients with papillary carcinoma and 37 patients with benign lesions showed that thyroid function, patient sex and age, the number of nodules, and a hypoechogenic ultrasound pattern were similar in the 2 groups. That the hypoechogenic ultrasound pattern was similar is linked to its low specificity (ie, the high prevalence of hypoechogenic nodules in benign lesions). However, 8 of 11 patients with a malignant neoplasm had a hypoechogenic lesion, which is known to be suspicious for cancer.^{6,31}

The presence of a solitary nodule is generally considered suspicious for malignancy. However, echography of-

ten reveals multinodularity vs uninodularity on clinical examination. The finding of multiple nodules on echography carries a greater risk of cancer compared with the finding of a solitary nodule.^{6,31} The discovery of multiple nodules also carries greater risk, in that 7 of 11 patients in our series with cancer had at least 2 nodules on echography, which was higher than reported by other investigators.⁵

Regarding the male-female ratio, more girls were affected in our series, as reported by other authors.^{27,32,33} However, more boys were affected among patients with thyroid cancer compared with the entire JAT case series.

Thyroid function was not found to be a risk factor for developing cancer. This contrasts with findings reported by other investigators,^{30,34} who claim that chronically elevated thyroid-stimulating hormone levels stimulate the growth of thyroid tissue, leading to the formation of nodules and thyroid cancer.

Another consideration is thyroglobulin level measurement in the washout fluid from FNAB of neck lymph nodes. This protocol, previously used for early detection of cervical metastases following thyroidectomy and radioiodine therapy, also detects lymph node metastasis before surgery.^{35,36} In 1 of 2 patients in our series who underwent this procedure, it proved particularly useful in that it permitted detection of a malignant lesion in a patient in whom the cytologic findings were benign.

CONCLUSIONS

To our knowledge, this is the first study to analyze the relationship between JAT, cancer, and thyroid nodules in a large case series of pediatric patients. Our results carry the limitation of a retrospective study design and may provide an imprecise estimate of the occurrence of thyroid nodules and cancer in patients affected by JAT. However, our data show that thyroid nodular disease is present in 31.5% of pediatric patients with JAT and that cancer occurs among these in at least 9.6% of cases, with papillary carcinoma being the most common histologic type.

The finding of lymphadenopathy and increases in nodule diameter during levothyroxine therapy are 2 factors that are statistically significantly more frequent in patients with thyroid cancer than in patients with a benign lesion. Thyroid echography provides further useful diagnostic information. Among patients with thyroid cancer, hypoechogenicity seems to predominate over other ultrasound patterns, although it is common also in benign nodules. Furthermore, multinodularity is more frequent than uninodularity in patients with cancer. Finally, the accuracy of FNAB supports its diagnostic usefulness in the management of patients with thyroid nodules and in the differentiation between benign and malignant lesions.

Accepted for Publication: December 7, 2007.

Author Affiliations: Division of Pediatric Endocrinology, Regina Margherita Children's Hospital, Torino (Drs Corrias, Mussa, Einaudi, and de Sanctis), Department of Pediatrics, University of Bologna, Bologna (Drs Cassio, Baronio, and Bal), Endocrine Unit, Depart-

ment of Pediatrics, University of Milano, Milano (Drs Weber and Vigone), Institute of Pediatrics, University of Messina, Messina (Drs Wasniewska and Messina), Department of Pediatrics, University of Genova, Genova (Dr Gastaldi); and Pediatric Unit, Department of Medical Sciences, University of Piemonte Orientale, Novara (Drs Rapa and Bona), Italy.

Correspondence: Andrea Corrias, MD, Division of Pediatric Endocrinology, Regina Margherita Children's Hospital, Piazza Polonia 94, 10126 Torino, Italy (corranda@libero.it).

Author Contributions: Dr Corrias had full access to all the data in the study and takes responsibility for the integrity of the data and the accuracy of the data analysis. **Study concept and design:** Corrias, Cassio, Weber, and de Sanctis. **Acquisition of data:** Corrias, Cassio, Weber, Mussa, Wasniewska, Rapa, Gastaldi, Einaudi, Baronio, Vigone, Messina, Bal, Bona, and de Sanctis. **Analysis and interpretation of data:** Corrias, Mussa, and Baronio. **Drafting of the manuscript:** Corrias, Cassio, Mussa, Rapa, Gastaldi, Einaudi, Bal, Bona, and de Sanctis. **Critical revision of the manuscript for important intellectual content:** Corrias, Cassio, Weber, Mussa, Wasniewska, Baronio, Vigone, Messina, Bona, and de Sanctis. **Statistical analysis:** Corrias, Cassio, and Mussa. **Administrative, technical, and material support:** Corrias, Cassio, Weber, Mussa, Wasniewska, Rapa, Gastaldi, Einaudi, Baronio, Vigone, Messina, Bal, Bona, and de Sanctis. **Study supervision:** Corrias, Cassio, Weber, Wasniewska, Bona, and de Sanctis.

Financial Disclosure: None reported.

REFERENCES

- Rallison ML, Dobyns BM, Keating FR, Rall JE, Tyler FH. Occurrence and natural history of chronic lymphocytic thyroiditis in childhood. *J Pediatr.* 1975;86(5):675-682.
- Kabelitz M, Liesenkötter KP, Stach B, et al. The prevalence of anti-thyroid peroxidase antibodies and autoimmune thyroiditis in children and adolescents in an iodine replete area. *Eur J Endocrinol.* 2003;148(3):301-307.
- Zois C, Stavrou I, Kalogera C, et al. High prevalence of autoimmune thyroiditis in schoolchildren after elimination of iodine deficiency in northwestern Greece. *Thyroid.* 2003;13(5):485-489.
- Niedziela M. Pathogenesis, diagnosis and management of thyroid nodules in children. *Endocr Relat Cancer.* 2006;13(2):427-453.
- Nguyen GK, Ginsberg J, Crockford PM, Villanueva RR. Hashimoto's thyroiditis: cytodiagnostic accuracy and pitfalls. *Diagn Cytopathol.* 1997;16(6):531-536.
- Takashima S, Matsuzuka F, Nagareda T, Tomiyama N, Kozuka T. Thyroid nodules associated with Hashimoto thyroiditis: assessment with US. *Radiology.* 1992;185(1):125-130.
- Dailey ME, Lindsay S, Skahan R. Relation of thyroid neoplasms to Hashimoto disease of the thyroid gland. *AMA Arch Surg.* 1955;70(2):291-297.
- Carson HJ, Castelli MJ, Gattuso P. Incidence of neoplasia in Hashimoto's thyroiditis: a fine-needle aspiration study. *Diagn Cytopathol.* 1996;14(1):38-42.
- Ott RA, Calandra DB, McCall A, Shah KH, Lawrence AM, Paloyan E. The incidence of thyroid carcinoma in patients with Hashimoto's thyroiditis and solitary cold nodules. *Surgery.* 1985;98(6):1202-1206.
- Loh KC, Greenspan FS, Dong F, Miller TR, Yeo PP. Influence of lymphocytic thyroiditis on the prognostic outcome of patients with papillary thyroid carcinoma. *J Clin Endocrinol Metab.* 1999;84(2):458-463.
- Chaukar DA, Rangarajan V, Nair N, et al. Pediatric thyroid cancer. *J Surg Oncol.* 2005;92(2):130-133.
- Sclafani AP, Valdes M, Cho H. Hashimoto's thyroiditis and carcinoma of the thyroid: optimal management. *Laryngoscope.* 1993;103(8):845-849.
- Pisanu A, Piu S, Cois A, Uccheddu A. Coexisting Hashimoto's thyroiditis with differentiated thyroid cancer and benign thyroid diseases: indications for thyroidectomy. *Chir Ital.* 2003;55(3):365-372.
- Neuhof N, Kaiser H, Kaserer K. Latent carcinoma of the thyroid in Austria: a systematic autopsy study. *Endocr Pathol.* 2001;12(1):23-31.
- World Health Organization Vitamin and Mineral Nutrition Information System (VMNIS): WHO Global Database on Iodine Deficiency: Italy. http://who.int/vmnis/iodine/data/database/countries/ita_idd.pdf. Accessed September 21, 2007.
- Delange F. Iodine deficiency in Europe and its consequences: an update. *Eur J Nucl Med Mol Imaging.* 2002;29(suppl 2):S404-S416.
- Vella V. Goitre decline in Italy and contribution of the silent and active prophylaxis. *Br J Nutr.* 2005;94(5):818-824.
- Aghini-Lombardi F, Antonangeli L, Martino E, et al. The spectrum of thyroid disorders in an iodine-deficient community: the Pescopagano survey. *J Clin Endocrinol Metab.* 1999;84(2):561-566.
- Harach HR, Williams ED. Thyroid cancer and thyroiditis in the goitrous region of Salta, Argentina, before and after iodine prophylaxis. *Clin Endocrinol (Oxf).* 1995;43(6):701-706.
- Di Pasquale M, Rothstein JL, Palazzo JP. Pathologic features of Hashimoto's-associated papillary thyroid carcinomas. *Hum Pathol.* 2001;32(1):24-30.
- Franklyn JA, Fitzgerald MG, Oates GD, Sheppard MC. Fine needle aspiration cytology in the management of euthyroid goitre. *Q J Med.* 1987;65(248):997-1003.
- Kollur SM, El Sayed S, El Hag IA, I. Follicular thyroid lesions coexisting with Hashimoto's thyroiditis: incidence and possible sources of diagnostic errors. *Diagn Cytopathol.* 2003;28(1):35-38.
- Williams ED. Malignant lymphoma of the thyroid. *Clin Endocrinol Metab.* 1981;10(2):379-389.
- McKee RF, Krukowski ZH, Matheson NA. Thyroid neoplasia coexistent with chronic lymphocytic thyroiditis. *Br J Surg.* 1993;80(10):1303-1304.
- Nys P, Merceron RE, Cordray JP, et al. Nodular or pseudo-nodular Hashimoto thyroiditis: value of cytologic examination [in French]. *Presse Med.* 1995;24(14):675-678.
- Holm LE, Blomgren H, Löwhagen T. Cancer risks in patients with chronic lymphocytic thyroiditis. *N Engl J Med.* 1985;312(10):601-604.
- Haveman JW, van Tol KM, Rouwe CW, Piers DA, Plukker JT. Surgical experience in children with differentiated thyroid carcinoma. *Ann Surg Oncol.* 2003;10(1):15-20.
- Corrias A, Einaudi S, Chiorboli E, et al. Accuracy of fine needle aspiration biopsy of thyroid nodules in detecting malignancy in childhood: comparison with conventional clinical, laboratory, and imaging approaches. *J Clin Endocrinol Metab.* 2001;86(10):4644-4648.
- Carli AF, Lottini M, Testa M, Neri A. Surgical treatment of Hashimoto's thyroiditis: personal experience [in Italian]. *Minerva Chir.* 2002;57(2):117-122.
- Reda G, Cesareo R, Lolli E, Gargiulo A. Thyroid cancer and Hashimoto's thyroiditis [in Italian]. *Minerva Chir.* 1997;52(1-2):139-141.
- Jun P, Chow LC, Jeffrey RB. The sonographic features of papillary thyroid carcinomas: pictorial essay. *Ultrasound Q.* 2005;21(1):39-45.
- Shapiro NL, Bhattacharyya N. Population-based outcomes for pediatric thyroid carcinoma. *Laryngoscope.* 2005;115(2):337-340.
- Kowalski LP, Gonçalves Filho J, Pinto CA, Carvalho AL, de Carmargo B. Long-term survival rates in young patients with thyroid carcinoma. *Arch Otolaryngol Head Neck Surg.* 2003;129(7):746-749.
- Bettendorf M. Thyroid disorders in children from birth to adolescence. *Eur J Nucl Med Mol Imaging.* 2002;29(suppl 2):S439-S446.
- Boi F, Baghino G, Atzeni F, Lai ML, Faa G, Mariotti S. The diagnostic value for differentiated thyroid carcinoma metastases of thyroglobulin (Tg) measurement in washout fluid from fine-needle aspiration biopsy of neck lymph nodes is maintained in the presence of circulating anti-Tg antibodies. *J Clin Endocrinol Metab.* 2006;91(4):1364-1369.
- Frasoldati A, Toschi E, Zini M, et al. Role of thyroglobulin measurement in fine-needle aspiration biopsies of cervical lymph nodes in patients with differentiated thyroid cancer. *Thyroid.* 1999;9(2):105-111.