

Picture of the Month

Apurva K. Patel, MD; Melissa Murphy; Carol L. Shields, MD

A 31-MONTH-OLD HISPANIC BOY PRESENTED for evaluation of possible retinoblastoma in the right eye. At 22 months of age, strabismus had developed. There was no history of trauma. Three months later, examination showed total retinal detachment with the retina visible immediately posterior to the lens (**Figure, A and B**). Visual acuity was reduced to light perception in the right eye. With the left eye, he could fix and follow an object normally. The anterior segment of the right eye was unremarkable except for xanthocoria (yellow pupil) from an exudative retinal detachment. Examination

of the left eye was unremarkable. He was treated with anterior chamber injections of bevacizumab on a monthly basis for 5 months to resolve the retinal detachment.

Following the injections, visual acuity was unchanged. Intraocular pressures were normal in each eye (13 mm Hg). No conjunctival hyperemia or corneal opacity was seen. The anterior segment of the right eye was filled with refractile yellow crystals (**Figure, C and D**). There was no view of the fundus but B-scan ultrasonography revealed total retinal detachment with a retinal macrocyst. There was no intraocular tumor or calcification.

Author Affiliations: Ocular Oncology Service, Wills Eye Institute (Drs Patel and Shields and Ms Murphy), and Department of Ophthalmology, University of Pennsylvania School of Medicine (Dr Patel), Philadelphia.

See <http://www.archpediatrics.org> for the Picture of the Month Web Quiz: What is your diagnosis?

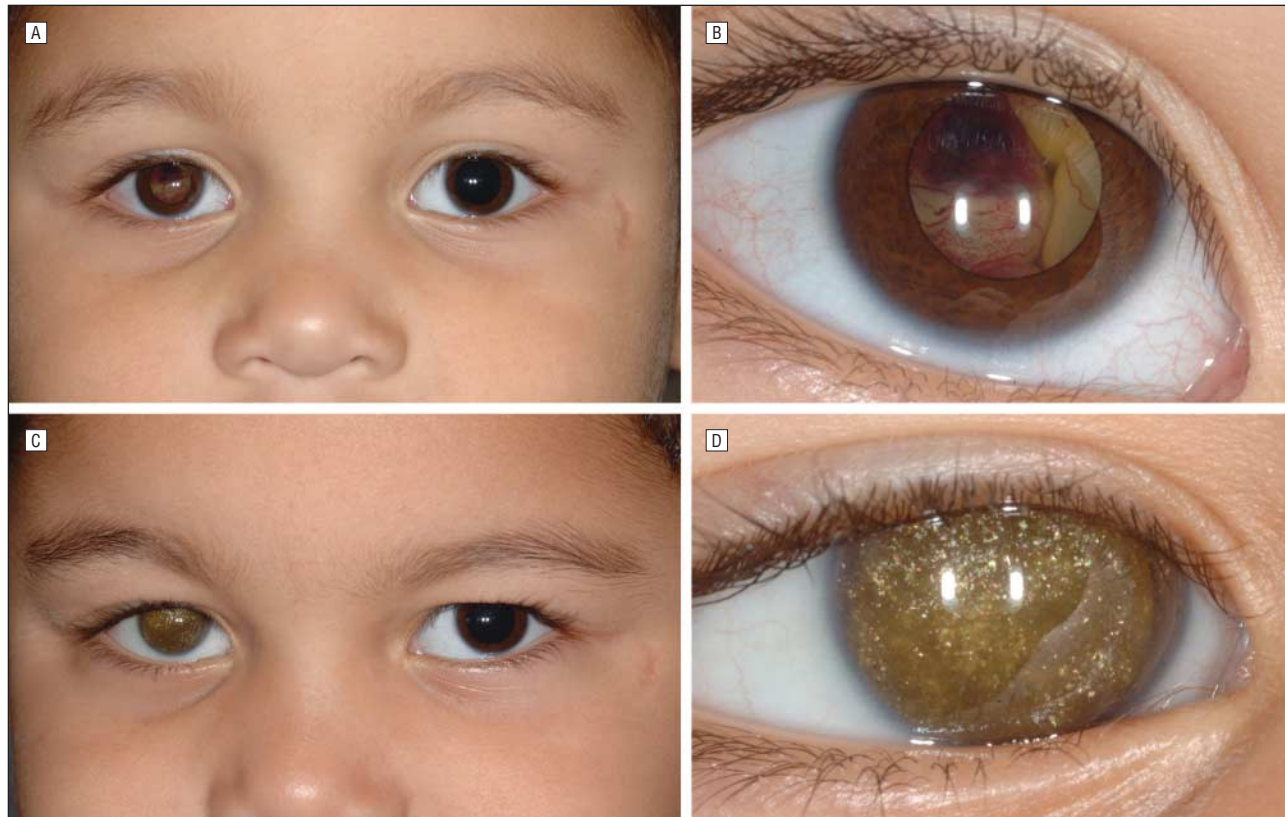


Figure. A, External view of the patient at initial presentation. B, Close-up view of the right eye showing the detached retina visible immediately posterior to the lens through a dilated pupil. The inferior retina shows telangiectatic retinal vessels characteristic of this condition. The detached retina appears yellow because of the presence of lipid exudate below the retina. C, External view of the patient 6 months later. D, Close-up view of the right eye at the 6-month follow-up showing numerous refractile cholesterol crystals in the anterior chamber.