

# Denouement and Comment

## Recurrent Biliary Colic in a Young Girl

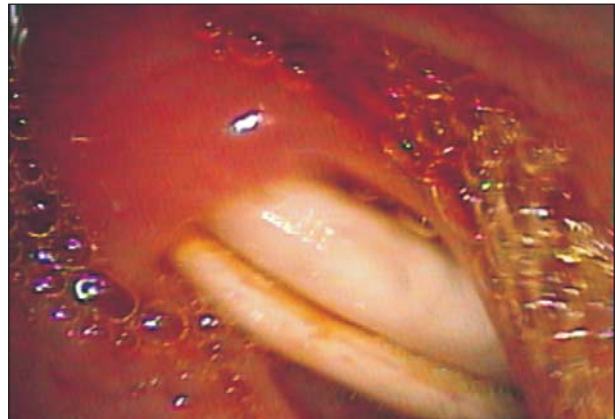
**E**ndoscopic US revealed multiple rounded echogenic structures with a hypoechoic center in a dilated CBD (about 14 mm), consistent with biliary ascariasis. Side-view endoscopy showed 2 live roundworms projecting from the ampullary orifice (**Figure 2**). Endoscopic retrograde cholangiopancreatography revealed multiple roundworms, which were extracted using a rat-tooth forceps (**Figure 3**). Worms inside the CBD and left hepatic duct were removed by a balloon, resulting in complete symptom relief. She received 1 dose of albendazole.

Ascariasis is the most common helminthic infection worldwide. While most cases occur in Asia and a modest number in Africa and the Middle East, some cases also occur along the Gulf Coast of the United States and in areas in Central and South America. It is acquired by consumption of food or water contaminated with eggs of *Ascaris lumbricoides*, a roundworm. The eggs hatch on reaching the small intestine and the resultant larvae penetrate the intestinal wall, migrating to the liver and lungs. The larvae pass up the trachea and are swallowed to reach the small intestine where they mature into adult worms.

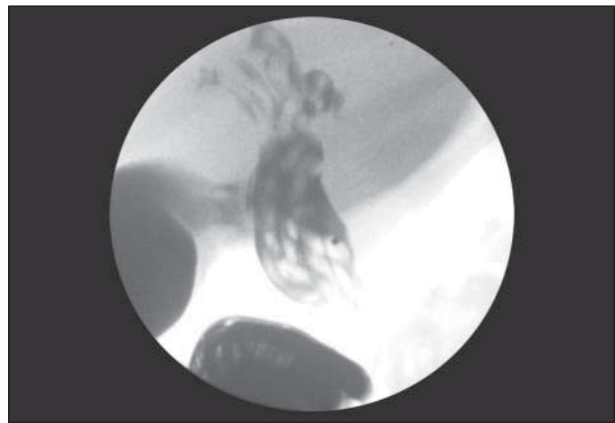
Persons with light infestation are typically without symptoms and only become aware of the parasites by passage or regurgitation of adult worms. Heavy infestations cause serious complications, including intestinal obstruction. Other complications include volvulus, perforation, appendicitis, intussusception, and hepatobiliary or pancreatic ascariasis.<sup>1-3</sup> Children with hepatobiliary ascariasis often present with biliary colic, nausea, and vomiting; the vomiting is bilious and usually contains worms. Cholangitis or cholecystitis complicate the course of up to one-third of children with hepatobiliary ascariasis.<sup>4</sup>

Stool examination will reveal adult worms or eggs in infected persons. Peripheral eosinophilia is only present during the tissue migration phase of infection. Serum conjugated bilirubin level is only mildly elevated because bile flows into the spaces between the cylindrical worms. However, most children with hepatobiliary or pancreatic ascariasis have elevated alkaline phosphatase levels.<sup>4</sup> US is an effective noninvasive imaging modality, although the sensitivity is low. Endoscopic US may be more sensitive in the evaluation of the cause for dilated CBD. The US appearances of CBD include a single, long, linear, or curved echogenic nonshadowing structure without an inner tube (stripe sign); a thick, long, linear, or curved nonshadowing echogenic stripe containing a central anechoic tube (inner-tube sign); and multiple long, linear, overlapping echogenic structures due to coiling of worms (spaghetti sign).

Most patients with uncomplicated biliary ascariasis respond to conservative management, with the worms spontaneously returning to the intestine. Anthelmintics are deferred during the acute stage for fear of causing flaccid paralysis and death of the worms in the bile duct. Commonly used drugs include mebendazole, pyrantel pamoate, and albendazole. The duration of therapy may be as long as 2 months in endemic regions to prevent recurrence.<sup>4</sup> Indications for aggressive invasive therapy are failure of con-



**Figure 2.** Side-view endoscopy showing ascaris protruding from the ampullary orifice.



**Figure 3.** Cholangiopancreatogram showing multiple ascaris worms in the common bile duct.

servative treatment; persistent alive or dead worms in the biliary tree; and coexisting biliary stones or strictures.

**Accepted for Publication:** February 23, 2011.

**Correspondence:** Malay Sharma, MD, DM, Jaswant Rai Specialty Hospital, Saket, Meerut, India (sharmamalay@hotmail.com).

**Author Contributions:** Dr Sharma did the endoscopic US. *Acquisition of data:* Sharma and Mohan. *Drafting of the manuscript:* Sharma and Mohan.

**Financial Disclosure:** None reported.

**Online-Only Material:** The video is available at <http://www.archpediatrics.com>.

## REFERENCES

1. Gangopadhyay AN, Upadhyaya VD, Gupta DK, Sharma SP, Kumar V. Conservative treatment for round worm intestinal obstruction. *Indian J Pediatr.* 2007;74(12):1085-1087.
2. Pinus J. Surgical complications of ascariasis. *Prog Pediatr Surg.* 1982;15:79-86.
3. Ochoa B. Surgical complications of ascariasis. *World J Surg.* 1991;15(2):222-227.
4. Malik AH, Saima BD, Wani MY. Management of hepatobiliary and pancreatic ascariasis in children of an endemic area. *Pediatr Surg Int.* 2006;22(2):164-168.