

Retinal Hemorrhages in Low-Risk Children Evaluated for Physical Abuse

Simiao Li, BA; Ellen Mitchell, MD; Janet Fromkin, MD; Rachel P. Berger, MD, MPH

Objectives: To describe the prevalence of retinal hemorrhage (RH) in children without intracranial injury who are being evaluated for abusive head trauma and to validate previously derived criteria for identifying patients within this population who are at low risk of having RH on dilated eye examination.

Design: Medical record review.

Setting: Children's Hospital of Pittsburgh of University of Pittsburgh Medical Center from January 1, 2006, to April 30, 2010.

Participants: One hundred ninety-four infants and children evaluated for physical abuse by the hospital Child Protection Team who did not have intracranial injury and who underwent a dilated eye examination to evaluate for RH.

Main Outcome Measure: Number of children with RH who met a set of low-risk criteria: no intracranial hem-

orrhage with or without a simple, nonoccipital skull fracture, normal mental status, and no bruising on the head or face.

Results: Of the 194 patients without intracranial injury who underwent dilated eye examination, 141 children (72.7%) met low-risk criteria. None of these 141 patients had RH. Of the 53 participants who did not meet low-risk criteria, 2 children (3.8%) had RH.

Conclusions: In children evaluated for physical abuse who fulfill a set of low-risk criteria, the dilated eye examination should not be a necessary component of the abuse evaluation. Use of these criteria can significantly decrease the number of children who need to undergo a dilated eye examination as part of an evaluation for abusive head trauma.

Arch Pediatr Adolesc Med. 2011;165(10):913-917

ABUSIVE HEAD TRAUMA (AHT) is the leading cause of death from child abuse.^{1,2} Proper and timely diagnosis of AHT is critical because, if left undiagnosed, repeated incidents can occur and lead to significant morbidity and mortality.³ The diagnosis of AHT can be difficult to make because children with AHT often present without a history of trauma, with nonspecific symptoms such as vomiting and fussiness, and without external signs of injury. Furthermore, caregivers rarely provide an accurate history.³ Finally, infants and young children can have normal mental statuses even in the presence of intracranial injury (ICI).⁴

Because it is so difficult to diagnose AHT, infants and young children who are being evaluated for possible physical abuse often undergo an evaluation for AHT even in the absence of signs or symptoms of brain injury.^{5,6} For example, premobile infants with a bruise or fracture are often evaluated for AHT, even in the absence of any symp-

toms of brain injury. The high rate of occult ICI in this population⁵⁻⁷ supports the need for liberal neuroimaging in this age group when there is concern for abuse. An evaluation for AHT includes neuroimaging (computed tomography [CT] or magnetic resonance imaging [MRI]) and a dilated eye examination. The role of the dilated eye examination is to evaluate for retinal hemorrhage (RH). While the absence of RH does not rule out abuse, RH outside the posterior pole and/or in multiple layers of the retina is considered one of the most specific indicators of AHT.⁸

The American Academy of Pediatrics recommends that an ophthalmologist with pediatric experience perform the dilated eye examination.⁹ The need to have an ophthalmologist with pediatric experience perform this examination can be logistically challenging and may extend the length of hospitalization, thereby increasing cost, expending resources, and increasing the possibility of nosocomial infection, a particularly important issue in infants.^{10,11}

Author Affiliations: Clinical Scientist Training Program, University of Pittsburgh School of Medicine (Ms Li), Division of Pediatric Ophthalmology, Department of Ophthalmology, University of Pittsburgh Medical Center (UPMC) Eye Center (Dr Mitchell), and Child Advocacy Center, Department of Pediatrics, Children's Hospital of Pittsburgh of UPMC (Drs Fromkin and Berger), Pittsburgh Pennsylvania.




Figure 1. Division of children into populations at low risk of and populations not at low risk of having retinal hemorrhage.

Although performance of the dilated eye examination has been considered a standard part of the evaluation for AHT, a recent study by Thackeray and colleagues¹² suggested that the examination may not be necessary in all children. In their study of 282 children younger than 2 years who were evaluated for AHT and had no ICI, 2 children (0.7%; 95% confidence interval [CI], 0.1%-2.5%) had RH, which the authors considered to be “characteristic” of abuse. Both children had “head or facial injury on physical examination and/or altered mental status.” On the basis of their data, the authors derived a set of criteria for children in whom a dilated eye examination may not be necessary: children with no ICI, normal mental status, and no bruising on the head or face.

The study by Thackeray and colleagues¹² had several limitations. Most important, because their investigation was ancillary to a larger multicenter study,¹³ the authors were unable to determine the effect of their recommendations on clinical practice. As part of the parent study, data were available on 1676 children who underwent evaluation for suspected physical abuse. Of those children, 282 had no ICI; 9 of the 282 had RH, 2 of whom had RH considered “characteristic” of AHT. The authors obtained patient-specific data, including physical examination findings and mental status, for those 9 individuals. However, they did not collect the same data on the 273 children without RH. As a result, it is not possible to determine how many of the 273 children met low-risk criteria (eg, if the majority of these children had an abnormal mental status or injury to the head or face, the authors’ recommendations would have little effect on the number of dilated eye examinations performed). The fact that the study derived the clinical criteria retrospectively is also a limitation because prospective validation is an important step before integrating a novel clinical decision rule into clinical practice.¹⁴ Finally, the study by Thackeray and colleagues¹² did not provide information about the type of neuroimaging (CT vs MRI) performed.

The objectives of the present study were therefore to describe the prevalence of RH in a novel population of children without ICI who underwent a dilated eye examination to evaluate for RH and prospectively validate previously derived criteria for identifying patients within this population who are at low risk of having RH identified on dilated eye examination.

We performed a review of the medical records of all children who underwent neuroimaging (CT or MRI) and a dilated eye examination and were evaluated by the Child Protection Team at Children’s Hospital of University of Pittsburgh Medical Center between January 1, 2006, and April 30, 2010. Children were identified as potentially eligible for enrollment if they were evaluated by the hospital’s Child Protection Team for concerns of physical abuse. All children evaluated by the hospital’s Child Protection Team are included in a database that is used for billing, legal, and research purposes. The electronic medical record was used to collect all data, with the exception of ophthalmology consultations during the first 2 years of the study. Paper records were needed for this information. To ensure the reliability of data collection, the senior author (R.P.B.) reviewed the first 25 data extractions and approximately 10% of all subsequent data collection forms.

Children were eligible for enrollment if results of the initial neuroimaging (head CT or brain MRI) were normal or demonstrated a skull fracture. Within this population, children were classified as low risk if they met a set of previously derived criteria: normal mental status, no bruising on the head or face, and no skull fracture or a simple, nonoccipital fracture. Children with definite or possible/equivocal ICI of any type on initial neuroimaging were excluded.

Demographic and clinical data were collected for each child. Demographic data included age and sex; information on race was not consistently available and so was not collected. Clinical data included the reason for presentation, mental status, type and location of dermatologic injuries, and results of neuroimaging, dilated eye examination, and skeletal survey. Mental status was classified as normal or abnormal on the basis of documentation by the emergency department physician who initially examined the child. Dermatologic injuries were classified as bruising or injuries other than bruising. Injuries other than bruising included abrasion/laceration, erythema, and petechiae. The location of injury was classified as head or face, trunk, or extremities. The presence or absence of subconjunctival hemorrhages was also documented. Neuroimaging results were classified as normal or skull fracture. Skull fractures were classified by type and location; type included simple linear or other, and location was classified as occipital or nonoccipital. Dilated eye examination results were documented as normal (defined as having no RH) or abnormal (defined as having any RH).

All dilated eye examinations were performed by a resident, fellow, or attending physician in pediatric ophthalmology, which conforms to the recommendation of the American Academy of Pediatrics. Standard practice at our institution is to perform the dilated eye examination as soon as possible after neuroimaging has been completed; this almost always occurs within 24 hours and often within several hours of the imaging. The retina is routinely photographed in cases in which there is RH (Ret-Cam; Clarity Medical Systems, Inc, Pleasanton, California). Commercial statistical software (SPSS 17.0; SPSS, Inc, Chicago, Illinois) was used for descriptive analysis, and the prevalence of RH was calculated with a 95% CI. The study was approved by the University of Pittsburgh institutional review board, with a waiver of informed consent.

RESULTS

One hundred ninety-four children met enrollment criteria; 141 of these (72.7%) met low-risk criteria (**Figure 1**). The median age of all children was 5 months (range, 0-58 months); 73.2% of the children (n=142) were younger than 12 months, and 11.3% of the population

Table. Case Descriptions of 2 Children With Retinal Hemorrhages

Sex/ Age, mo	Reason for Presentation	Neurologic Status in ED	Dermatologic Findings	CT Result	RH Description
F/17	History of trauma (reportedly fell from chair and hit head on kitchen counter)	Normal	Abnormal: bruises on head, abdomen, extremities, chest	Normal	Bilateral, preretinal, intraretinal, and subretinal hemorrhages in posterior pole; 8-10 hemorrhages in each eye
M/37	Request by CPS to evaluate for abuse (sibling of abused child)	Abnormal (fussy, inconsolable)	Abnormal: bruises and abrasions on head, abdomen, back, extremities, shoulder	Extensive nondisplaced fracture extending from foramen magnum to frontoparietal skull through occipital bone	Bilateral, intraretinal hemorrhages in posterior pole; 2 hemorrhages in each eye

Abbreviations: CPS, Child Protective Services; CT, computed tomography; ED, emergency department; RH, retinal hemorrhage.

(n=22) were 24 months or older. In addition, 55.7% of the children (n=108) were male. There were no significant demographic differences between children who met low-risk criteria and those who did not.

Of the 53 children who did not meet low-risk criteria, 6 children (11.3%) had an abnormal mental status, 29 (54.7%) had bruising on the head or face, and 20 (37.7%) had skull fractures that were not simple linear fractures, or fractures that involved the occipital bone. Two children had more than 1 reason for not meeting low-risk criteria.

Of 194 participants, 95.4% of the children (n=185) underwent CT as the initial neuroimaging, 9.3% (n=18) underwent CT and MRI, and 4.6% (n=9) underwent only MRI. All 18 participants who underwent MRI had normal mental status, and 11 would have been considered low risk. In the 18 children who underwent MRI and head CT, there were 4 cases in which there was a discrepancy between the results of the 2 imaging techniques. In 3 cases, the MRI did not show the skull fracture that was visible on head CT. In 1 case, the MRI demonstrated chronic subdural hemorrhages that were interpreted as being benign extra-axial fluid of infancy on the head CT. This child did not have RH.

None of the 141 children at low risk had RH (95% CI, 0%-2.1%).¹⁵ Therefore, if dilated eye examinations had not been performed in children who met low-risk criteria, 72.7% of these children (141 of 194) would not have needed an eye examination.

Two of the 53 high-risk children (3.8%; 95% CI, 1.2%-6.4%) had RH. These children are described in the **Table**. In addition to the 2 children with RH, 11 had subconjunctival hemorrhages. Of the 11 participants with subconjunctival hemorrhages, 7 would not have met low-risk criteria because of bruising on the face. Four children with subconjunctival hemorrhages did not have any sign of blunt force trauma to the face, suggesting that the source of the hemorrhages may have been increased intrathoracic pressure.^{16,17} None of the 11 children with subconjunctival hemorrhages had RH.

COMMENT

This study demonstrates a prospective validation of a set of low-risk criteria for identifying children who may not need to undergo a dilated eye examination as part of their

evaluation for AHT. This validation was performed using criteria that were derived in an entirely different population. In our population, none of 141 children who met low-risk criteria had RH. Based on our study and that of Thackeray and colleagues,¹² we recommend a clinical decision pathway/paradigm for assessing whether a given patient should undergo a dilated eye examination (**Figure 2**).

We recognize that it is difficult for physicians to be comfortable eliminating certain evaluations because of concern that pathology could be missed. However, no study can prove that an event did not occur. The decision about whether a test needs to be performed is a subjective assessment of the usefulness of the test in a given scenario. It is particularly difficult to know the true frequency of rare events. In the present 4¹/₂-year study, no child who met low-risk criteria had RH. Based on the rule of Hanley and Lippman-Hand,¹⁵ the true rate of RH in the low-risk population in this study may be as high as 2.1%. Given that the studies by Thackeray et al¹² and Morad et al¹⁸ also demonstrated that no child who met low-risk criteria had RH, the true rate is likely lower. Decreasing the upper limit of the CI can be problematic; if one were to enroll 300 children who were considered low-risk in the study (a study that would require approximately 9 years at a large, level I trauma center) and there were no cases of RH, the CI would decrease, but only to 1%. It is not clear whether a physician who is uncomfortable changing clinical practice based on no RH in a population of 141 would be more comfortable based on no RH in a population of 300. Perhaps more important, if there were 1 child during this 9-year period who met low-risk criteria and had RH, the question is whether this finding would balance the cost and resources associated with 299 examinations with normal results. These important issues will likely be brought to the forefront during the next several years as the burden falls on proving the usefulness of evaluations that may not have a clear evidence base.

The importance of mental status in assessing for possible AHT in children without ICI was described in a case series by Morad and colleagues¹⁸ in which a worldwide listserv was used to identify children who received a diagnosis of AHT but had normal results of an initial CT scan. Of the 9 children in the case series, 8 had RH. All

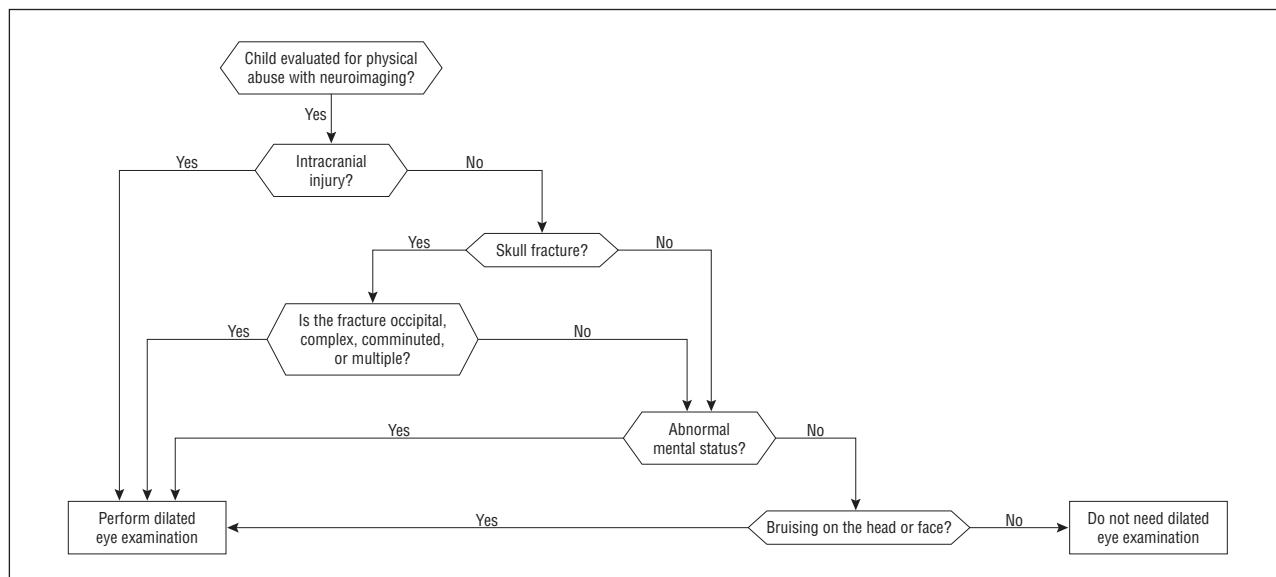


Figure 2. Suggested paradigm for determining whether a child meets low-risk criteria.

children included in that case series had an abnormal mental status and/or facial bruising. As a result, none of those patients would have been considered low risk and all would have undergone dilated eye examination.

It is unlikely that the RH in the 2 children with RH in the present study would be considered characteristic of AHT because they were localized to the posterior pole. In both cases, the diagnosis of physical abuse was made independent of the RH. However, we do not believe that this should be interpreted to mean that the dilated eye examinations were not useful and should not have been performed. The presence of RH, even that isolated to the posterior pole, can provide information about the severity of injury,¹⁹ allowing for better assessment of whether the history provided by the caretakers is consistent with clinical data. Posterior pole RH may also be seen in cases of AHT in which the RH is resolving. As a result, identification of even a few posterior pole RHs may prompt physicians to perform a brain MRI to further evaluate for evidence of chronic brain injury.

Eleven percent of the children in our study, including one of the two with RH, were older than 2 years and would not have been included in the study by Thackeray and colleagues.¹² It is important to recognize that AHT can occur in older children²⁰ and that the possibility of RH should be considered in these children. Our data suggest that the low-risk criteria identified by Thackeray and colleagues may also be relevant in older children. Studies will be necessary to confirm the applicability of these low-risk criteria to the population of children older than 2 years.

Twenty patients (10.3%) had either complex (multiple, diastatic, or comminuted) or occipital fractures. Our data suggest that the rate of RH in children with complex and/or occipital fractures is low; however, the force required to produce these injuries may be higher than that required for simple linear skull fractures. The association of occipital skull fractures and child abuse has been reported previously.^{21,22} In our study and the study by Thackeray and colleagues, one of the children with

RH had an occipital fracture. As a result, we recommend continuing to perform dilated eye examinations in children with complex fractures and occipital fractures until additional information is available that could determine which children with these types of fractures can be considered low risk. The lack of RH in children with fractures is consistent with the findings of Thackeray and colleagues and suggests that repeated acceleration-deceleration (eg, shaking) rather than impact is important in the genesis of RH.

There are several limitations to this study. The first relates to selection bias. Only children who were evaluated by the hospital Child Protection Team were eligible for enrollment. There may have been other children who underwent neuroimaging and dilated eye examination but did not undergo a consultation by the Child Protection Team. Presumably, in these cases, the diagnosis of abuse was considered, but the concern for abuse was very low after all screening tests had been performed. If this were the case, the true prevalence of RH in our study population would be lower than the calculated rate.

The second limitation relates to the subjectivity of interpretation of the head CT scans and eye examinations. We do not believe that there was significant variability in head CT interpretation because all the interpretations were performed by board-certified neuroradiologists at Children's Hospital of Pittsburgh who have significant experience interpreting pediatric head CT scans. As part of a related study, we demonstrated a 100% (51 of 51) agreement in the interpretation of head CT scan results between 2 attending neuroradiologists when the initial interpretation of the head CT was normal (R.P.B., unpublished data, January 2011). We also believe it is unlikely that RH was missed on the dilated eye examinations. All dilated eye examinations were performed by residents, fellows, or attending pediatric ophthalmologists, all of whom have significant training in pediatric ophthalmology.

In conclusion, the results of this study validate the clinical criteria derived by Thackeray and colleagues¹² for identifying children who may not require a dilated eye examination as part of the evaluation for AHT. These children have normal results of head CT or a head CT scan demonstrating a simple linear skull fracture not involving the occipital bone, normal mental status, and no bruising on the head or face. The next step in the process of implementing these clinical criteria is to assess the impact of their use on clinical behavior by using well-accepted, evidence-based recommendations.¹⁴

Accepted for Publication: March 30, 2011.

Correspondence: Rachel P. Berger, MD, MPH, Department of Pediatrics, Child Advocacy Center, Children's Hospital of Pittsburgh of University of Pittsburgh Medical Center, 4401 Penn Ave, Pittsburgh, PA 15224 (rachel.berger@chp.edu).

Author Contributions: Dr Berger had full access to all the data in the study and takes responsibility for the integrity of the data and the accuracy of the data analysis. **Study concept and design:** Li and Berger. **Acquisition of data:** Li, Mitchell, and Berger. **Analysis and interpretation of data:** Li, Fromkin, and Berger. **Drafting of the manuscript:** Li and Berger. **Critical revision of the manuscript for important intellectual content:** Li, Mitchell, Fromkin, and Berger. **Statistical analysis:** Li and Berger. **Obtained funding:** Li and Berger. **Administrative, technical, and material support:** Berger. **Study supervision:** Fromkin and Berger.

Financial Disclosure: None reported.

Funding/Support: Support for statistical consultation was made possible by grant 5UL1 RR024153-05 from the National Center for Research Resources (NCRR), a component of the National Institutes of Health (NIH), and the NIH Roadmap for Medical Research. This study was supported by the Clinical Scientist Training Program Scholarship from the Dean's Office of the University of Pittsburgh School of Medicine and the Children's Hospital of Pittsburgh of University of Pittsburgh Medical Center Student Research Training Program.

Disclaimer: The contents of this article are solely the responsibility of the authors and do not necessarily represent the official view of the NCRR or the NIH.

Additional Contributions: Amber Barnato, MD, and Debra Bogen, MD, provided research guidance as part of the Clinical Scientist Training Program at the University of Pittsburgh School of Medicine. Janet Squires, MD, of the Children's Hospital of Pittsburgh of University of Pittsburgh Medical Center Division of Child Advocacy, provided intellectual input. Pamela Rubin, RN, Diane Weidner, BA, and Haley Stutz, BA, of the Children's Hospital of Pittsburgh of University of Pittsburgh Medical Center Division of Child Advocacy provided administrative

support. Douglas Landsittel, PhD, Clareann H. Bunker, PhD, and Li Wang, MS, provided statistical support as part of the Clinical & Translational Science Institute of the University of Pittsburgh.

REFERENCES

- King WK, Kiesel EL, Simon HK. Child abuse fatalities: are we missing opportunities for intervention? *Pediatr Emerg Care*. 2006;22(4):211-214.
- Jenny C, Hymel KP, Ritzen A, Reinert SE, Hay TC. Analysis of missed cases of abusive head trauma. *JAMA*. 1999;281(7):621-626.
- Keenan HT, Runyan DK, Marshall SW, Nocera MA, Merten DF, Sinal SH. A population-based study of inflicted traumatic brain injury in young children. *JAMA*. 2003;290(5):621-626.
- Greenes DS, Schutzman SA. Occult intracranial injury in infants. *Ann Emerg Med*. 1998;32(6):680-686.
- Laskey AL, Holsti M, Runyan DK, Socolar RR. Occult head trauma in young suspected victims of physical abuse. *J Pediatr*. 2004;144(6):719-722.
- Rubin DM, Christian CW, Bilaniuk LT, Zazychny KA, Durbin DR. Occult head injury in high-risk abused children. *Pediatrics*. 2003;111(6, pt 1):1382-1386.
- Greenes DS, Schutzman SA. Clinical indicators of intracranial injury in head-injured infants. *Pediatrics*. 1999;104(4, pt 1):861-867.
- Togioka BM, Arnold MA, Bathurst MA, et al. Retinal hemorrhages and shaken baby syndrome: an evidence-based review. *J Emerg Med*. 2009;37(1):98-106.
- Levin AV, Christian CW; Committee on Child Abuse and Neglect, Section on Ophthalmology. The eye examination in the evaluation of child abuse [published correction appears in *Pediatrics*. 2010;126(5):1053]. *Pediatrics*. 2010;126(2):376-380.
- Hatherill M, Levin M, Lawrenson J, Hsiao NY, Reynolds L, Argent A. Evolution of an adenovirus outbreak in a multidisciplinary children's hospital. *J Paediatr Child Health*. 2004;40(8):449-454.
- Ringenberg ML, Davidson GP, Spence J, Morris S. Prospective study of nosocomial rotavirus infection in a paediatric hospital. *Aust Paediatr J*. 1989;25(3):156-160.
- Thackeray JD, Scribano PV, Lindberg DM. Yield of retinal examination in suspected physical abuse with normal neuroimaging. *Pediatrics*. 2010;125(5):e1066-e1071. doi:10.1542/peds.2009-2184.
- Lindberg D, Makoroff K, Harper N, et al; ULTRA Investigators. Utility of hepatic transaminases to recognize abuse in children. *Pediatrics*. 2009;124(2):509-516.
- McGinn TG, Guyatt GH, Wyer PC, Naylor CD, Stiell IG, Richardson WS; Evidence-Based Medicine Working Group. Users' guides to the medical literature. XXII: how to use articles about clinical decision rules. *JAMA*. 2000;284(1):79-84.
- Hanley JA, Lippman-Hand A. If nothing goes wrong, is everything all right? interpreting zero numerators. *JAMA*. 1983;249(13):1743-1745.
- Katzman GH. Pathophysiology of neonatal subconjunctival hemorrhage. *Clin Pediatr (Phila)*. 1992;31(3):149-152.
- Kleemann WJ, Wiechern V, Schuck M, Tröger HD. Intrathoracic and subconjunctival petechiae in sudden infant death syndrome (SIDS). *Forensic Sci Int*. 1995;72(1):49-54.
- Morad Y, Avni I, Benton SA, et al. Normal computerized tomography of brain in children with shaken baby syndrome. *J AAPOS*. 2004;8(5):445-450.
- Johnson DL, Braun D, Friendly D. Accidental head trauma and retinal hemorrhage. *Neurosurgery*. 1993;33(2):231-235.
- Salehi-Had H, Brandt JD, Rosas AJ, Rogers KK. Findings in older children with abusive head injury: does shaken-child syndrome exist? *Pediatrics*. 2006;117(5):e1039-e1044. doi:10.1542/peds.2005-0811.
- Hobbs CJ. Skull fracture and the diagnosis of abuse. *Arch Dis Child*. 1984;59(3):246-252.
- Kemp AM, Dunstan F, Harrison S, et al. Patterns of skeletal fractures in child abuse: systematic review. *BMJ*. 2008;337:a1518. doi:10.1136/bmj.a1518.