

Picture of the Month

Lindsey Burghardt, MD; Mark I. Neuman, MD, MPH; Andrew J. Capraro, MD;
Mark S. Volk, MD, DMD; Joshua Nagler, MD

AN 11-MONTH-OLD BOY PRESENTED TO THE emergency department with a 24-hour history of barking cough and sudden onset of increased work of breathing. The family reported that his respiratory difficulty acutely worsened after a bout of forceful coughing shortly prior

to arrival. On examination, the patient was ill appearing. His vital signs revealed a respiratory rate of 50 breaths/min and oxygen saturation of 76% on room air. The patient was in moderate respiratory distress, with grunting and retractions noted. There was no stridor. Auscultation of the chest revealed decreased breath sounds on the left. A portable chest radiograph was obtained (**Figure 1**).

Author Affiliations: Division of Emergency Medicine (Drs Burghardt, Neuman, Capraro, and Nagler) and Department of Otolaryngology (Dr Volk), Children's Hospital Boston, Boston, Massachusetts.

See <http://www.archpediatrics.org> for the Picture of the Month Web Quiz: What is your diagnosis?

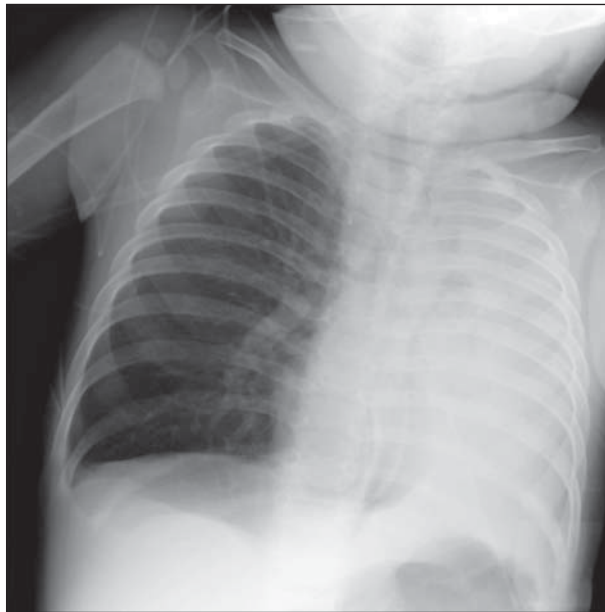


Figure 1. Chest radiograph demonstrates pneumomediastinum with subcutaneous emphysema. Additionally, there is near-complete collapse of the left lung with associated leftward mediastinal shift.