ARTICLE

Minocycline-Related Autoimmune Hepatitis

Case Series and Literature Review

Jonathan E. Teitelbaum, MD; Antonio R. Perez-Atayde, MD; Mark Cohen, MD; Athos Bousvaros, MD; Maureen M. Jonas, MD

Background: Minocycline is an antibiotic commonly used in the treatment of adolescent acne.

Objectives: To describe the clinical, laboratory, and histological features in 3 cases of minocycline-related autoimmune hepatitis and to review the literature of similar cases in the adolescent population.

Design: Case series.

Setting: Patients were cared for in the Division of Gastroenterology, Children's Hospital, Boston, Mass.

Results: Three adolescents (age, 15-16 years), while being treated with therapeutic doses of minocycline for periods of 12 to 20 months, met the 1993 International Autoimmune Hepatitis Group criteria for autoimmune hepatitis. All had a positive antinuclear antibody titer. Other features included hypergammaglobulinemia and a positive anti–smooth muscle antibody titer. Two patients underwent liver biopsy that revealed severe chronic lymphoplasmacytic inflammation, necrosis, and fibrosis. All other causes of liver disease were excluded. One patient had resolution of symptoms with withdrawal of the drug, while 2 required immunosuppression therapy. A review of the literature yielded only 18 similar cases, none in the pediatric literature, the majority of which contained incomplete pertinent data.

Conclusions: Minocycline is related to the development of autoimmune hepatitis in some adolescents. Pediatricians who use this drug for treatment of acne should be aware of this serious potential relation and stop the drug immediately when suspicion is raised.

Arch Pediatr Adolesc Med. 1998;152:1132-1136

Editor's Note: Minocycline-related autoimmune hepatitis seems to be a relatively rare problem. However, we need to be aware of the potential problems if we care for adolescents, in whom acne is hardly rare.

Catherine D. DeAngelis, MD

From the Combined Program in Gastroenterology and Nutrition (Drs Teitelbaum, Bousvaros, and Jonas) and the Department of Pathology (Dr Perez-Atayde), Children's Hospital, Harvard Medical School, Boston, Mass; and Acton Medical Associates, Acton, Mass (Dr Cohen).

MINOCYCLINE IS now the most widely prescribed systemic antibiotic for acne. Initial studies emphasized its relative safety and identified common adverse effects including headache, lightheadedness, vertigo, nausea, weakness, and rash.[1-3] As its use has increased, more serious sequelae have been identified, including serum sickness–like reaction, drug-induced lupus,[4] pneumonitis, hypersensitivity syndrome reaction, acute febrile neutrophilic dermatosis (Sweet disease), and hepatitis.[5] We describe 3 adolescents in whom autoimmune hepatitis developed related to minocycline use. While the manifestations and outcome of this illness are variable, the potential severity of the hepatitis warrants immediate attention and discontinuation of the drug in affected patients.

REPORT OF PATIENTS

PATIENT 1

A 15-year-old girl received oral minocycline, with variable compliance, in addition to a topical acne regimen (benzoyl peroxide, clindamycin phosphate, and tretinoin) for 18 months. Two months before her evaluation for liver disease, 100 mg of minocycline once daily was started with good compliance. During these 2 months, arthralgias in her knees, toes, fingers, and wrists; a livedo reticularis rash over her shins; intermittent fevers to 39°C; and fatigue developed. The results of the physical examination were normal with the exception of a violaceous serpiginous rash over both shins. The liver span was 6 cm, and there was no splenomegaly or lymphadenopathy. The laboratory evaluation demonstrated an aspartate aminotransfer-

©1998 American Medical Association. All rights reserved.
Downloaded From: http://archpedi.jamanetwork.com/ on 04/30/2017

ase (AST) level of 363 U/L (reference range, 2-40 U/L), an alanine aminotransferase (ALT) level of 459 U/L (reference range, 3-30 U/L), normal levels of bilirubin and albumin, a normal complete blood cell count, a normal prothrombin time (PT), and a normal partial thromboplastin time (PTT). The erythrocyte sedimentation rate was 57 mm/h (reference range, 0-30 mm/h). The antinuclear antibody (ANA) concentration was 15.0 IU/mL (reference range, <7.5 IU/mL), corresponding to a titer of 1:180 to 1:360 (reference range, <1:20) with homogeneous and speckled patterns, and the serum IgG level was elevated to 46 g/L (reference range, 5-12 g/L). The results of an abdominal ultrasonogram were normal. The minocycline was discontinued, and 1 week later, the AST level was 54 U/L, the ALT level was 101 U/L, and the serum IgG level was 39 g/L. After 5 weeks, the AST and ALT levels returned to normal.

PATIENT 2

A 15-year-old girl with a 1-year exposure to 200 mg of minocycline daily was examined because of midepigastric pain, jaundice, nausea, diarrhea, decreased appetite, and a 9.1-kg weight loss over 2 months. There was neither fever nor complaints of joint pain or discomfort. The physical examination revealed a liver span of 12 cm, jaundice, and spider angiomata. There was no splenomegaly, arthritis, or lymphadenopathy. An abdominal ultrasonogram revealed a heterogeneous liver. The laboratory evaluation revealed an AST level of 1530 U/L; an ALT level of 904 U/L, an alkaline phosphatase level of 259 U/L (reference range, 70-390 U/L); total and direct bilirubin levels of 157 and 109 µmol/L, respectively (reference range, 2-18 and 0-4 µmol/L, respectively); and a PT and PTT of 18.8 and 36.4 seconds, respectively (reference range, 11-13 and 21-30 seconds, respectively). The ANA titer was 1:160 with a diffuse pattern, and the anti–smooth muscle antibody (ASMA) titer was 1:160 (reference range, <1:20). The serum IgG level was 51.52 g/L. The minocycline was discontinued, and she was treated with corticosteroids. A liver biopsy performed 1 month later when the coagulopathy had resolved revealed characteristic features of chronic autoimmune hepatitis, including marked portal lymphoplasmacytic inflammation, diffuse hepatocellular damage, moderate necroinflammatory activity, and marked portal fibrosis (**Figure**, A and B). There was considerable lobular collapse, nodular transformation, and marked pericellular fibrosis (Figure, A and B). An attempt at tapering the dosage of prednisone at 1 month was associated with a reactivation of the hepatitis. The AST and ALT levels became normal after 9 months of treatment with corticosteroids and azathioprine.

PATIENT 3

A 16-year-old boy had been taking 100 to 200 mg of minocycline daily for 18 months before being examined because of a 1-month history of increasing fatigue, a decrease in appetite, and intermittent night sweats. The initial evaluation revealed an AST level of 707 U/L, an ALT level of 988 U/L, and a bilirubin level of 26 µmol/L. During the next month, myalgias in his calves, jaundice, a 6.8-kg weight loss, and pruritus developed. He had neither rash nor joint pain. The physical examination revealed icterus, tenderness in the right upper quadrant of the abdomen, enlargement of the spleen to 4 cm below the costal margin, and the absence of palpable lymph nodes. One month after the initial examination, the laboratory data revealed an AST level of 2046 U/L, and ALT level of 1299 U/L; a γ-glutamyltransferase level of 24 U/L (reference range, 11-50 U/L); total and direct bilirubin levels of 181 and 121 µmol/L, respectively; normal PT and PTT; and a white blood cell count of 6.6×10^9/L with 11% eosinophils. The ANA titer was 1:320 with a diffuse pattern, the serum IgG level was increased to 25.58 g/L, and the ASMA titer was 1:20. An abdominal ultrasonogram revealed a normal-appearing liver and splenomegaly (16.2 cm) with-

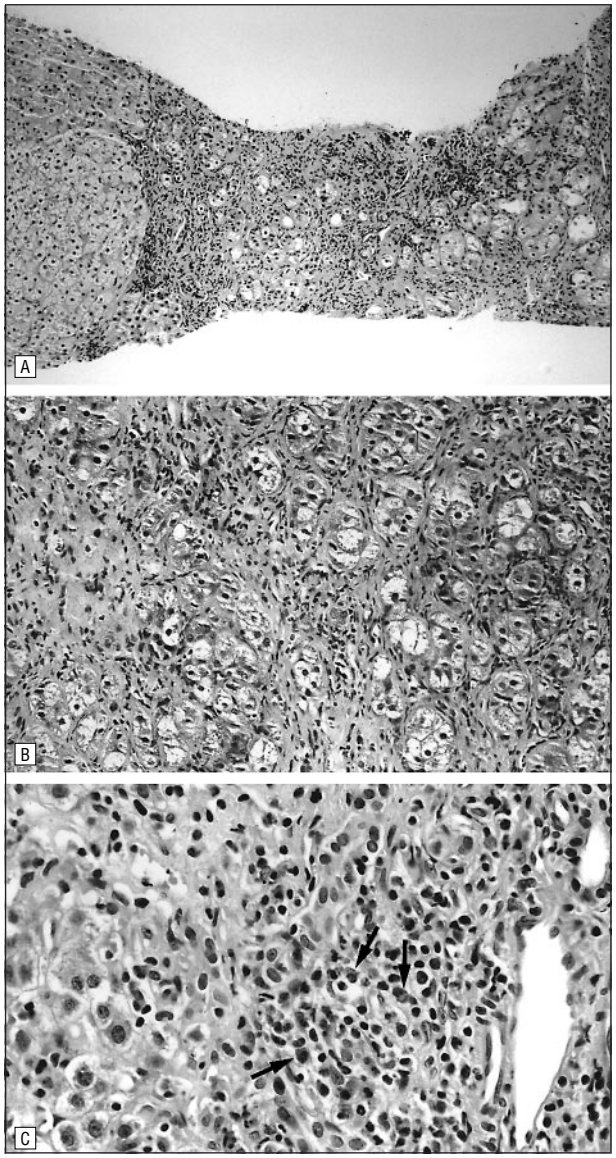

A, Patient 2. Needle liver biopsy specimen showing severe chronic hepatitis with marked parenchymal collapse, necroinflammatory activity, and focal nodular transformation with fibrosis. B, Patient 2. Higher magnification showing diffuse hepatocellular damage with ballooning and pseudoacinar transformation of hepatocytes. Chronic inflammation and pericellular fibrosis are evident. C, Patient 3. Needle liver biopsy showing chronic hepatitis with moderate necroinflammatory activity and numerous plasma cells (arrows). The portal tract is seen at the right side of the figure. All parts were stained with hematoxylin-eosin.

©1998 American Medical Association. All rights reserved.
Downloaded From: http://archpedi.jamanetwork.com/ on 04/30/2017

Clinical and Laboratory Data in Adolescent Patients With Minocycline-Related Autoimmune Hepatitis*

Reference	Sex/Age, y	Duration of Treatment, mo	Initial Complaints	ALT, U/L	AST, U/L
					Present
NA	F/15	20	Fever, rash, arthralgias, fatigue	459	363
NA	F/15	12	Epigastric pain, nausea, diarrhea, decreased appetite, weight loss	904	1503
NA	M/16	18	Night sweats, fatigue, weight loss, myalgias, decreased appetite	1299	2046
					Previous
Herzog et al[6]	F/16	18	Hashimoto thyroiditis, arthralgias	292	347
MacNeil et al[9]	F/17	0.75	Fever, rash, weight loss, lymphadenopathy	197	196
Malcolm et l[10]	F/15	1	Headache, nausea, anorexia, pruritus, abdominal pain	1908	1800
	M/17	4	Arthralgias	102	157
	M/17	24	Neutropenia, fatigue, pain	1200	41
	M/17	25	Anorexia, jaundice	3498	1366
Davies and Kersey[11]	M/16	1	Headache, fever, rash, malaise, hepatomegaly, lymphadenopathy	. . .	. . .
	F/17	1	Fever, rash, hepatic coma	. . .	182
Gough et al[12]	F/16	24	Polyarthritis, hepatitis	. . .	684
	F/16	24	Malaise, jaundice	. . .	915
Knowles et al[5]	F/16	0.75	Fever, headache, rash, lymphadenopathy	. . .	. . .
	M/16	1	Stevens-Johnson syndrome,fulminant hepatic failure, lymphadenopathy	. . .	. . .
	F/14	1	Fever, rash, splenomegaly, renal failure, lymphadenopathy	. . .	. . .
	F/17	1	Fever, rash, pulmonary edema, lymphadenopathy	. . .	. . .
Boudreaux et al[8]	F/17	. . .	Fulminant hepatic failure, coma, hepatorenal syndrome	. . .	. . .
Gough et al[12]	M/17	3	Hepatitis	. . .	. . .
	M/18	1	Hepatitis, jaundice	. . .	. . .
	M/18	7	Hepatitis	. . .	. . .

*NA indicates not applicable; ALT, alanine aminotransferase; AST, aspartate aminotransferase; GGT, γ-glutamyltransferase; ALKP, alkaline phosphatase; ANA, antinuclear antibody; ASMA, anti–smooth muscle antibody; PT, prothrombin time; PTT, partial thromboplastin time; ALKM, anti–liver-kidney-microsomal antibody; and INR, international normalized ratio. Ellipses indicate not reported. For reference ranges, see the text.

out focal lesion. The minocycline was discontinued. Despite this, his levels of AST and ALT did not decline, and he underwent liver biopsy 1 week later because of concern for substantial immune-related injury that might require immunosuppressive therapy. The biopsy revealed chronic hepatitis with diffuse hepatocellular damage, marked necroinflammatory activity, and marked portal and pericellular fibrosis with portal-to-portal bridging. The presence of numerous plasma cells was consistent with an autoimmune process (Figure, C). He was treated with oral prednisone. Within 2 weeks his laboratory abnormalities and visceromegaly resolved. With tapering of the corticosteroid dosage, azathioprine therapy was started, and 2 months later he was asymptomatic (except for severe acne).

All patients had negative serologic test results for hepatitis A, B, and C; Epstein-Barr virus; and cytomegalovirus, in addition to normal ceruloplasmin levels, iron studies, and α_1-antitrypsin levels. No patient had anti–liver-kidney-microsomal antibody.

COMMENT

Drug-induced hepatotoxic effects are common and have been attributed to a wide variety of antibiotics including tetracycline hydrochloride, isoniazid, sulfonamides, and nitrofurantoin. Although many drugs are associated with the development of autoantibodies, drug-associated autoimmune hepatitis is much less common and has been described with pemoline, ticrynafen, and hydralazine hydrochloride. In the latter 2 medications, covalent binding of a drug metabolite with the metabolizing protein CYP2C9 or 1A2 results in an antigenic molecule with secondary immune response resulting in hepatitis.[6]

Minocycline is a synthetically modified tetracycline with a broad antimicrobial spectrum and activity against *Staphylococcus* organisms and anaerobes. This attribute, along with its long half-life of 11 to 13 hours, makes it an attractive choice in the treatment of acne in adolescents. Because of the known hepatotoxic effects of the parent drug, tetracycline, the effect of intravenous minocycline in mice was studied. Although increases in AST and bilirubin values were noted, there were no morphologic abnormalities in the livers.[7] When the safety of minocycline in 200 humans (mean age, 21.6 years) at doses up to 200 mg/d was monitored with aminotransaminase levels every 3 months (range 2 weeks to 4 years), no significant biochemical abnormalities were detected.[1] Despite this, case reports of hepatic injury began to emerge

©1998 American Medical Association. All rights reserved.
Downloaded From: http://archpedi.jamanetwork.com/ on 04/30/2017

Bilirubin µmol/L	GGT, U/L	ALKP, U/L	ANA	ASMA	PT/PTT	Other	Hepatic Histologic Features	Additional Treatment	Outcome
Report									
10	48	246	1:180	Negative	13.1/32.1	ALKM, negative	. . .	. . .	Normal
157	56	259	1:160	1:160	18.8/36.4	ALKM, negative	Chronic inflammation, fibrosis	Corticosteroids, azathioprine	Remission with treatment
181	24	191	1:320	1:20	11.8/27.7	ALKM, negative; IgG, 2.55 g/L	Chronic inflammation, fibrosis	Corticosteroids, azathioprine	Remission with treatment
Report									
. . .	. . .	. . .	1:1280	Negative	. . .	ALKM, negative	Chronic portal inflammation	. . .	Normal
55	259	1061	. . .	. . .	16.3/38.8	. . .	. . .	Corticosteroids	Normal in 2 d
81	85	. . .	. . .	1:128	. . .	ALKM, negative	. . .	. . .	Normal in 38 wk
. . .	. . .	207	. . .	1:2560	. . .	INR, 1.3	Chronic hepatitis with eosinophils	Corticosteroids, azathioprine	Normal
55	122	221	. . .	. . .	. . .	. . .	. . .	. . .	Normal
83	134	238	. . .	. . .	. . .	. . .	. . .	. . .	Normal
. . .	395	. . .	. . .	. . .	. . .	. . .	. . .	. . .	Normal
. . .	417	56	. . .	. . .	. . .	. . .	. . .	. . .	Liver transplantation, death
9	. . .	. . .	1:80	Negative	. . .	ALKM, negative	Chronic active hepatitis	. . .	Normal in 3 mo
170	. . .	. . .	1:640	Negative	. . .	ALKM, negative	Chronic active hepatitis	. . .	Normal in 3 mo
. . .	. . .	. . .	. . .	. . .	. . .	. . .	. . .	. . .	Normal
. . .	. . .	. . .	. . .	. . .	. . .	. . .	. . .	Corticosteroids	Normal
. . .	. . .	. . .	. . .	. . .	. . .	. . .	. . .	Corticosteroids	Normal
. . .	. . .	. . .	. . .	. . .	. . .	. . .	. . .	Corticosteroids	Normal
. . .	. . .	. . .	. . .	. . .	. . .	. . .	. . .	. . .	Liver transplantation
. . .	. . .	. . .	. . .	. . .	. . .	. . .	. . .	. . .	. . .
. . .	. . .	. . .	. . .	. . .	. . .	. . .	. . .	. . .	. . .
. . .	. . .	. . .	. . .	. . .	. . .	. . .	. . .	. . .	. . .

12 years after minocycline became widely available, and more than 45 cases of minocycline-related autoimmune hepatitis have now been reported in the medical literature not targeted to pediatric practitioners, with various degrees of morbidity ranging from reversible elevations in aminotransferase levels to fulminant hepatic failure requiring liver transplantation.[8]

Before the present report, 18 adolescents with minocycline-related liver injury have been described, and the proportion of the liver injuries that were immune-mediated or associated with autoantibodies is unclear.[5,6,8-12] The medical literature targeted to pediatric practitioners contains no cases, suggesting that this entity is underreported. Available clinical and laboratory data are summarized in the **Table**. The hepatic histopathologic features were described for only 4 of the 18 adolescents, although 5 were treated with corticosteroids, and 2 underwent liver transplantation. The pediatric experience roughly reflects that of Gough et al[12] who reviewed all patients with minocycline-induced lupus and autoimmune hepatitis in the United Kingdom through April 1994. There was a slight female predominance (57% [12/21]) and variable duration of exposure to minocycline (21 days to 2 years). Clinical features of the illness included fever (33% [7/21]), polyarthralgia (19% [14/21]), rash (39% [8/21]), malaise, anorexia, and jaundice. The prognosis was highly variable; many recovered with simple withdrawal of the antibiotic (as in our case 1), while others required prolonged immunosuppression (as in our cases 2 and 3).

The distinction should be made between direct hepatotoxic effects of the drug and drug-associated immune-mediated injury. The patients we describe met the 1993 International Autoimmune Hepatitis Group criteria for the diagnosis of autoimmune hepatitis,[13] which are as follows:

1. histological evidence of chronic hepatitis with periportal or periseptal piecemeal necrosis and a predominantly lymphoplasmacytic infiltrate;
2. abnormal levels of serum ALT and AST, especially if alkaline phosphatase activity is not markedly elevated;
3. serum immunoglobulin (total globulin or IgG) concentration greater than 1.5 times the upper limit;
4. seropositivity for antinuclear, smooth muscle actin, or liver-kidney-microsomal-1 antibodies at titers greater than 1:20; and
5. absence of evidence for viral, metabolic, or alcoholic hepatitis.

©1998 American Medical Association. All rights reserved.
Downloaded From: http://archpedi.jamanetwork.com/ on 04/30/2017

In typical toxin-mediated hepatic injury, there is microvesicular steatosis, portal tract sparing, and a sparse monocellular infiltrate. In addition, toxic damage would not be expected to resolve with immunosuppressive therapy.

Herzog et al[6] analyzed the serum of an affected patient and found multiple autoantibodies, including those to 50- and 90-kd proteins on human hepatoma cells and to rat P-450 proteins. They speculated that an antibody reaction against a yet unknown metabolite of minocycline cross-reacts with several microsomal cytochromes. Whether some patients (particularly those requiring transplantation or immunosuppression) have a genetic predisposition to autoimmune disease remains unclear. Others who responded to withdrawal of the drug alone may be reacting to an antigen that bears similarity to an autoantigen. Whether the minocycline is responsible for the autoimmune hepatitis in this large population of adolescents exposed to the drug is difficult to determine; causation is supported by the number of reports linking the two,[5,6,8-12] the association of minocycline with other autoimmune diseases like lupus,[4,5,12] and the resolution of symptoms in the majority of affected patients when the drug is withdrawn.

Minocycline is now the most widely prescribed systemic antibiotic for acne. Although autoimmune disorders associated with this drug are uncommon, pediatricians must be aware of these potentially life-threatening adverse reactions. Minocycline-related autoimmune hepatitis should be suspected in any patient with rash, unexplained fever, arthralgias, or malaise who is taking the drug. Detection of elevated levels of AST and ALT, serum immunoglobulins, and autoantibodies supports this diagnosis. There are no data to predict the patients who are at greater risk of developing hepatitis, nor is there evidence to support routine monitoring of AST and ALT levels. Prevention of serious sequelae can be accomplished through judicious use of the antibiotic, patient education about potential adverse reactions, and quick cessation of the offending agent when suspicion is raised.

Since the manuscript was accepted for publication, we have cared for a 17-year-old girl who presented with acute, severe hepatitis after taking minocycline for 1 year. At presentation, the ALT level was 1639 U/L, PTwas 14.3 seconds, and ANA was found in her serum sample. Infectious and metabolic causes of hepatitis were excluded. Minocycline was discontinued, and the hepatitis rapidly improved, with ALT level decreased to 287 U/L 16 days later. Liver biopsy was not performed because of the prompt improvement.

Accepted for publication June 5, 1998.

Supported in part by training grant T32-DK-07477 (Dr Teitelbaum), and the General Clinical Research Center Clinical Associate Position award 2M01 RR 02172 (Dr Bousvaros) from the National Institutes of Health, Bethesda, Md.

Corresponding author: Maureen M. Jonas, MD, GI Division, Hunnewell Bldg, Ground Floor, Children's Hospital, 300 Longwood Ave, Boston, MA 02115.

REFERENCES

1. Goulden V, Glass D, Cunliffe WJ. Safety of long-term high-dose minocycline in the treatment of acne. *Br J Dermatol.* 1996;134:693-695.
2. Gump DW, Ashikaga T, Fink TJ, Radin AM. Side effects of minocycline: different dosage regimens. *Antimicrob Agents Chemother.* 1977;19:642-646.
3. Fanning WL, Gump DW, Sofferman RA. Side effects of minocycline: a double-blind study. *Antimicrob Agents Chemother.* 1977;11:712-717.
4. Atkin E, Miller LC, Tucker LB. Minocycline-induced lupus in adolescents. *Pediatrics.* 1998;101:926-928.
5. Knowles SR, Shapiro L, Shear NH. Serious adverse reactions induced by minocycline: report of 13 patients and review of the literature. *Arch Dermatol.* 1996; 132:934-939.
6. Herzog D, Hajoui O, Russo P, Alvarez F. Study of immune reactivity of minocycline-induced chronic active hepatitis. *Dig Dis Sci.* 1997;42:1100-1103.
7. Bocker R, Estler CJ, Ludewig-Sandig D. Evaluation of the hepatotoxic potential of minocycline. *Antimicrob Agents Chemother.* 1991;35:1434-1436.
8. Boudreaux JP, Hayes DH, Mizrahi S, Hussey J, Regenstein, Balart L. Fulminant hepatic failure, hepatorenal syndrome, and necrotizing pancreatitis after minocycline hepatotoxicity. *Transplant Proc.* 1993;25:1873.
9. MacNeil M, Haase DA, Tremaine R, Marrie TJ. Fever, lymphadenopathy, eosinophilia, lymphocytosis, hepatitis, and dermatitis: a severe adverse reaction to minocycline. *J Am Acad Dermatol.* 1997;36:347-350.
10. Malcolm A, Heap TR, Eckstein RP, Lunzer MR. Minocycline-induced liver injury. *Am J Gastroenterol.* 1996;91:1641-1643.
11. Davies MG, Kersey PJW. Acute hepatitis and exfoliative dermatitis associated with minocycline. *Arch Intern Med.* 1994;154:1983-1984.
12. Gough A, Chapman S, Wagstaff K, Emery P, Elias E. Minocycline induced autoimmune hepatitis and systemic lupus erythematosus-like syndrome. *BMJ.* 1996; 312:169-172.
13. Johnson PJ, McFarlane IG. Meeting report: international autoimmune hepatitis group. *Hepatology.* 1993;18:998-1005.

©1998 American Medical Association. All rights reserved.
Downloaded From: http://archpedi.jamanetwork.com/ on 04/30/2017