

SECTION EDITOR: ENID GILBERT-BARNES, MD

Pathological Case of the Month

Christof Dame, MD; Ingrid Hausser, ScD; Janique Geukens, MD; Rolf E. Brenner, MD

SKIN HYPEREXTENSIBILITY was present in a 10-year-old girl (**Figure 1**). After minor injuries, connective tissue fragility manifested as easy bruising; the wounds were widely gaping, and more than 20 surgical procedures were performed. Thin, brownish, discolored, atrophic

From the Children's Hospital (Drs Dame and Brenner) and the Department of Dermatology (Dr Geukens), University of Bonn, Bonn, Germany; and the Institute for Ultrastructure Research of the Skin, Department of Dermatology, Ruprecht-Karls University, Heidelberg, Germany (Dr Hausser). Dr Brenner is now with the Division for Biochemistry of Joint and Connective Tissue Diseases, Department of Orthopaedics, University of Ulm, Ulm, Germany.

scars with a papyraceous appearance were found on typical pressure points such as the forehead, elbows, and knees. On the elbows, molluscoid pseudotumors were obvious. Joint hypermobility was shown by passive and active dorsiflexion of the fingers, passive opposition of the thumbs to the flexor aspect of the forearm, and hypermobility of the elbows and knees. Kyphoscoliosis and multiple hematomas were obvious. Within the patient's family, similar clinical features were reported for her father and her great grandmother. Electron micrographs of the patient's skin showed numerous "composite" collagen fibrils, described as "cauliflower" deformity within the whole dermal connective tissue (**Figure 2** and **Figure 3**).

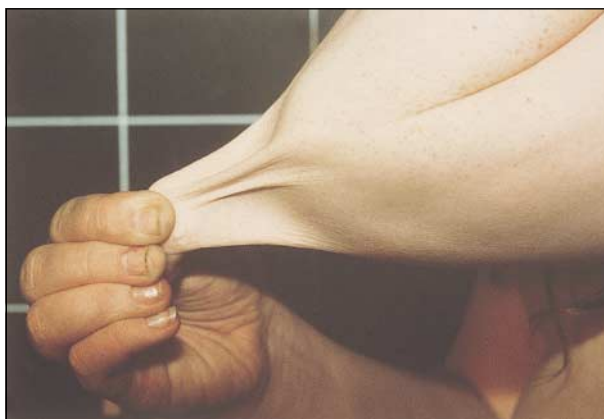

Figure 1.

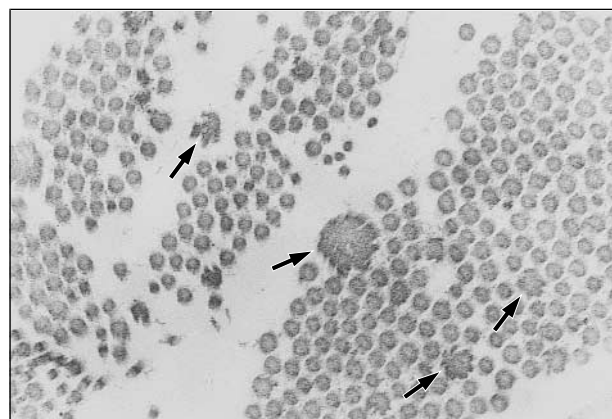


Figure 2.

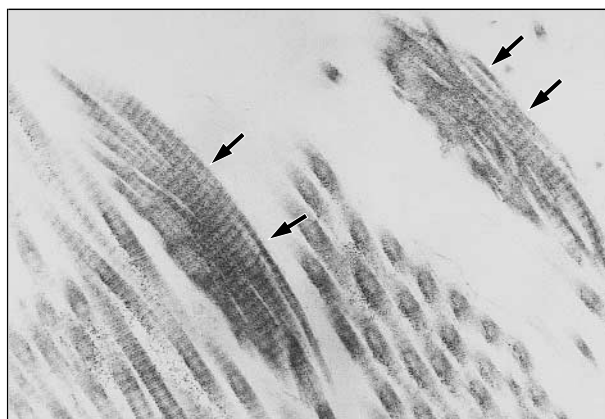


Figure 3.

Diagnosis and Discussion

Ehlers-Danlos Syndrome—Classical Type

Figure 1. Skin hyperextensibility in a 10-year-old girl.

Figure 2. Electron micrograph of the patient's skin shows collagen fibrils in cross sections with "flowerlike" servated contours, so-called composite fibrils (arrows) (magnification $\times 36000$).

Figure 3. Collagen fibrils of the patient's skin in longitudinal sections (magnification $\times 36000$). Arrows indicate broadened and twisted ropes.

A heterogeneous group of heritable connective tissue disorders characterized by skin hyperextensibility, tissue fragility, and articular hypermobility is summarized as Ehlers-Danlos syndrome (EDS). In 1997, classification of EDS was revised and simplified.¹ Six types of EDS were defined based on clinical features (major and minor criteria) and biochemical and molecular findings.¹ For diagnosis of a specific type of EDS, the presence of 1 or more major criteria is necessary, complemented by positive findings on laboratory tests when possible. The major criteria have high diagnostic specificity because they are infrequent in other conditions or in healthy people. Minor criteria have lower diagnostic specificity, but the presence of 1 or more minor criteria contributes to the diagnosis of a specific type.¹

This patient fulfills all the major diagnostic criteria for the diagnosis of the classical type of EDS, showing skin hyperextensibility, widened atrophic scars as a manifestation of tissue fragility, and joint hypermobility. The classical type of EDS—described in the old Berlin classification² as EDS I in severe cases or as EDS II if moderate severity was observed—has an autosomal dominant inheritance. Moreover, we found 7 of 9 minor criteria of the classical type in this patient: smooth, velvety skin (+); molluscoid pseudotumors (+); subcutaneous spheroids (-); complications of joint hypermobility (eg, pes planus) (+); muscle hypotonia/delayed gross motor development (-); easy bruising (+); manifestations of tissue extensibility and fragility (+); surgical complications (+); and positive family history (+). Specific advice for the diagnosis of skin hyperextensibility, tissue fragility, and easy bruising despite normal coagulation status are described.³ Joint hypermobility should be assessed using the Beighton scale.⁴

The diagnosis of EDS was confirmed in our patient and her father for the first time when the girl was 10 years old. The diagnosis of skin hyperextensibility in young children can be difficult and delayed because of the abundance of subcutaneous fat.¹ Early diagnosis would help to prevent additional complications (eg, by avoiding injury and using fibrin glue after injury).

Within the dermis of patients with EDS, differential ultrastructural abnormalities of collagen fibrils can be found by electron microscopy.⁵ By light microscopy, in our patient and her father, the epidermis was normal but the dermal connective tissue was loosely packed. Only small col-

lagen bundles could be found, and generally the amount of collagen was diminished compared with the elastic structures. By electron microscopy, many aberrant collagen fibrils became obvious, beginning in the papillary dermis and increasing in number within the reticular dermis. These composite collagen fibrils with enlarged "flowerlike" cross sections and ropelike longitudinal sections are characteristic, but not specific, for the classical types of EDS.⁵ However, the combination of clinical symptoms and the pattern of ultrastructural collagen changes is highly specific for classical EDS.^{1,5} Abnormal electrophoretic mobility of the pro α 1(V) or pro α 2(V) chains of type V collagen as well as genetic linkage to intragenic markers of the *COL5A1* and *COL5A2* genes and mutations in the respective genes can be found in several but not most patients with the classical type of EDS.^{3,6-8} The kyphoscoliotic type of EDS (EDS VI in the old classification), however, can be excluded by a normal ratio (6:1) of hydroxylysyl-pyridinoline to lysyl-pyridinoline in urine.⁹

The new classification of EDS includes clinical and laboratory findings that are useful for diagnosis of the classical type of EDS, although there is still considerable clinical and ultrastructural heterogeneity among patients.

Accepted for publication July 1, 1999.

Corresponding author: Christof Dame, MD, Children's Hospital, University of Bonn, Adenauerallee 119, D-53113 Bonn, Germany (e-mail: dame@uni-bonn.de).

REFERENCES

1. Beighton P, De Paepe A, Steinmann B, Tsipouras P, Wenstrup RJ. Ehlers-Danlos syndromes: revised nosology, Villefranche, 1997. *Am J Med Genet.* 1998; 77:31-37.
2. Beighton P, De Paepe A, Danks D, et al. International nosology of heritable disorders of connective tissue. *Am J Med Genet.* 1988;29:581-594.
3. Steinmann B, Royce PM, Superti-Furga A. The Ehlers-Danlos syndrome. In: Royce PM, Steinmann B, eds. *Connective Tissue and Its Heritable Disorders: Molecular, Genetic and Medical Aspects.* New York, NY: Wiley-Liss Inc; 1993:351-407.
4. Beighton P, Grahame R, Bird H. *Hypermobility of Joints.* 2nd ed. Berlin, Germany: Springer-Verlag; 1989:1-182.
5. Hausser I, Anton-Lamprecht I. Differential ultrastructural aberrations of collagen fibrils in Ehlers-Danlos syndrome types I-IV as a means of diagnostics and classification. *Hum Genet.* 1994;3:394-407.
6. Byers PH. Ehlers-Danlos syndrome: recent advances and current understanding of the clinical and genetic heterogeneity. *J Invest Dermatol.* 1994;103: 47S-52S.
7. De Pape A, Nuytinck L, Hausser I, Anton-Lamprecht I, Naeyaert JM. Mutations in the *COL5A1* gene are causal in the Ehlers-Danlos syndromes I and II. *Am J Hum Genet.* 1997;60:547-554.
8. Michalickova K, Susic M, Willing MC, Wenstrup RJ, Cole WG. Mutations of the α 2(V) chain of type V collagen impair matrix assembly and produce Ehlers-Danlos syndrome I. *Hum Mol Genet.* 1998;7:249-255.
9. Acil Y, Vetter U, Brenner R, Müller PK, Brinckmann J. Ehlers-Danlos syndrome type VI: cross-link pattern in tissue and urine sample as a diagnostic marker. *J Am Acad Dermatol.* 1995;33:522-524.