

SECTION EDITOR: WALTER W. TUNNESSEN, JR, MD

Picture of the Month

Yann-Jinn Lee, MD; Hsi-Che Liu, MD; Hung-Chang Lee, MD; Chi-Yuan Tzen, MD;
Chi-Yu Huang, MD; Tsen-Long Yang, MD

A 10-YEAR-OLD GIRL underwent reduction cheiloplasty and excision of tongue nodules. The development of progressively patulous lips and thickening of the tongue began at age 6 years. Following surgery, a right neck mass was discovered. Thyroid scan revealed an enlarged gland with a cold area in the upper two thirds of the right lobe. A right thyroidectomy was performed. Her medical history included abdominal distension and the onset of severe constipation at age 4 years,

From the Departments of Pediatrics (Drs Y.-J. Lee, H.-C. Liu, H.-C. Lee, and C.-Y. Huang), Pathology (Dr C.-Y. Tzen), Medical Research (Dr Y.-J. Lee), and Surgery (Dr T.-L. Yang), Mackay Memorial Hospital, and the Department of Pediatrics (Drs Y.-J. Lee and H.-C. Lee), Taipei Medical University, Taipei, Taiwan.

which responded to medical treatment. On physical examination thick lips and an enlarged, nodular tongue were present (**Figure 1** and **Figure 2**). A firm, visibly enlarged goiter was palpable in the left thyroid gland. An ultrasound study demonstrated an enlarged left lobe of the thyroid with 2 hypoechoic nodules and bilateral, enlarged cervical lymph nodes. Her serum calcitonin level was 299 pmol/L (reference, <26.6 pmol/L). A total thyroidectomy was performed with modified radical neck dissection. Pathologic interpretation of the removed tissue revealed medullary thyroid carcinoma (MTC) with metastases to the cervical lymph nodes. A review of the tongue biopsy specimen was consistent with mucosal neuromas. DNA sequencing analysis of exon 16 of the RET proto-oncogene from peripheral blood cells showed a germline M918T mutation (**Figure 3**).

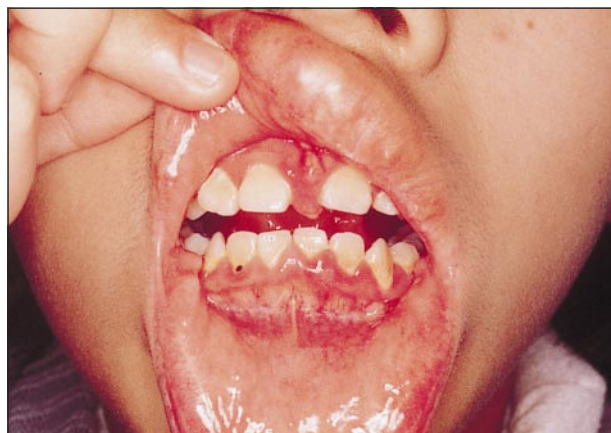

Figure 1.

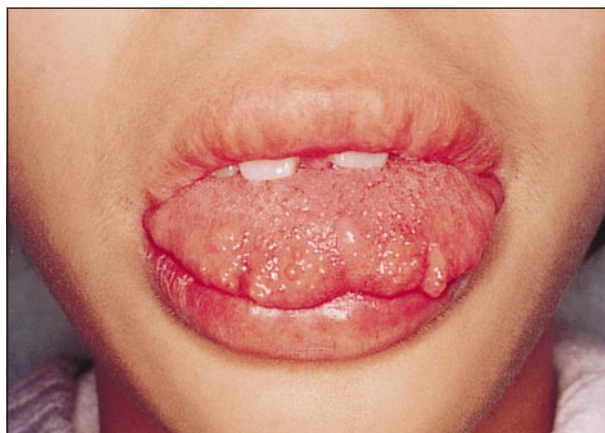

Figure 2.

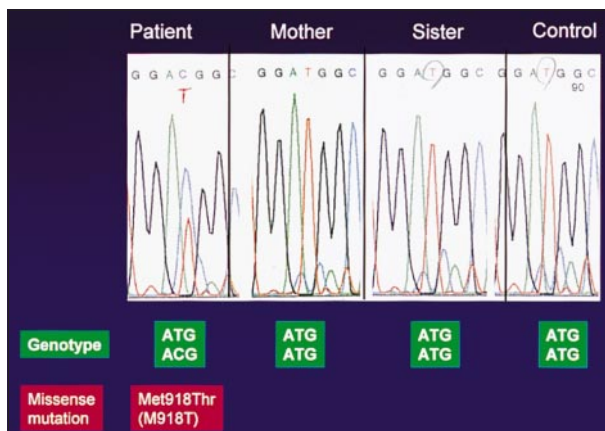


Figure 3.

Denouement and Discussion

Multiple Endocrine Neoplasia 2B Syndrome

Figure 1. The lips are thick with nodules on the buccal mucosa at the angles of the mouth.

Figure 2. Nodules are noted lateral to an indented scar at the tip of the tongue from previous surgery.

Figure 3. DNA sequencing analysis of exon 16 of the RET proto-oncogene of the patient, her mother, sister, and control. A T→C transition in codon 918 is present in the patient; findings for the mother and sister were normal. This single point mutation results in the substitution of threonine for methionine (M918T) in the tyrosine kinase domain of the RET protein.

Multiple endocrine neoplasia 2B syndrome (MEN 2B) is a rare disorder inherited as an autosomal dominant trait. It is characterized by multiple mucosal neuromas, MTC, and pheochromocytoma.¹

CLINICAL FEATURES

Characteristic findings on physical examination include elongated facies; mucosal neuromas on the lips, eyelids, buccal mucosa, tongue, palate, and intestinal mucous membranes; thickened medullated corneal nerves on slitlamp examination; marfanoid habitus; kyphoscoliosis; joint laxity; and pes cavus.^{2,3} Gastrointestinal manifestations, such as abdominal distension, feeding problems, dysphagia, vomiting, chronic constipation, intermittent abdominal pain, megacolon, and ganglioneuromatosis, may be seen in infancy.³ Constipation may suggest Hirschsprung disease.

Mucosal neuromas and MTC occur in all affected patients. A marfanoid habitus is present in 75% of patients, while enteric ganglioneuromatosis is found in more than 40% and pheochromocytoma in 50% of those affected.¹ A main criterion for differentiation of MEN 2B from MEN 2A is the absence of mucosal neuromas in the latter.

Although full-blown manifestations of this disorder should facilitate recognition, in infancy or early childhood, when only gastrointestinal signs and symptoms are present, the diagnosis may be difficult. MEN 2B should be included in the differential diagnosis of chronic constipation in young children, and careful evaluation for clinical findings should be performed and genetic testing considered.³

MOLECULAR BASIS

Genetic alterations of the RET proto-oncogene have been identified in 95% to 98% of patients with MEN 2B, with a germline mutation most frequently at codon 918^{4,5} and, rarely, at codon 883.⁶ Screening is hampered because at least 50% of the cases are caused by de novo mutations.⁵

SURGICAL THERAPY

Total thyroidectomy is the primary treatment of MTC,⁷ which is almost universally bilateral and multifocal in

MEN 2B cases and is associated with a high incidence of metastasis at the time of diagnosis.⁸ Extensive lymphadenectomy should be performed at the time of initial thyroidectomy, and reoperative lymphadenectomy must be considered in patients with persistently elevated calcitonin levels after thyroidectomy.⁷ Monitoring serum calcitonin levels is useful in identifying the occurrence of metastatic disease.

Early detection of individuals at risk for MEN 2B by genetic screening allows prophylactic thyroidectomy to be carried out before metastasis occurs. Because MTC has been diagnosed in a 6-month-old infant with MEN 2B,⁸ and metastatic MTC has been found in children younger than 5 years,⁹ prophylactic total thyroidectomy before age one² or five¹⁰ years has been proposed.

PROGNOSIS

The 5-year survival rate for MTC is 70% to 80%. Good prognostic factors are young age at diagnosis, female sex, occurrence in families, and tumor confinement to the thyroid gland.¹¹ Periodic evaluation for pheochromocytoma should continue indefinitely after MEN 2B is identified.

Accepted for publication May 3, 2000.

This research was supported by NSC grant 88-2314-B-195-012 from the National Science Council, Executive Yuan, Taiwan.

Reprints: Tsen-Long Yang, MD, Department of Surgery, Mackay Memorial Hospital, 92 Chung-San N Rd, Section 2, Taipei 10449, Taiwan.

REFERENCES

1. Morrison PJ, Nevin NC. Multiple endocrine neoplasia type 2B (mucosal neuroma syndrome, Wagenmann-Froboese syndrome). *J Med Genet.* 1996;33:779-782.
2. O'Riordain DS, O'Brien T, Crotty TB, et al. Multiple endocrine neoplasia type 2B: more than an endocrine disorder. *Surgery.* 1995;118:936-943.
3. de Krijger RR, Brooks A, van der Harst E, et al. Constipation as the presenting symptom in de novo multiple endocrine neoplasia type 2B. *Pediatrics.* 1998;102:405-408.
4. Hofstra RMW, Landsvater RM, Ceccherini I, et al. A mutation in the RET proto-oncogene associated with multiple endocrine neoplasia type 2B and sporadic medullary thyroid carcinoma. *Nature.* 1994;367:375-376.
5. Carlson KM, Dou S, Chi D, et al. Single missense mutation in the tyrosine kinase catalytic domain of the RET proto-oncogene is associated with multiple endocrine neoplasia type 2 B. *Proc Natl Acad Sci U S A.* 1994;91:1579-1583.
6. Gimm O, Marsh DJ, Andrew SD, et al. Germline dinucleotide mutation in codon 883 of the RET proto-oncogene in multiple endocrine neoplasia type 2B without codon 918 mutation. *J Clin Endocrinol Metab.* 1997;82:3902-3904.
7. Fleming JB, Lee JE, Bouvet M, et al. Surgical strategy for the treatment of medullary thyroid carcinoma. *Ann Surg.* 1999;230:697-706.
8. O'Riordain DS, O'Brien T, Weaver AL, et al. Medullary thyroid carcinoma in multiple endocrine neoplasia types 2A and 2B. *Surgery.* 1994;116:1017-1023.
9. Kaufman FR, Roe TF, Isaacs H Jr, Weitzman JJ. Metastatic medullary thyroid carcinoma in young children with mucosal neuroma syndrome. *Pediatrics.* 1982;70:263-267.
10. Eng C, Ponder BAJ. Multiple endocrine neoplasia type 2 and medullary thyroid carcinoma. In: Grossman A, ed. *Clinical Endocrinology.* 2nd ed. Oxford, England: Blackwell Science Ltd; 1998:635-650.
11. Saad MF, Ordonez NG, Rashid RK, et al. Medullary carcinoma of the thyroid: a study of the clinical features and prognostic factors in 161 patients. *Medicine (Baltimore).* 1984;63:319-342.