

SECTION EDITOR: ENID GILBERT-BARNES, MD

## Pathological Case of the Month

Atilano Lacson, MD; Kenneth Washington, MD; Gerald Tuite, MD; Robert Nuttall, MD

**A** PREVIOUSLY healthy 6-year-old boy received lamotrigine after examination for seizures involving the left face and arms. Cranial computed tomography showed a probable brain tumor. Surgery was deferred because of family relocation. On examination 3 months later, he was awake, alert, and had no focal neurological signs. A repeated magnetic resonance imaging study revealed a densely enhancing focal lesion in the right parietal region with mild edema of the underlying white matter (**Figure 1**). Additionally, he had mild maxillary

*From the Department of Surgery, Division of Pathology (Drs Lacson and Washington), Division of Neurosurgery (Dr Tuite), and the Department of Medicine, Division of Radiology (Dr Nuttall), All Children's Hospital, St Petersburg, Fla.*

and ethmoid sinus disease. He underwent a right frontal craniotomy under Stealth guidance. The lesion was partly adherent to the overlying dura mater and was within a portion of the premotor cortex, which was excised. The entire lesion was resected. Biopsy findings revealed a lesion that was well-demarcated from the surrounding brain and consisted of islands and broad zones of reactive, granulation tissue–like whorls of fibrocapillary proliferation with a diffuse infiltrate of lymphocytes, plasma cells, and histiocytes (**Figure 2**). Plasma cells and histiocytes dominate the inflammatory components. The lesion contained many lipid-rich histiocytes, collagen, and cells that express HLA-DR, CD20, and CD68 (**Figure 3**). The patient was discharged after surgery with mild residual facial weakness. At last follow-up, he was seizure free.

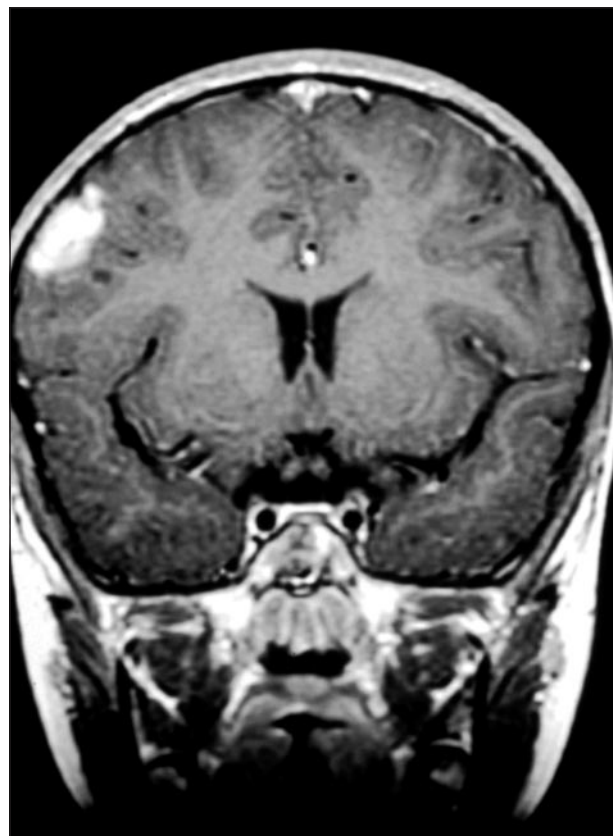


Figure 1.

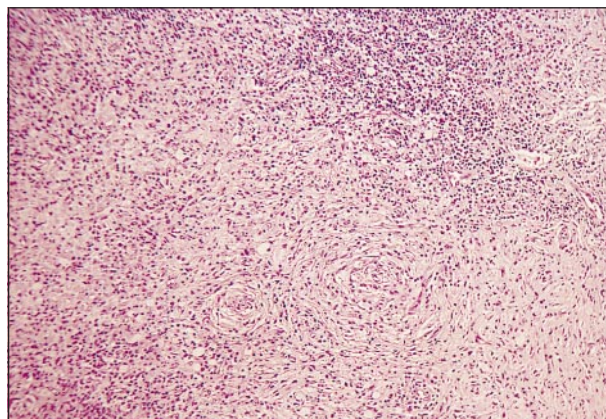


Figure 2.

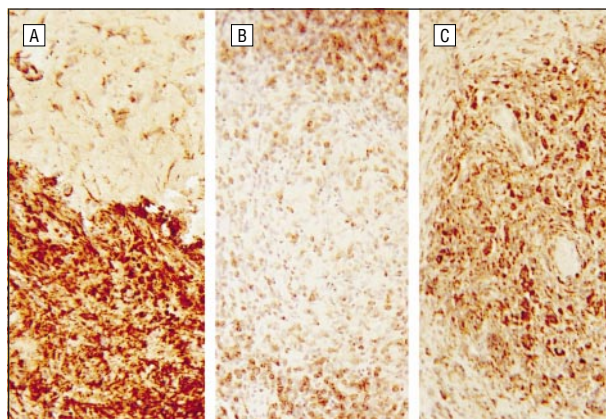


Figure 3.

# Diagnosis and Discussion

## Intracranial Plasma Cell Granuloma

**Figure 1.** Discrete intracortical densely enhancing lesion with sharp borders on T2-weighted image at the level of corpus striatum.

**Figure 2.** Spindle-shaped cells form whorls and ill-defined fascicles resembling a meningioma, mixed with a diffuse mononuclear infiltrate containing histiocytes (hematoxylin-eosin, original magnification  $\times 40$ ).

**Figure 3.** Most of the inflammatory cells express HLA-DR (A), CD20 (B), and CD68 (C) (avidin-biotin immunoperoxidase method, original magnification  $\times 100$ ).

**P**lasma cell granuloma is a rare pulmonary lesion of children and young adults, often discovered as an incidental mass on routine examination. A minority of cases catch clinical attention because of an associated syndrome of fever, anemia, and leukocytosis. Extrapulmonary plasma cell granuloma occurs in various locations. Other names given to this condition include inflammatory pseudotumor, xanthomatous pseudotumor, low-grade inflammatory fibrosarcoma, plasma cell pseudotumor, inflammatory meningeal mass of unexplained origin, meningioma with conspicuous plasma cell lymphocytic components, hyalinizing plasmacytic granulomatosis, inflammatory myofibrohistiocytic proliferation,<sup>1</sup> and inflammatory myofibroblastic tumor.<sup>2</sup>

In the intracranial location, plasma cell granuloma often presents with headache, seizure, paresis, vision disturbance, ataxia or vertigo, gait disturbance, and decreased consciousness. The intracranial localization varies; in a recent series of 29 cases, 8 were found to be intraparenchymal (6 of these were in the right frontal lobe), 19 were meningeal based, 1 had meningeal and parenchymal components, and 1 was unknown. In some cases, hematological abnormalities were commonly observed, including leukocytosis (5/8), hypochromic anemia (3/8), thrombocytosis (3/8), low ferritin levels (2/8), elevated erythrocyte sedimentation rate in most patients, and hypergammaglobulinemia (8/15).<sup>3</sup> Histologically, the lesion is invariably composed of myofibroblasts, polyclonal plasma cells with Russell bodies, lymphocytes with or without germinal centers, and

eosinophils. In neural tissue, one also frequently finds activated microglia and hypertrophic astrocytes.<sup>3-5</sup> The presence of necrosis, calcification, and hemorrhage often imparts a more ominous appearance.<sup>1</sup> Immunophenotyping studies have revealed the presence of vimentin in almost all the lesions, particularly among the spindle-cell components (99%). Many of these also react with smooth muscle actin (92%) and desmin (69%). CD68 has been expressed in about 24% of cases.<sup>2</sup>

Other extrapulmonary sites reported have included the mesentery and/or omentum, the gastrointestinal tract, the genitourinary tract, the upper respiratory tract, the pelvis, the retroperitoneum, soft tissue, trunk (including heart, mediastinum, breast, inguinal area), extremities, and head and neck.<sup>2</sup> The cause is unknown. While various bacterial infections have been implicated, most cases have had negative culture findings.<sup>4</sup> Findings for Epstein-Barr virus by in situ hybridization for a portion of the *EBER-1* gene was positive in 7 (41.2%) of 18 patients in a recent study.<sup>6</sup> The search for an origin is ongoing.

Accepted for publication June 4, 1999.

Reprints: Atilano Lacson, MD, Department of Pathology, All Children's Hospital, 801 Sixth St S, St Petersburg, FL 33701-8920.

## REFERENCES

1. Tang TT, Segura AD, Oechler HW, et al. Inflammatory myofibrohistiocytic proliferation simulating sarcoma in children. *Cancer*. 1990;65:1626-1634.
2. Coffin CM, Watterson J, Priest JR, Dehner LP. Extrapulmonary inflammatory myofibroblastic tumor (inflammatory pseudotumor): a clinicopathologic and immunohistochemical study of 84 cases. *Am J Surg Pathol*. 1995;19:859-872.
3. Tresser N, Rolf C, Cohen M. Plasma cell granulomas of the brain: pediatric case presentation and review of the literature. *Childs Nerv Syst*. 1996;12:52-57.
4. LeMarc'hadour F, Fransen P, Labat-Moleur F, et al. Intracranial plasma cell granuloma: a report of 4 cases. *Surg Neurol*. 1994;42:481-488.
5. Canella DM, Prezyna AP, Kapp JP. Primary intracranial plasma cell granuloma. *J Neurosurg*. 1988;69:785-788.
6. Arber AD, Kamel OW, van de Rijn M, et al. Frequent presence of the Epstein-Barr virus in inflammatory pseudotumor. *Hum Pathol*. 1995;26:1093-1098.