

Radiological Case of the Month

Patrick S. Ramsey, MD; Diana R. Danilenko, MD; Douglas P. Derleth, MD

A FEMALE INFANT weighed 870 g at birth and had Apgar scores of 7 and 8 at 1 and 5 minutes, respectively. She was born at 26 $\frac{2}{7}$ weeks' gestation to a mother with advanced malignant pleural mesothelioma.¹ A histologic evaluation of the products of conception revealed no evidence of malignancy. Immediately following delivery, the infant developed moderate stridor, grunting, and nasal flaring. She was intubated, received exogenous pulmonary surfactant, and was transferred to the neonatal intensive care unit.

From the Division of Maternal-Fetal Medicine, University of Alabama at Birmingham (Dr Ramsey); and the Divisions of Maternal-Fetal Medicine (Dr Danilenko) and Neonatology (Dr Derleth), Mayo Medical Center, Rochester, Minn.

Ventilator assistance was discontinued on day 7 and she was subsequently weaned from continuous positive airway pressure by day 23. Her hospital course remained uneventful until day 54 when edema, discoloration, and proptosis of the right eye were noted. Funduscopy demonstrated immature retinal vasculature and no papilledema or proliferative retinopathy. Computed tomography of the head revealed a soft tissue mass in the intracranial aspect of the right orbit with ascension of the mass posteriorly into the right cavernous sinus (**Figure 1**). Ultrasonography confirmed a homogeneous 2.1-cm solid mass in the right retro-orbital region. Doppler interrogation demonstrated prominent flow within the mass (**Figure 2**).

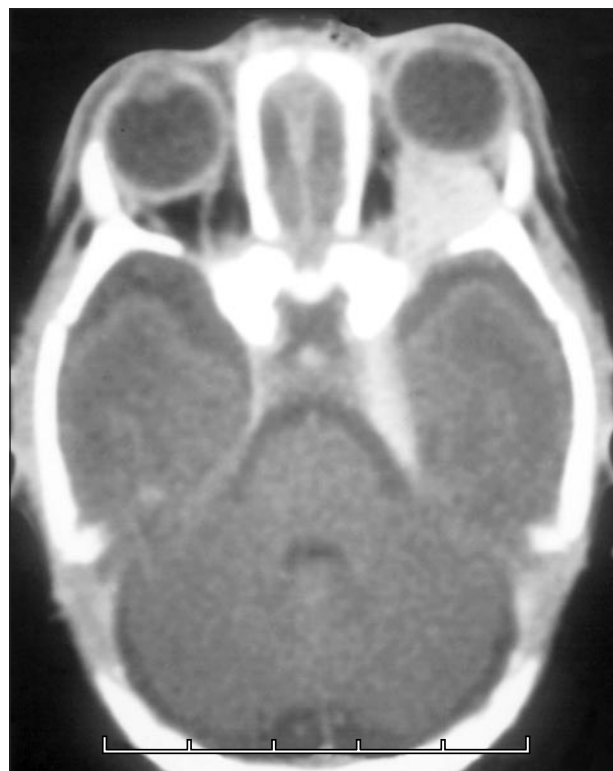

Figure 1.

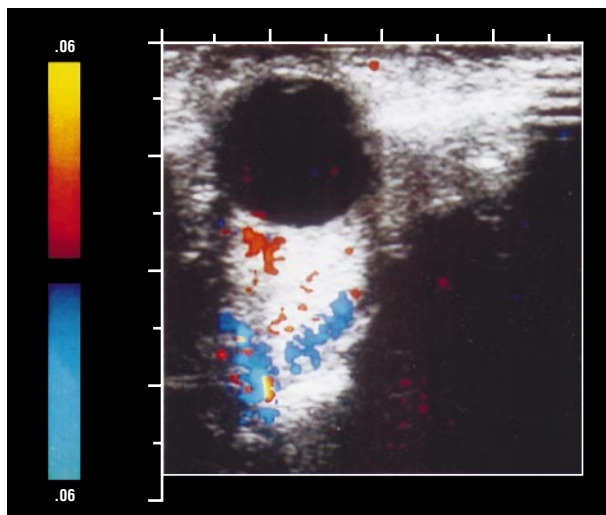


Figure 2.

Denouement and Discussion

Orbital Capillary Hemangioma

Figure 1. Computed tomographic scan of the head at age 54 days. A 2.1-cm soft tissue mass involves the intracoronary right orbit. The mass extends posteriorly into the right cavernous sinus.

Figure 2. Ultrasound with Doppler interrogation. A 2-cm retro-orbital mass is noted. Doppler flow interrogation demonstrates the highly vascular nature of the lesions.

Capillary hemangiomas are the most common benign orbital tumor of infancy.²⁻⁴ They are seen nearly twice as frequently in girls as in boys and occur more frequently in premature neonates.²⁻⁶ Capillary hemangiomas primarily involve the head and neck region, with approximately 90% demonstrating a visible cutaneous component (strawberry nevus).^{2,3} Deep orbital lesions comprise only 3% of all capillary hemangioma.^{2,3} They are typically situated in the upper lid or superior aspect of the orbit and often lack a cutaneous component. The most common presentation for orbital hemangioma is the development of proptosis and/or amblyopia.^{2,3}

Capillary hemangiomas are benign tumors composed of capillary endothelial cells. Fewer than 25% of lesions are present at birth, but rapid development is common in the first months of life.³ Rapid proliferation of these lesions can produce ulceration, bleeding, infection, necrosis, and compression of adjacent structures.⁷ Large lesions may result in thrombocytopenia secondary to intralesional platelet sequestration (Kasabach-Merritt syndrome).^{7,8} Most capillary hemangiomas resolve spontaneously. Typically, 50% of capillary hemangioma resolve spontaneously by age 5 years, 70% by age 7 years, 90% by age 9 years, and the rest by adolescence.^{2,3} The clinical course of capillary hemangioma is similar for lesions from various sites. Since spontaneous regression is the rule, treatment is only indicated if visual disturbance is present.^{4,7} Corticosteroids are the primary pharmacologic treatment used to control hemangiomas.^{4,9} Interferon is effective in refractory cases.⁴ Use of intralesional cryotherapy and sclerosing agents are of limited value. Radiation treatment is only considered for life-threatening lesions. Because orbital capillary hemangiomas are highly vascular lesions with the blood supply directly from the internal or external carotid artery, surgical intervention poses considerable risk for massive blood loss and is rarely indicated.

Other diagnostic considerations include an array of ocular and/or orbital tumors, including retinoblastoma, intraocular malignancy, solid rhabdomyosarcoma, dermoid cyst, teratoma, lymphangioma, glioma,

neurofibroma, and meningioma.⁷ Another consideration is the possibility of transplacental metastasis of maternal malignancy. Metastasis of malignancy to products of conception is rare. Fewer than 100 cases of malignant metastasis to products of conception have been reported, to our knowledge; malignant melanoma is the most common of these, accounting for nearly 30%. Leukemia, lymphoma, and breast adenocarcinoma combined account for an additional 30%.¹⁰ Metastasis to the fetus occurs in only 27% of these cases in which products of conception are involved. Eighty percent of the cases are associated with malignant melanoma or hematopoietic malignancies.¹⁰ No cases of mesothelioma metastatic to products of conception have been reported to our knowledge.

In light of the clinical presentation, the well-circumscribed nature of the lesion, and the prominent vascular supply, a diagnosis of orbital capillary hemangioma was made. Because of progressive ocular manifestations, prednisone was administered, and follow-up imaging studies demonstrated no further progression of size. The infant did well and was discharged on the 70th day of life.

Accepted for publication August 21, 1999.

Reprints: Patrick S. Ramsey, MD, Division of Maternal-Fetal Medicine, Department of Obstetrics/Gynecology, University of Alabama at Birmingham, 618 19th Street S, Birmingham, AL 35249 (e-mail: ramsey-patrick@hotmail.com).

REFERENCES

1. Ramsey PS, Danilenko-Dixon DR, Ramin KD, Ogburn PL Jr. Malignant pleural mesothelioma in pregnancy. *J Matern Fetal Med.* 2000;9:373-375.
2. Esterly NB. Hemangiomas in infants and children: clinical observations. *Pediatr Dermatol.* 1992;9:353-355.
3. Haik BG, Jakobiec FA, Ellsworth RM, Jones IS. Capillary hemangioma of the lids and orbit: an analysis of the clinical features and therapeutic results in 101 cases. *Ophthalmology.* 1979;86:760-792.
4. Ezekowitz RAB, Mulliken JB, Folkman J. Interferon alfa-2a therapy for life-threatening hemangiomas of infancy. *N Engl J Med.* 1992;326:1456-1463.
5. Holmdahl K. Cutaneous hemangiomas in premature and mature infants. *Acta Paediatr Scand.* 1955;44:370-379.
6. Amir J, Metzker A, Krikler R, Reisner SH. Strawberry hemangioma in preterm infants. *Pediatr Dermatol.* 1986;3:331-332.
7. Nicholson DH, Green WR. Ocular tumors in children. In: Nelson LB, Calhoun JH, Harley RD, eds. *Pediatric Ophthalmology.* 3rd ed. Philadelphia, Pa: WB Saunders Co; 1991:382-426.
8. Kasabach HH, Merritt KK. Capillary hemangioma with extensive purpura: report of a case. *AJDC.* 1940;59:1063-1070.
9. Hiles DA, Pilchard WA. Corticosteroid control of neonatal hemangiomas of the orbit and ocular adnexa. *Am J Ophthalmol.* 1971;71:1003-1008.
10. Read EJ, Platzer PB. Placental metastasis from maternal carcinoma of the lung. *Obstet Gynecol.* 1981;38:387-391.