

SECTION EDITOR: ENID GILBERT-BARNES, MD

## Pathological Case of the Month

Joseph Rose, MD; Bejan Iranpour, DDS; Walter Markowitch, MD; Vernon Loveless, DMD; Paul F. Lehoullier, MD, PhD

**A** 10-MONTH-OLD girl was evaluated for facial swelling lasting for 3 days over the left premaxilla-nasal area. There was no history of trauma, nasal discharge, or fever. On physical examination a 3-cm mass in the left nasomaxillary area was evident. On palpation the mass was firm, fixed, nontender, and extended toward the malar eminence. Intraorally, the mass obliterated the left maxillary vestibule from the midline to the molar region; palatal displacement by the mass was noted. A facial computed tomographic scan showed a large

From the Medicine-Pediatrics Residency Program, Strong Memorial Hospital (Dr Rose); the Departments of Oral Maxillofacial Surgery (Dr Iranpour) and Pathology (Dr Markowitch), The Genesee Hospital; the Department of Oral Surgery (Dr Loveless), and Rochester General Pediatric Associates (Dr Lehoullier), Rochester General Hospital, Rochester, NY.

19 × 21-mm round/ovoid lucency in the anterior maxilla. The margins of the lesion included the left alveolar ridge to just under the orbital floor. The sinuses were intact. Focal bony destruction of the maxilla over the anterior portion of the mass and perforation of the nasal floor was noted. Multiple developing teeth were engulfed by the lesion (**Figure 1**). Several days later, she underwent surgical exploration, frozen section biopsy, and possible enucleation of the left maxillary mass. An intraoral approach through the left maxillary alveolar crest revealed a large multilocular mesenchymatous tissue mass (**Figure 2**); aggressive excision and curettage was performed. All unerupted teeth engulfed in the mass were removed. Her postoperative course was uneventful, and she was discharged 2 days later. The excised specimen consisted of 3 pieces of soft, pale, yellow-gray tissue, the largest of which was 1.5 × 1.2 × 1.1 cm (**Figure 3** and **Figure 4**).

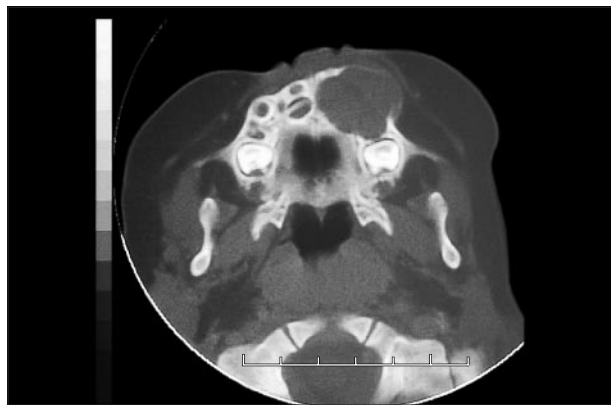


Figure 1.

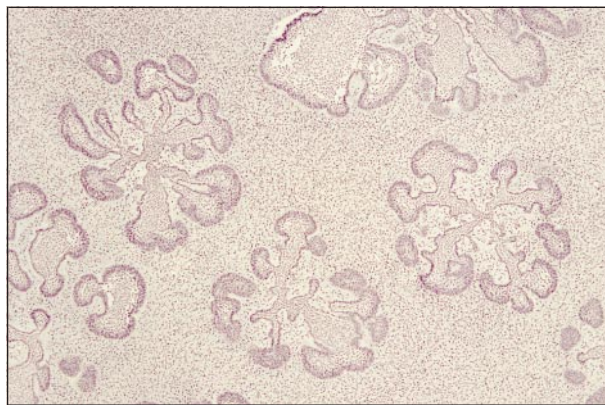


Figure 3.

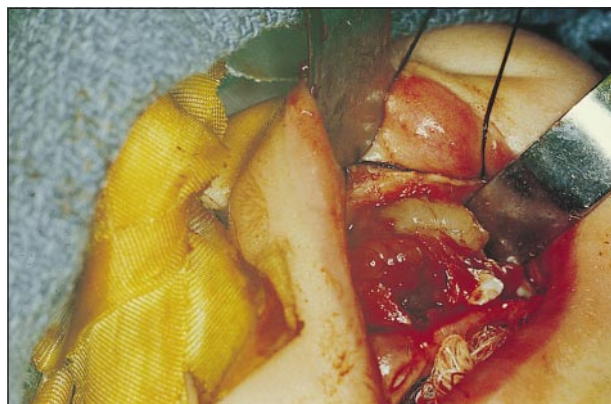

Figure 2.

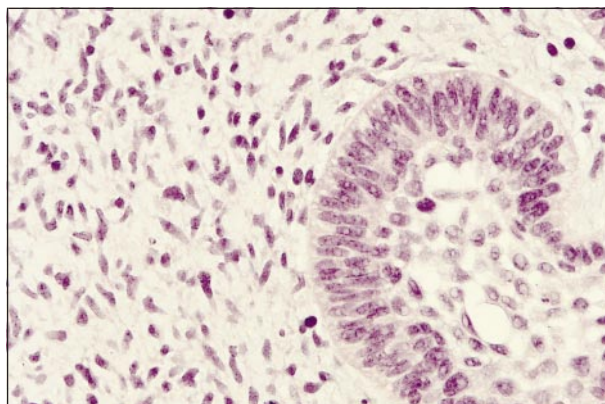


Figure 4.

# Diagnosis and Discussion

## Ameloblastic Fibroma of the Maxilla

**Figure 1.** Expansile mass in the left maxilla, loss of the lateral wall of the maxilla, and extension of the mass into the palatine bone. Most of the developing teeth on the left side are not depicted.

**Figure 2.** Grayish, loose, friable tissue extending from the anterior to the left maxillary tuberosity area.

**Figure 3.** Islands of odontogenic epithelium in cellular mesenchymal stroma (hematoxylin-eosin, original magnification  $\times 40$ ).

**Figure 4.** Peripheral columnar cells and central loosely arranged epithelial cells in islands of odontogenic epithelium. Cellular mesenchyme resembles developing dental papilla (hematoxylin-eosin, original magnification  $\times 200$ ).

**H**istopathologically, the excised neoplasm was composed of islands of odontogenic epithelium, resembling developing enamel organ with peripheral columnar cells and central loosely arranged epithelial cells, and cellular mesenchymal tissue with stellate and spindle-shaped cells resembling developing dental papilla. The mitotic count was low.

Ameloblastic fibroma (AF) is a benign tumor of odontogenic origin. It is composed of proliferative odontogenic epithelium and mesenchymal tissue resembling primitive dental papilla. Comprising approximately 2.5% of odontogenic tumors, AF was first described by Kruse et al<sup>1</sup> in 1891. It is more common in children than adults; the average age of onset is 15 years (range, 7 weeks to 42 years).<sup>1-3</sup> There is no apparent predilection for race or sex.<sup>2,4</sup> The most common clinical presentation is painless facial swelling, although delayed tooth eruption and gingival cysts have been reported as well.<sup>4-6</sup> Radiographically, the lesion appears as unilocular or multilocular radiolucencies. Expansion of the cortex is occasionally seen, and involvement with unerupted teeth is common. The lesions are primarily intraosseous ranging in size from 0.5 to 8.5 cm with 80% to 90% of lesions occurring in the mandible.<sup>1,4</sup> The clinical differential diagnosis, which requires histopathologic studies, includes neuroectodermal tumor of infancy, ameloblastoma, odontogenic or developmental cyst, ameloblastic fibrosarcoma, and osteogenic sarcoma.

The need for precise histologic diagnosis of AF is uniformly agreed on throughout the literature.<sup>6-8</sup> It is histologically similar to 2 other tumors of odontogenic origin: the ameloblastoma and the ameloblastic fibrosarcoma. As of July 1990, Girdler and Edwards<sup>2</sup> found only 98 reported cases of AF in the English-language literature. In 1998, Mosby et al<sup>1</sup> found only 4 reports of anterior maxillary AF, and they subsequently reported a fifth. Although AF is considered benign, there is still debate over how aggressive one should be in its removal because AF has an 18.3% incidence of recurrence (14 of 82 cases) when treated with simple enucleation and cu-

rettage alone.<sup>1</sup> Also, it has been found that 44% of the time, ameloblastic fibrosarcoma develops its origins within AF.<sup>9</sup> Given the rarity of these tumors, there is limited data regarding the outcome of various surgical approaches. Some have recommended wide local excision as the initial approach,<sup>9</sup> while others have concluded that this results in serious disfigurement with unproven long-term benefit.<sup>1</sup> In this case, aggressive curettage instead of block resection was performed mainly because of the close proximity of the posterior margin of the tumor to the base of the skull.

Long-term, possibly lifelong, monitoring to detect any recurrence of the tumor will be required for this patient, including clinical and radiographic follow-up every 6 months. Ultimately, bone grafting of the maxillary deformity will be carried out in sequential steps, depending on the growth outcome of the facial bones. The missing teeth will be replaced with implants. Additional surgical intervention in the case of tumor recurrence would include curettage or block resection. Ameloblastic fibroma is not responsive to radiation or chemotherapy. This case constitutes the sixth reported case to our knowledge.

Accepted for publication September 15, 1999.

We thank John R. Kalmar, DMD, PhD, for his assistance in the histopathologic diagnosis.

Reprints: Paul F. Lehoullier, MD, PhD, Rochester General Pediatric Associates, Rochester General Hospital, 1425 Portland Ave, Rochester, NY 14621.

## REFERENCES

1. Mosby EL, Russell D, Noren S, Barker BF. Ameloblastic fibroma in a 7-week-old infant: a case report and review of the literature. *J Oral Maxillofac Surg.* 1998; 56:368-372.
2. Girdler NM, Edwards DM. Ameloblastic fibroma: an unusual case of facial swelling in a young child. *Br Dent J.* 1990;169:57-58.
3. Sapp JP. Intraosseous lesions of the maxilla and mandible. In: Sanders B, ed. *Pediatric Oral and Maxillofacial Surgery.* St Louis, Mo: CV Mosby Co; 1979:307-308.
4. Meyers A, Poulson T, Pettigrew J, Clark M. Cystic ameloblastic fibroma. *Ear Nose Throat J.* 1991;70:729-732.
5. Kusama K, Miyake M, Moro I. Peripheral ameloblastic fibroma of the mandible: report of a case. *J Oral Maxillofac Surg.* 1998;56:399-401.
6. Baroni C, Farneti M, Stea S, Rimondini L. Ameloblastic fibroma and impacted mandibular first molar. *Oral Surg Oral Med Oral Pathol.* 1992;73:548-549.
7. Carrillo R, Cuesta C, Rodriguez-Peralto JL, Matin J. Ameloblastic fibroma: report of a case with fine needle aspiration cytologic findings. *Acta Cytol.* 1992; 36:537-540.
8. Nogueira TO, Carvalho YR, Rosa LEB, Santos LM. Possible malignant transformation of an ameloblastic fibroma to ameloblastic fibrosarcoma: a case report. *J Oral Maxillofac Surg.* 1997;55:180-182.
9. Muller S, Parker DC, Kapadia SB, et al. Ameloblastic fibrosarcoma of the jaws: a clinicopathologic and dna analysis of five cases and review of the literature with discussion of its relationship to ameloblastic fibroma. *Oral Surg Oral Med Oral Pathol.* 1995;79:467-477.