

## Radiological Case of the Month

John G. Walsh, MB, MRCPCH; Martin J. O'Sullivan, MB, FRCI; C. Anthony Ryan, MB, MRCPCH

**A**N INFANT weighing 1530 g and born at 31 weeks' gestation by emergency caesarean delivery was intubated in the delivery room because of respiratory distress. Endotracheal surfactant was administered, and she was transferred to the neonatal intensive care unit. Within an hour, high-frequency oscillation ventilation was started because of difficulty maintaining oxygenation with conventional ventilation. A double-lumen 3F catheter was inserted into an umbilical vein. The baby's clinical condition improved rapidly over the next 2 days, and she was extubated and maintained on continuous positive airway pressure. At age 4 days, she was breathing room air spontaneously.

From the Departments of Paediatrics and Child Health (Drs Walsh and Ryan) and Surgery (Dr O'Sullivan), Cork University Hospital, Cork, Ireland.

On day 5, her abdomen was distended, and she developed respiratory distress and was intubated. The umbilical venous catheter (UVC) was removed because of clinical suspicion of necrotizing enterocolitis. A radiograph of the abdomen was obtained (**Figure 1**). An ultrasound examination of the abdomen showed echolucency in both flanks indicating free fluid. The kidneys were not identified, but the liver and spleen were normal. Pigtail catheters (4F) were inserted by ultrasound guidance into the flank regions bilaterally. Ninety milliliters of opalescent, blood-stained fluid was aspirated, 50 mL from the right flank and 40 mL from the left flank. Contrast medium was injected via the catheters (**Figure 2**). Ultrasound following this procedure showed normal kidneys. A laparotomy was performed and showed no necrotizing enterocolitis, perforated viscus, or any other intraperitoneal abnormality. The infant recovered, and findings from ultrasound examination of the abdomen prior to discharge on day 53 was normal.

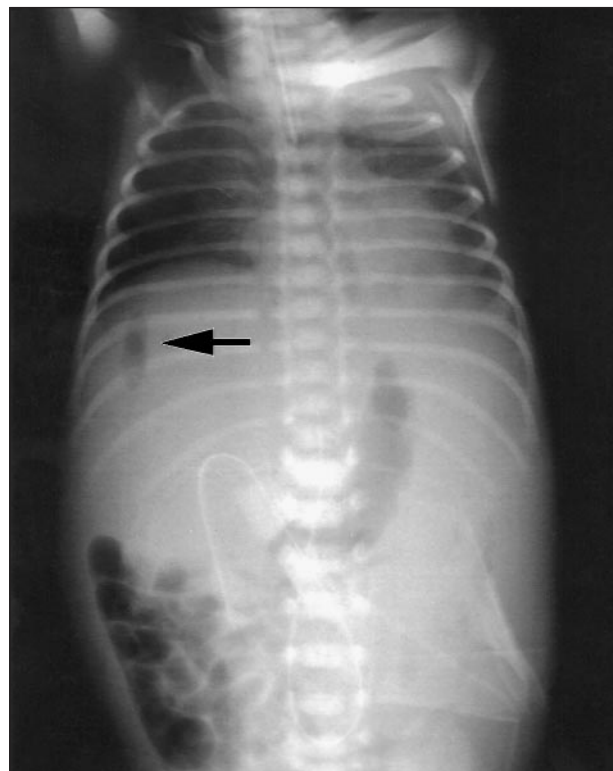


Figure 1.

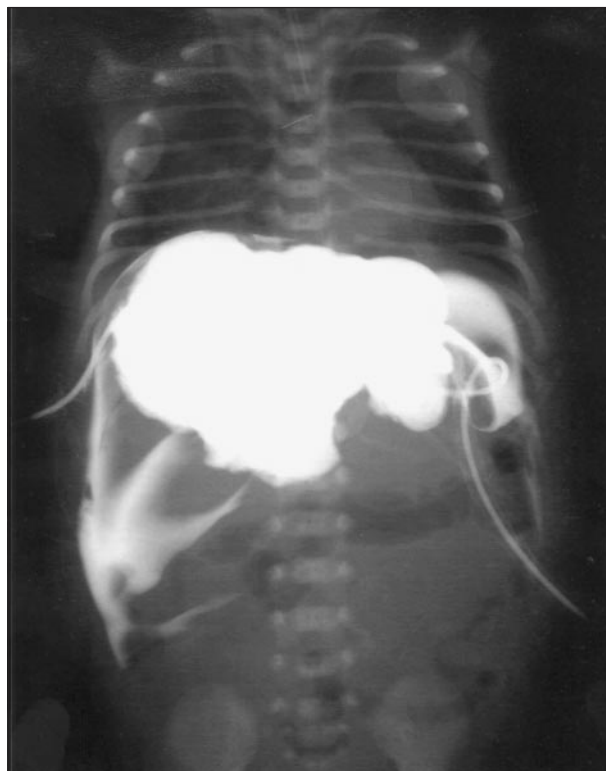

Figure 2.

# Denouement and Discussion

## Perforation of the Inferior Cava As a Cause of Neonatal Free Intra-Abdominal Air

**Figure 1.** Radiograph of the abdomen showing free air around the liver.

**Figure 2.** Contrast media in the retroperitoneal space inserted via draining catheters.

**F**ree intra-abdominal air on radiography is an ominous sign, usually indicating perforation of a viscus. In the premature neonate, the cause is usually necrotizing enterocolitis.<sup>1,2</sup> The term “free air” usually refers to air within the peritoneal cavity, but in this case, the air was in the retroperitoneal space along with extravasated parenteral nutrition fluid. Apparently, the UVC eroded the wall of the inferior vena cava, resulting in extravasation of total parenteral nutrition (TPN) fluid. The origin of free air was either direct catheter air embolus or represented accumulation of microbubbles from the TPN fluid. Biochemical analysis of the fluid aspirated confirmed it as lipid-containing TPN fluid.

A total of 700 mL of crystalloid and TPN was infused through the UVC during the 5-day period from its insertion to its removal. If the vena caval perforation occurred at the time of insertion of the UVC, a larger volume of fluid would have been expected on paracentesis. Therefore, there was likely gradual erosion of the vena cava wall after insertion of the UVC.

Complications previously recognized with UVC insertion include thrombosis, embolism, vasospasm, vessel perforation, hemorrhage, infection intestinal, and renal and limb damage.<sup>3</sup> Small air emboli have been described following insertion of peripheral or central venous catheters.<sup>4,5</sup> This report highlights an unusual hazard of umbilical vessel catheterization and a radiological sign: vena cava erosion and perforation with accumulation of retroperitoneal gas. To our knowledge,

this cause of radiologically diagnosed free intra-abdominal air in a neonate has not previously been described.

Accepted for publication May 10, 2000.

Reprints: C. Anthony Ryan, MD, MRCPCH, Neonatal Intensive Care Unit, Erinville Hospital, Western Road, Cork, Ireland (e-mail: cryan@indigo.ie).

### REFERENCES

1. Pokorny WJ, Garcia-Prats JA, Barry YN. Necrotizing enterocolitis: incidence, operative care and outcome. *J Pediatr Surg.* 1986;21:1149-1154.
2. Harms K, Ludtke FE, Lepsien G, et al. Idiopathic intestinal perforations in premature infants without evidence of NEC. *Eur J Pediatr Surg.* 1995;5:30-33.
3. Green C, Yohannan MD. Umbilical arterial and venous catheters: placement, use and complications. *Neonatal Netw.* 1998;17:23-28.
4. Groell R, Schaffler GJ, Rienmuller R. The peripheral intravenous cannula: a cause of venous air embolism. *Am J Med Sci.* 1997;314:300-302.
5. Waggoner SE. Venous air embolism through a Groshong catheter. *Gynecol Oncol.* 1993;48:394-396.

### New Feature: Clinical Problem Solving

The Editor is seeking submissions for a new feature, *Clinical Problem Solving*, which will combine *Picture of the Month*, *Radiological Case of the Month*, and *Pathological Case of the Month*. Our aim is to demonstrate the thinking process of a master clinician involved in approaching a patient with an unknown disease. The discussion of such cases should place the clinician's expertise into the context of the prevailing medical literature on the topic. Manuscripts should be between 3000 and 4000 words and may include photographs and radiographs.