

## Pathological Case of the Month

Gregg T. Lueder, MD; Richard Grosten, MD; Morton Smith, MD

**T**HE RIGHT eye of an otherwise healthy 6-year-old girl was red for several months without pain. She had neither a history of ocular trauma nor family history of iritis, glaucoma, or ocular tumors. On examination, visual acuity was 20/50 OD and 20/20 OS. Intraocular pressure was 44 mm Hg OD (reference, <20 mm Hg). The conjunctiva was diffusely hyperemic. The patient had circulating cells in the anterior chamber and layered cells inferiorly (**Figure 1**). Computed tomogra-

phy revealed calcification in the retina. Results of a serum *Toxocara canis* titer were 1:16. Examination under anesthesia revealed flaky and noncohesive white cells in the anterior chamber. In the recumbent position, the cells dispersed onto the anterior lens capsule and zonules. A large, white, elevated lesion was present in the peripheral retina with 2 creamy, elevated retinal nodules posteriorly (**Figure 2**). The right eye was enucleated and examined (**Figure 3** and **Figure 4**).

From the Departments of Ophthalmology and Visual Sciences (Drs Lueder and Smith), Pediatrics (Dr Lueder), and Pathology (Dr Smith), Washington University Medical Center and St Louis Children's Hospital, St Louis, Mo; and the Department of Ophthalmology and Visual Sciences (Drs Grosten and Smith), University of Wisconsin Medical School, Madison.

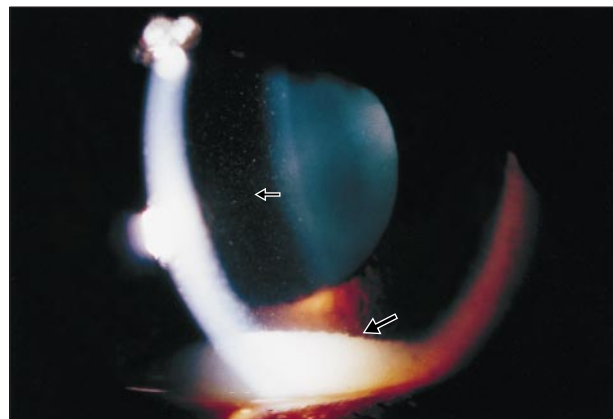


Figure 1.

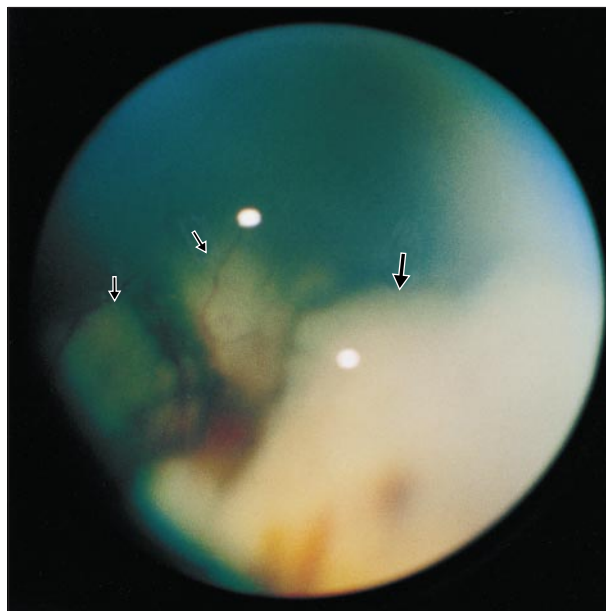


Figure 2.

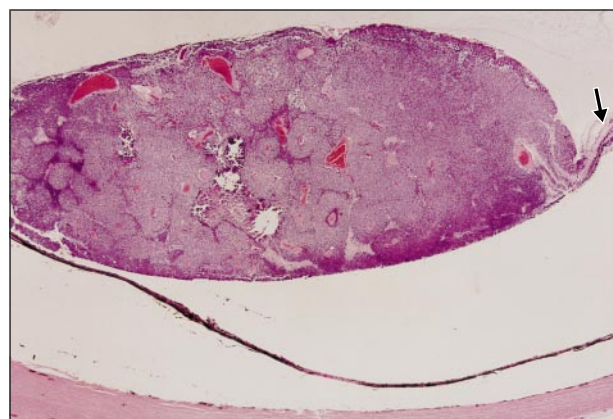


Figure 3.

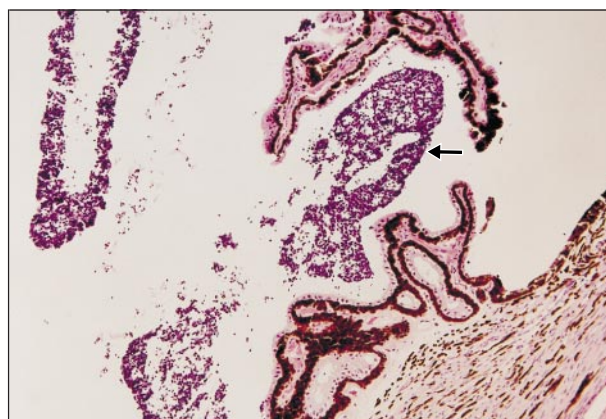


Figure 4.

# Diagnosis and Discussion

## Retinoblastoma Presenting as Pseudiritis and Secondary Glaucoma

**Figure 1.** Layered tumor cells in the inferior angle (large arrow) and individual circulating cells in the anterior chamber (small arrow).

**Figure 2.** Note the large white mass in the inferonasal retina (large arrow) and 2 creamy, slightly elevated subretinal lesions posteriorly (small arrows).

**Figure 3.** Retinoblastoma cells (center) arise adjacent to normal retinal cells (arrow). Areas of necrosis and calcification are present (hematoxylin-eosin, original magnification  $\times 20$ ).

**Figure 4.** Aggregates of retinoblastoma cells (arrow) are present between the ciliary processes (hematoxylin-eosin, original magnification  $\times 40$ ).

**R**etinoblastoma is the most common intraocular tumor in children but is, nevertheless, rare with an incidence of approximately 1:20 000 live births. It usually is seen in the first 1 to 2 years of life. Most pediatricians are familiar with the presentation of retinoblastoma in early childhood. The most common and most striking sign is leukocoria—a white pupillary reflex that results from light reflecting off of the surface of the tumor. The second most common sign is strabismus. This may develop if the tumor is large enough to cause decreased vision, in which case a sensory esotropia or exotropia can develop.

Retinoblastoma is much less common in older children. In a large series, fewer than 10% of patients were aged 5 years or older at the time of diagnosis.<sup>1</sup> The presenting signs and symptoms of retinoblastoma are distinctly different in this older group. Most importantly, children at this age are able to verbally describe symptoms, while younger children cannot. Decreased vision, eye pain, and floaters may be self-reported in affected patients.

Retinoblastoma may rarely present as a pseudiritis, and this presentation is most common in older children.<sup>2-4</sup> In this condition, tumor cells break free from the main tumor mass in the retina and migrate into the anterior chamber. Cells may be seen circulating in the aqueous humor on slitlamp examination, producing a clinical picture similar to iritis. The cells may also deposit in the inferior anterior chamber angle and resemble a hypopyon. In pseudiritis, glaucoma may occur if the tumor cells obstruct the outflow of aqueous humor by clogging the trabecular meshwork.

The histopathological appearance of retinoblastoma is one of abnormal cells with hyperchromatic nuclei and little cytoplasm arising from the retina (Figure 3). Areas of necrosis and calcification are common. In more differentiated tumors, primitive photoreceptors may organize into Flexner-Wintersteiner rosettes. The tumor in this patient grew in an endophytic pattern (toward the vitreous), and the pseudiritis resulted from the presence of tumor cells that migrated to the ciliary body and anterior chamber (Figure 4). There was no histopathological evidence of extraocular extension of the tumor.

The differential diagnosis for an elevated white retinal lesion with inflammation (or pseudoinflammation) in an older child includes *T canis* retinitis, occult retinal foreign body, bacterial endophthalmitis, intermediate uveitis, retinoblastoma, and other inflammatory and infectious disorders. The clinical features that helped establish the diagnosis of retinoblastoma in this patient were the absence of other inflammatory signs (ie, no cataract, iris adhesions, or vitreous inflammation), the flaky and easily dispersed nature of the anterior chamber tumor cells, and the clinical and radiological appearance of the retinal lesions.

The prognosis for a large retinoblastoma is excellent if the eye is removed before the tumor spreads. If extraocular extension occurs, either by direct extension or metastases, the tumor mortality is high. Early recognition and treatment of this potentially lethal tumor is important to minimize the risk of extraocular disease.

Accepted for publication July 7, 2000.

Corresponding author and reprints: Gregg T. Lueder, MD, Department of Ophthalmology and Visual Sciences, Washington University Medical Center, Box 8096, 660 S Euclid Ave, St Louis, MO 63110 (e-mail: lueder@vision.wustl.edu).

### REFERENCES

1. Shields CL, Shields JA, Shah P. Retinoblastoma in older children. *Ophthalmology*. 1991;98:395-399.
2. Foster BS, Mukai S. Intraocular retinoblastoma presenting as ocular and orbital inflammation. *Int Ophthalmol Clin*. 1996;36:153-160.
3. Richards WW. Retinoblastoma simulating uveitis. *Am J Ophthalmol*. 1968;65:427-431.
4. Stafford WR, Yanoff M, Parnell BL. Retinoblastoma initially misdiagnosed as primary ocular inflammations. *Arch Ophthalmol*. 1969;82:771-773.