

SECTION EDITOR: BEVERLY P. WOOD, MD

Radiological Case of the Month

Phyllis R. Bishop, MD; Michael J. Nowicki, MD; Paul H. Parker, MD

A 3-YEAR-OLD boy was referred to the pediatric gastroenterology department for evaluation of abdominal pain and vomiting. The patient had a 1-year history of recurrent, acute, episodic abdominal pain that was often associated with vomiting. The episodes occurred infrequently and typically lasted for 48 to 72 hours. There was no nocturnal awakening with abdominal pain or emesis. There was no associated fever, diarrhea, rash, headache, or altered consciousness. The child has main-

From the Department of Pediatrics, Division of Pediatric Gastroenterology and Nutrition, Blair E. Batson Children's Hospital, University of Mississippi Medical Center, Jackson.

tained growth at the 25th percentile both for height and weight.

Findings from physical examination were normal except for the abdomen. Mild abdominal distension was present with a sense of fullness to palpation, but no mass was felt. There was no tenderness to deep palpation. Results of rectal examination were normal, and a stool sample was guaiac negative. The following laboratory studies were performed and revealed normal results: complete blood cell count, erythrocyte sedimentation rate, amylase, lipase, urinalysis, and urine culture. An abdominal computed tomographic scan was obtained (**Figure 1**). Surgery was performed, and a large cystic mass was removed (**Figure 2**).

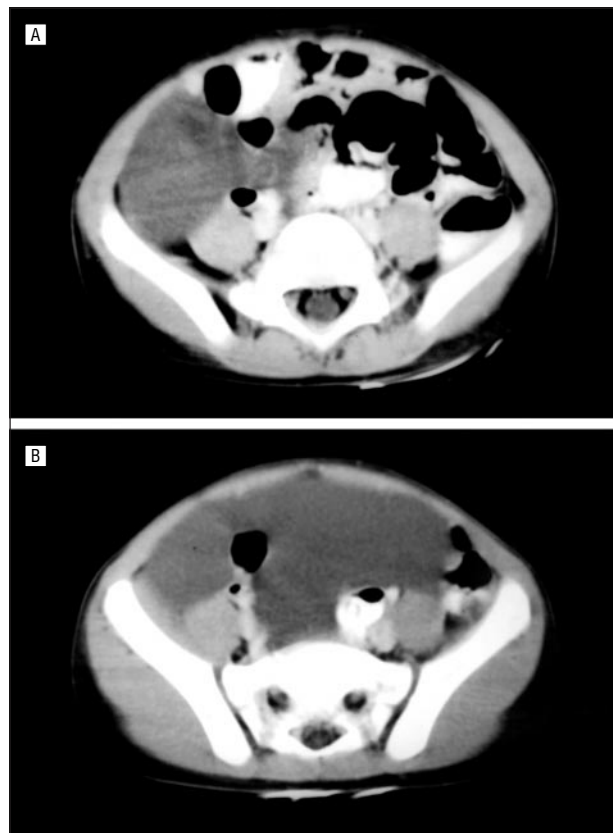


Figure 1.

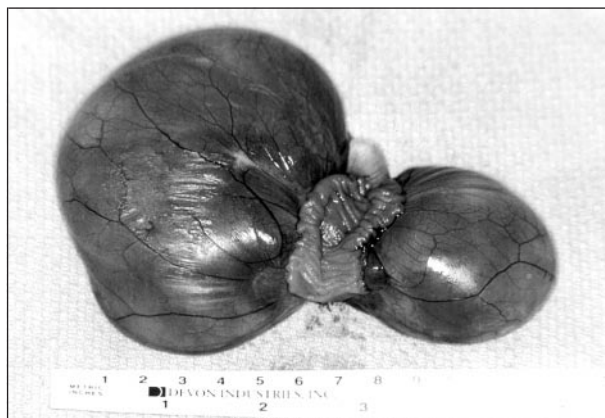


Figure 2.

Denouement and Discussion

Mesenteric Cyst

Figure 1. An abdominal computed tomographic scan revealed a large cystic mass displacing the bowel superiorly.

Figure 2. Surgically resected specimen revealing a thin-walled, bilobed cyst containing clear amber fluid.

Based on the findings of the abdominal computed tomographic scan, surgery was planned. A large, bilobed mesenteric cyst was found, involving the ileum. The cyst was removed, and segmental intestinal resection with primary anastomosis was necessary. The pathologist identified the cyst as a cystic lymphangioma of the mesentery.

Mesenteric cysts are rare, benign, intra-abdominal tumors, and fewer than 1000 cases are reported since Benevieni's original description in 1505.^{1,2} One third of reported cases involve children younger than age 10 years.^{3,4} The incidence of mesenteric cysts in children ranges from 1 per 11 250 to 1 per 34 000 hospitalizations.^{2,5} Most are considered congenital in origin. Proposed mechanisms of development include sequestration or obstruction of lymphatic vessels and ectopic lymphatic tissue.⁶⁻⁸ Mesenteric cysts may arise from trauma, infection, or neoplasm.⁶ They are grouped with omental and retroperitoneal cysts because of a common origin and histologic features.⁹

Mesenteric cysts are described in the mesentery from the duodenum to the rectum; however, half are found in the small intestine mesentery, usually near the ileum.^{2,4,5,9} The patterns of presentation include specific abdominal signs and the incidental finding of an abdominal mass.¹⁰ Presentation relates to size, location, and associated complications. Most children with mesenteric cysts are symptomatic; only 20% of mesenteric cysts in children are asymptomatic.² A palpable mass is found on physical examination in 30% to 50% of affected children.^{2,3,9,11} Occasionally, these patients are surgical emergencies, particularly when there is intestinal obstruction or appendicitis.^{9,12} Other presentations include acute abdomen due to hemorrhage, rupture, or torsion of the cyst, which may predispose to volvulus with resultant intestinal infarction.^{13,14}

Diagnosis is not made by history, clinical features, or findings from laboratory examination; radiological evaluation is necessary. Findings from abdominal radiographs are normal or show bowel displacement by the mass. Sometimes calcifications are seen in the cyst wall. The more useful modalities that demonstrate the cystic

nature of the mass are abdominal ultrasound or computed tomographic scan.¹⁰

The treatment of choice for mesenteric cysts is complete surgical excision. In 33% to 60% of children with mesenteric cysts, segmental bowel resection is required to fully excise the cyst.^{2,3,5} Although the greatest experience is with open surgery, laparoscopic surgery has been used.^{15,16} Marsupialization is performed in approximately 10% of the cases.^{2,5} Neither partial resection nor cyst aspiration is adequate treatment, and both result in a high recurrence rate, while patients with total excision have a negligible risk of recurrence.

Accepted for publication February 24, 1999.

Reprints: Phyllis R. Bishop, MD, Department of Pediatrics, Division of Pediatric Gastroenterology and Nutrition, Blair E. Batson Children's Hospital, University of Mississippi Medical Center, Jackson, MS 39216.

REFERENCES

1. Swartley WR. Mesenteric cysts. *Ann Surg.* 1997;85:886-896.
2. Egozi EI, Ricketts RR. Mesenteric and omental cysts in children. *Am Surg.* 1997; 63:287-290.
3. Bliss DP, Coffin CM, Bower R J, Stockman PT, Ternberg JL. Mesenteric cysts in children. *Surgery.* 1994;115:571-577.
4. Burnett WE, Rosemond GP, Bucher RM. Mesenteric cysts: report of three cases, in one of which a calcified cyst was present. *Arch Surg.* 1950;60:699-706.
5. Kurtz R J, Heimann TM, Beck AR, Holt J. Mesenteric and retroperitoneal cysts. *Ann Surg.* 1986;203:109-112.
6. Beahrs OM, Judd ES Jr, Dockerty MD. Chylous cysts of the abdomen. *Surg Clin North Am.* 1950;30:1081-1096.
7. Gross RE. *The Surgery of Infancy and Childhood: Its Principles and Techniques.* Philadelphia, PA: WB Saunders Co; 1956:377-383.
8. Hardin WJ, Hardy JD. Mesenteric cysts. *Am J Surg.* 1970;119:640-645.
9. Okur H, Küçükaydin M, Özokutan BH, Durak AC, Kazez A, Köse O. Mesenteric, omental, and retroperitoneal cysts in children. *Eur J Surg.* 1997;163:673-677.
10. Liew SCC, Glenn DC, Storey DW. Mesenteric cyst. *Aust N Z J Surg.* 1994;64: 741-744.
11. Chung MA, Brandt ML, St-Vii D, Yazbeck S. Mesenteric cysts in children. *J Pediatr Surg.* 1991;26:1306-1308.
12. Hadley MN. The origin of retroperitoneal cystic tumors. *Surg Gynecol Obstet.* 1916; 22:174-176.
13. Namasivayam J, Ziervogel MA, Hollman AS. Case report: volvulus of a mesenteric cyst: an unusual complication diagnosed by CT. *Clin Radiol.* 1992;46:211-212.
14. Wong SW, Gardner V. Sudden death in children due to mesenteric defect and mesenteric cyst. *Am J Forensic Med Pathol.* 1992;13:214-216.
15. Shimura H, Ueda J, Ogawa Y, Ichimiya H, Tanaka M. Total excision of mesenteric cysts by laparoscopic surgery: report of two cases. *Surg Laparosc Endosc.* 1997;7:173-176.
16. Brentano L, Faccini P, de Castro Oderich GS. Laparoscopic resection of a mesenteric cyst. *Surg Laparosc Endosc.* 1998;8:402-403.