SPECIAL FEATURE

Pathological Case of the Month

Bina S. Menon, MRCP; Wan Maziah, WM, MMed; Mutum Samarendra, MDPath; Ahmad Toha, MMed

A 10-YEAR-OLD Malaysian girl was seen for a 7-month history of multiple swellings over the left thigh, upper arm, and anterior chest. Traditional healers had been consulted; however, the swellings continued to increase in size and to ulcerate. There was loss of weight and loss of appetite. On examination, 3 masses were noted measuring 7 × 4 cm over the left thigh, 4 × 5 cm on the left arm (**Figure 1**), and 5 × 3 cm over the chest wall. There were shotty cervical and inguinal lymph nodes palpable. Findings from general examination were otherwise unremarkable. Computed tomographic (CT) scans of the chest and abdomen were normal. The CT scan of the upper limbs is shown in **Figure 2**. The complete blood cell count showed a hemoglobin level of 127 g/L; white blood cell count, 30.9×10^9/L; and platelets, 563×10^9/L. There was a predominant neutrophilia. Results of renal and liver function tests were normal. The chest and thigh masses were debulked at surgery and the specimens sent for histopathological examination (**Figure 3** and **Figure 4**).

From the Departments of Paediatrics (Drs Menon and Maziah), Pathology (Dr Samarendra), School of Medical Sciences, Universiti Sains Malaysia, and General Hospital Kota Bharu (Dr Toha), Kelantan, Malaysia.

Figure 1.

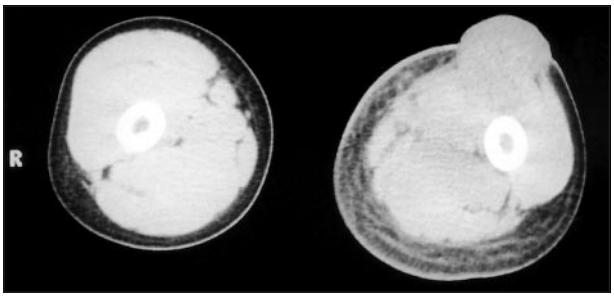

Figure 2.

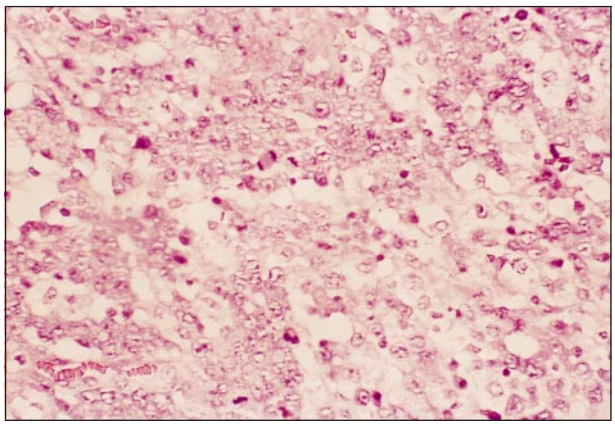

Figure 3.

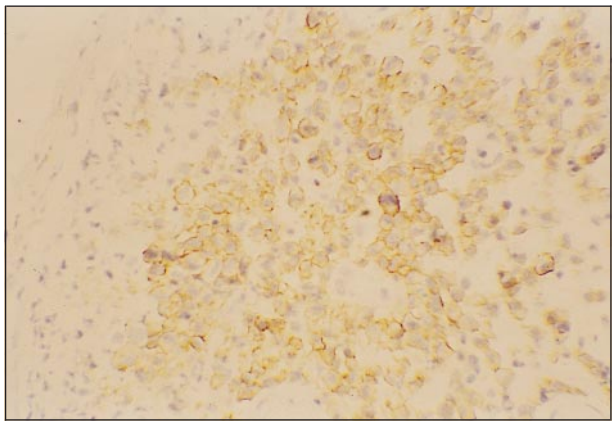

Figure 4.

©2001 American Medical Association. All rights reserved.
Downloaded From: http://archpedi.jamanetwork.com/ on 04/27/2017

Denouement and Discussion

Ki-1–Positive Anaplastic Large Cell Lymphoma Involving Muscle

Figure 1. *Swelling with overlying erythema on the anterior aspect of the left upper arm.*

Figure 2. *Computed tomographic scan of the upper limbs showing a tumor arising from the left biceps muscle.*

Figure 3. *Cohesive sheets of large pleomorphic cells displaying vesicular nuclei with peripheral condensation of chromatin are seen in the dermis. Some have prominent irregular nucleoli and amphophilic or vacuolated abundant cytoplasm. Several mitotic figures are also noted (hematoxylin-eosin, original magnification ×400).*

Figure 4. *Lymphoma cells display strong staining of cell membranes for Ki-1 antigen CD30 (Bcr-H2 monoclonal antibody, peroxidase-antiperoxidase, original magnification ×400).*

The CT scan of the thigh showed a tumor arising from the left rectus femoris muscle. Examination of the bone marrow and cerebrospinal fluid did not show any metastases. The lymphoma was classified as stage 3 (Murphy classification), and the child was treated with chemotherapy using the French LMB-89 protocol. She has completed therapy and is currently healthy with resolution of all the swellings.

Large cell lymphomas constitute approximately 20% of all childhood non-Hodgkin lymphomas.[1] Ki-1–positive anaplastic large cell lymphoma (Ki-l+ ALCL) is a tumor that expresses the antigen CD30, which is detected by the monoclonal antibody Ki-1. It is associated with the translocation t(2;5).[2] Seventy percent of ALCL are of T-cell lineage, as in this case.[3] The usual presentation of Ki-1+ ALCL is lymphadenopathy. Common extranodal sites include skin, soft tissue, lung, and bone. Bone marrow and central nervous system involvement is uncommon.[4]

Primary skeletal muscle lymphoma is rare. In a large retrospective series, only 8 (0.1%) of 7000 cases had primary muscle lymphoma, with the thigh and upper arm being the most common sites of involvement.[5] Previous reports in the literature have been mainly in adults, particularly the elderly population.[6]

In children with advanced-stage ALCL, CD30 positivity is associated with a better survival than CD30 negativity.[7] Overall survival rates for children with Ki-1+ ALCL treated with chemotherapy are approximately 70% to 80%, regardless of whether a B-cell or T-cell protocol is used.[8] Our patient responded well to a protocol for B-cell lymphomas.

Accepted for publication November 24, 1999.

Reprints: Bina S. Menon, MRCP (UK), No. 53, Lorong 5/4 H, 46000 Petaling Jaya, Selangor, Malaysia.

REFERENCES

1. Readett DRJ, Gerrard MP. Lymphoma. *Curr Pediatr.* 1998;8:92-97.
2. Bitter MA, Franklin WA, Larson RA, et al. CD30-positive non-Hodgkin's lymphoma is correlated with clinical features and the presence of a unique chromosomal abnormality, t(2;5) (p23;q35). *Am J Surg Pathol.* 1990;14:305-316.
3. Kadin ME. Primary Ki-1 positive anaplastic large-cell lymphoma: a distinct clinicopathologic entity. *Ann Oncol.* 1994;5:25-30.
4. Shad A, Magrath I. Malignant non-Hodgkin's lymphomas in children. In: Pizzo PA, Poplack DG, eds. *Principles and Practice of Pediatric Oncology.* Philadelphia, Pa: Lippincott-Raven; 1997:545-587.
5. Travis WD, Banks PM, Reiman HM. Primary extranodal soft tissue lymphoma of the extremities. *Am J Surg Pathol.* 1987;11:359-366.
6. Yi KK, Liang R. Report of a case of primary skeletal muscle lymphoma and review of the literature. *Acta Haematol.* 1996;96:184-186.
7. Sandlund JT, Pui CH, Santana VM, et al. Clinical features and treatment outcome for children with CD30+ large cell non-Hodgkin's lymphoma. *J Clin Oncol.* 1994;12:895-898.
8. Patte C. Non-Hodgkin's lymphoma. *Eur J Cancer.* 1998;34:359-362.

New Feature: Clinical Problem Solving

The Editor is seeking submissions for a new feature, *Clinical Problem Solving,* which will combine *Picture of the Month, Radiological Case of the Month,* and *Pathological Case of the Month.* Our aim is to demonstrate the thinking process of a master clinician involved in approaching a patient with an unknown disease. The discussion of such cases should place the clinician's expertise into the context of the prevailing medical literature on the topic. Manuscripts should be between 3000 and 4000 words and may include photographs and radiographs.

©2001 American Medical Association. All rights reserved.
Downloaded From: http://archpedi.jamanetwork.com/ on 04/27/2017