

## Pathological Case of the Month

Nandita Kakkar, MD; R. K. Vasishtha, MD, FRCPath; Amit Lamba, MD; Amita Trehan, MD; R. K. Marwaha, MD

**A** 23-DAY-OLD full-term, vaginally delivered boy weighing 3.2 kg at birth had abdominal distension and excessive weight gain. At age 23 days he weighed 4.6 kg and had cushingoid features, edema, hirsutism, and stria on the abdomen. Blood pressure was elevated (170/110 mm Hg). On examination a mass was palpable in the right hypochondriac and lumbar region. The liver was enlarged and firm. Ultrasonography revealed a well-defined mass in the right suprarenal region with a heterogeneous echotexture. Both kidneys were visualized and showed medullary calcinosis. Serum cortisol levels were normal. At autopsy a right suprarenal tumor measuring 6 × 4 × 3 cm and weighing 125 g was removed. Gross and microscopic appearances are shown in **Figures 1, 2, 3, and 4.**

From the Departments of Histopathology (Drs Kakkar, Vasishtha, and Lamba) and Pediatrics (Drs Trehan and Marwaha), Postgraduate Institute of Medical Education and Research, Chandigarh, India.

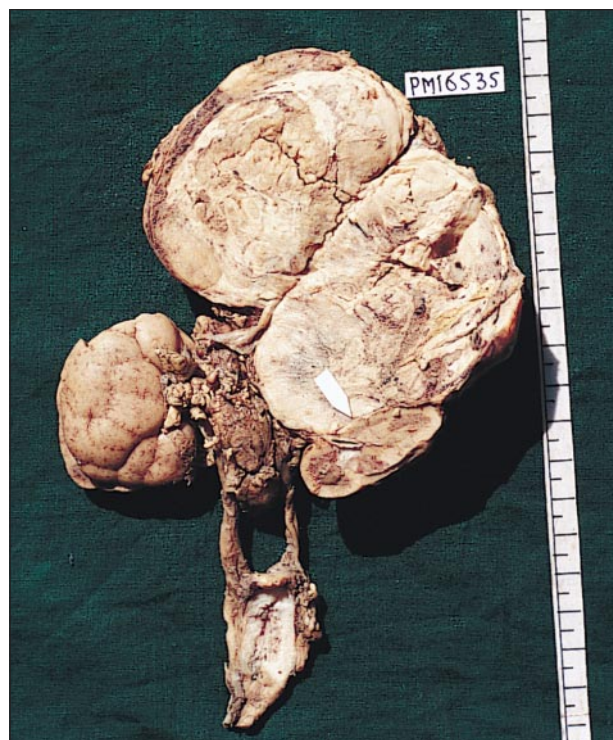

Figure 1.

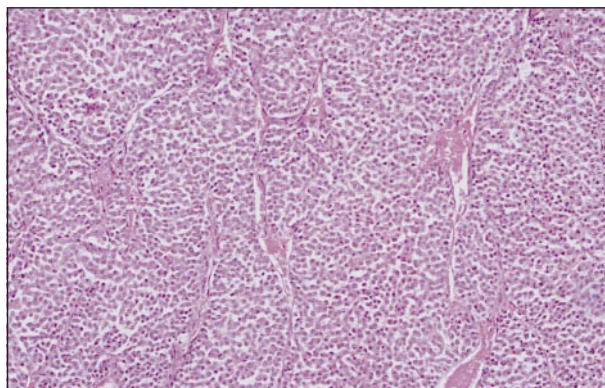


Figure 2.

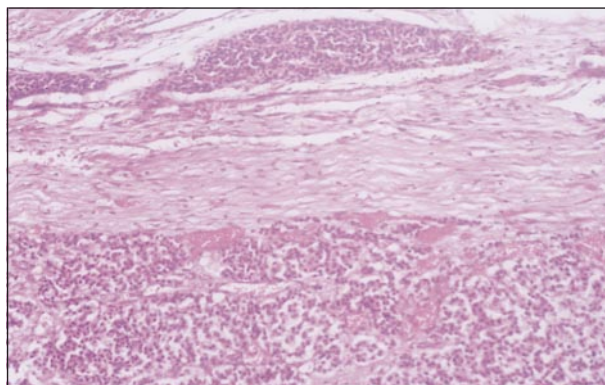


Figure 3.

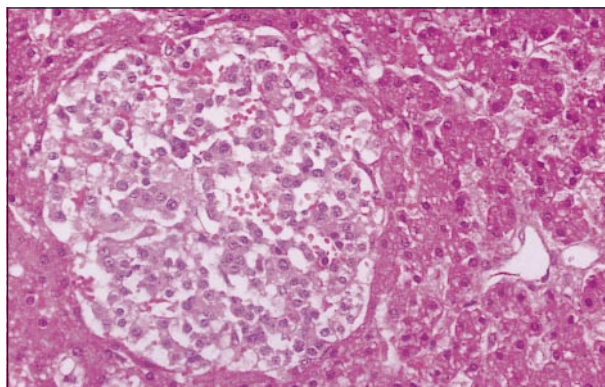


Figure 4.

# Diagnosis and Discussion

## Congenital Adrenocortical Carcinoma

**Figure 1.** Well-encapsulated tumor measuring 6 × 4 × 3 cm pushing the right kidney downward. The photograph has been taken from the posterior aspect.

**Figure 2.** Tumor cells arranged in nests with intervening blood vessels (hematoxylin-eosin, original magnification × 140).

**Figure 3.** Capsular invasion by the tumor (hematoxylin-eosin, original magnification × 140).

**Figure 4.** Metastatic deposits in the liver (hematoxylin-eosin, original magnification × 280).

This child presented with a rare entity: congenital adrenocortical carcinoma with microscopic metastasis to the liver. The tumor revealed 6 of 9 histologic criteria laid out by Medeiros and Weiss,<sup>1</sup> which are found to be associated with adrenal cortical neoplasms that metastasized or recurred. These are capsular invasion, necrosis, sinusoidal invasion, mitosis (>5/50 high-power field), diffuse architecture (>33% of tumor), and eosinophilic tumor cell cytoplasm (>75% of tumor). Above all, the sine qua non of malignant tumors (metastasis to the liver) was also seen.

Adrenocortical carcinoma in children is rare<sup>2-4</sup> and comprises only 0.2% of all childhood malignant tumors.<sup>5</sup> They comprise 6% of childhood malignant adrenal tumors, most being neuroblastomas.<sup>6</sup> Congenital adrenocortical carcinomas are even more rare, and few cases have been published in the world literature.<sup>7-9</sup> In contrast to adults, most of these tumors in children are hormonally active, and perhaps early detection is the reason for their so-called better survival. Clinically, they manifest by virilization, Cushing syndrome, and occasionally with aldosteronism and feminization (in decreasing order of frequency). A mixture of syndromes is the most common mode of presentation. There is greater incidence of functional adrenal tumors in females than males for unexplained reasons. The occurrence of Cushing syndrome resulting from an adrenal cortex tumor in infants in association with hemihypertrophy and urinary tract anomalies as well as various other anomalies suggests oncogenic factors occurring during embryonic development.<sup>2,9,10</sup> Carcinomas outnumber adenomas in childhood adrenocortical tumors.

Most children with adrenal tumors have signs of androgen excess,<sup>3,11</sup> including acne, deepening of voice, muscular appearance, pubic hair, rapid statural growth, and enlarged penis or clitoris. The differential diagnoses in a virilized boy are quite limited and include late-onset congenital adrenal hyperplasia, Leydig cell tumor of the testis, and true isosexual precocity. Virilization associated with features of hypercortisolism or feminization occurs twice as frequently as “pure” virilization.<sup>12</sup> Virilizing tumors tend to be small (≈50 g). Endogenous Cushing syndrome in children younger than age 10 years is usually due to an adrenal tumor,<sup>13</sup> whereas in older children, hyperplasia may

exceed tumors in frequency.<sup>14</sup> Cushing syndrome without virilization is rarely observed. The classic features of Cushing syndrome include obesity, muscle wasting, plethora, round facies, striae, short stature, and hypertension. Linear growth may be normal in children with associated virilization. Truncal obesity may be observed in older children, but infants tend to demonstrate generalized obesity. Primary aldosteronism is rare in children and is usually due to adrenocortical hyperplasia, but few cases are reported in the literature in which primary aldosteronism is due to an adrenocortical tumor.<sup>15,16</sup> Pure feminizing tumors are rarely encountered in children. Only 7 cases of feminizing adenomas in males have been recorded.<sup>17</sup> About 5% of childhood adrenocortical tumors produce no clinical evidence of endocrine dysfunction. This does not mean that they are incapable of steroidogenesis but only that they do not produce an excess of active hormones. Because these tumors do not produce symptoms, they are extremely large at the time of diagnosis and have poor prognosis.

Accepted for publication May 28, 1999.

Reprints: Nandita Kakkar, MD, Department of Histopathology, PGIMER, Chandigarh-160012, India.

### REFERENCES

1. Medeiros LJ, Weiss LM. New developments in the pathologic diagnosis of adrenal cortical neoplasms. *Am J Clin Pathol.* 1992;97:73-83.
2. Miller RW. Peculiarities in the occurrence of adrenal cortical carcinoma [editorial]. *AJDC.* 1978;132:235.
3. Hayles AB, Hahn HB, Sprague RG, et al. Hormone-secreting tumours of the adrenal cortex in children [editorial]. *Pediatrics.* 1966;37:19.
4. Rapaport E, Goldberg MB, Gordan GS, et al. Mortality in surgically treated adrenocortical tumours: review of cases reported for a 20-year period (1930-1949). *Postgrad Med.* 1952;11:325-332.
5. Young JL Jr, Miller RW. Incidence of malignant tumours in US children. *J Pediatr.* 1975;86:254-258.
6. Stewart DR, Jones PA, Jolly SA. Carcinoma of adrenal gland in children. *J Pediatr Surg.* 1974;9:59-67.
7. Burrington JD, Stephens CA. Virilizing tumours of the adrenal gland in childhood: report of eight cases. *J Pediatr Surg.* 1969;4:291-302.
8. Goldstein AE, Rubin SW, Askin JA. Carcinoma of adrenal cortex with adrenogenital syndrome in children: complete review of the literature and report of a case with recovery in a child 8 months of age. *AJDC.* 1946;72:563.
9. Artigas JLR, Niclewicz ED, Silva AdPG, Ribas DB, Athayde SL. Congenital adrenal cortical carcinoma. *J Pediatr Surg.* 1976;11:247-252.
10. Fraumeni JF, Miller RW. Adrenal cortical neoplasms and hemihypertrophy, brain tumour and other disorders. *J Pediatr.* 1967;70:129-138.
11. Kenny FM, Hashide I, Askari A, Siebver WH, Fetterman GH. Virilizing tumour of the adrenal cortex. *AJDC.* 1968;115:445-459.
12. Humphrey GB, ed. *Adrenal and Endocrine Tumors in Children.* Boston, Mass: Kluwer Academic Publishers; 1984:240.
13. Guin GH, Gilbert EF. Cushing's syndrome in children associated with adrenal cortical carcinoma: a case report with review of literature. *AJDC.* 1956;92:297-307.
14. McArthur RG, Cloutier MD, Hayles AB, Sprague RB. Cushing disease in children: findings in 13 cases. *Mayo Clin Proc.* 1972;47:318-336.
15. Canell B, Sandegard E, Hokfelt B. Primary aldosteronism due to an adrenal adenoma in a 3-year-old child. *Acta Paediatr Scand.* 1964;53:205-212.
16. Kelch RP, Connors MH, Kaplan SI, et al. A calcified aldosterone producing tumor in a hypertensive, normokalemic prepubertal girl. *J Pediatr.* 1973;83:432-437.
17. Sultan C, Descomp SB, Garandeau P, Bressot N, Jean R. Pubertal gynecomastia due to an estrogen producing adrenal adenoma. *J Pediatr.* 1976;95:744-746.