

Pathological Case of the Month

Figen Şahin, MD; Tansu Sipahi, MD; Hümeysra Doğan, MD; Ayşegül Oksal, MD; Ülker Ertan, MD

A 13-YEAR-OLD girl was seen for complaints of abdominal distention and inability to walk. Her abdominal distention began in infancy, and her parents noticed that her legs bowed when she walked. In the last few months, she became unable to walk because of pain. On physical examination, her height was 95 cm (<3rd percentile) and her weight was 19 kg (<3rd percentile). Her liver was palpable 8 cm below the costal margin. Enlargement in her wrist and ankle joints and bowing of her legs were noted. She could not stand up without help (**Figure 1**). Radiographs of the extremities revealed severe rickets (**Figure 2**). Results of liver needle aspiration biopsy showed glycogen accumulation in the hepatocytes (**Figure 3**).

Her serum calcium levels were 2.25 mmol/L (9.0 mg/dL); phosphorus levels, 0.52 mmol/L (reference range, 1.25-2.10 mmol/L); alkaline phosphatase levels, 2464 U/L

(reference range, 0-700 U/L); uric acid levels, 0.03 mmol/L (reference range, 0.12-0.42 mmol/L); and cholesterol levels, 6.88 mmol/L (266 mg/dL) (reference range, 0-5.17 mmol/L [0-200 mg/dL]). Her urine showed 4+ glucosuria, 4+ proteinuria, and generalized aminoaciduria. Tubular phosphate reabsorption was calculated as 52% (reference value, >85%).

From the Departments of Pediatrics (Drs Şahin, Sipahi, Doğan, and Ertan) and Pathology (Dr Oksal), Sami Ulus Children's Hospital, Ankara, Turkey.

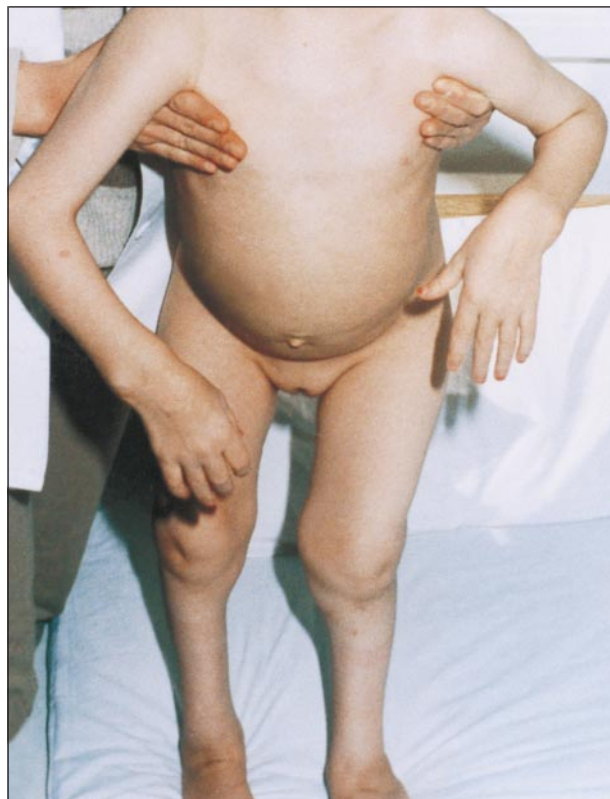

Figure 1.

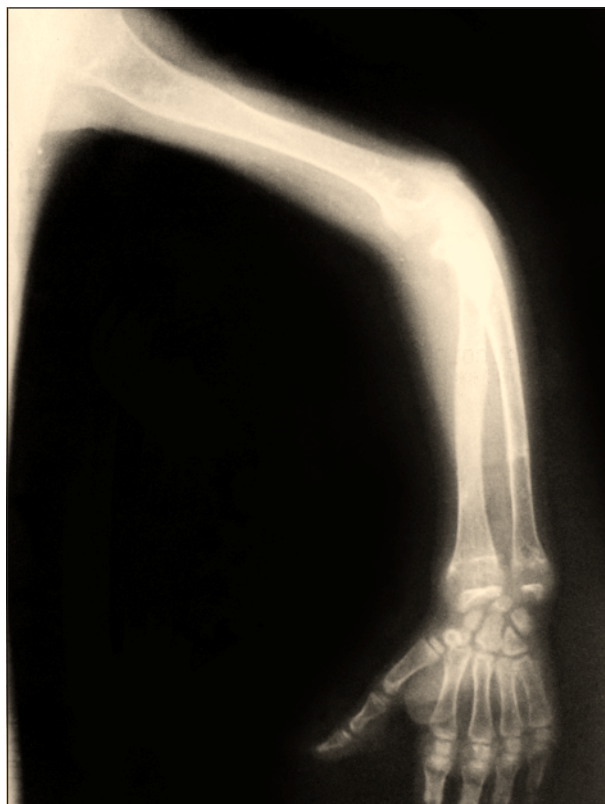

Figure 2.

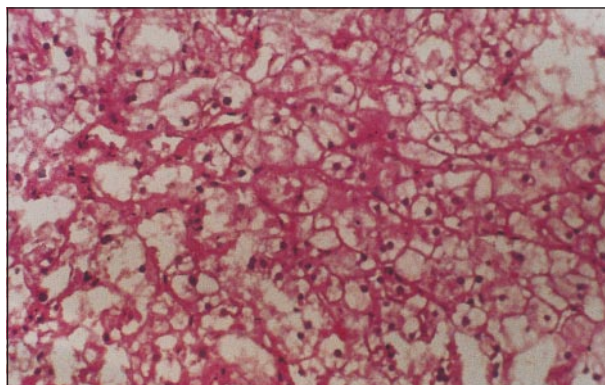


Figure 3.

Diagnosis and Discussion

Glycogen Storage Disease With Renal Tubular Dysfunction (Type XI, Fanconi-Bickel Syndrome)

Figure 1. The patient is unable to stand up because of pain. She is short for her age, and there is bowing in her legs.

Figure 2. Radiographs of the patient's extremities show osteoporosis and severe rickets.

Figure 3. Results of liver needle aspiration biopsy show glycogen accumulation (hematoxylin-eosin, original magnification $\times 200$).

Fanconi-Bickel syndrome is a rare type of glycogen storage disease first described by Fanconi and Bickel in 1949.¹ It is an autosomal recessive disease for which an enzymatic defect has not yet been identified. The disease is characterized by the association of a large liver with massive glycogen accumulation and severe renal tubular dysfunction.² Renal Fanconi syndrome, characterized by urinary loss of phosphate, amino acids, glucose, and bicarbonate, results in severe hypophosphatemic rickets and markedly stunted growth.³

Affected children usually present in the first year of life with failure to thrive. A protuberant abdomen with hepatomegaly and enlarged kidneys are noticeable by age 2 years.⁴ These children develop severe hypophosphatemic rickets early in life unless they receive oral phosphate supplementation. Orally administering phosphate alone to the extent necessary for correction of hypophosphatemia may heal the florid rickets, but adequate growth is not attained. At adolescence these children have an extremely short stature. After puberty the hepatomegaly may recede although hepatic glycogen concentration remains increased. Some patients have additional muscular involvement.⁵

Proximal renal tubular dysfunction with glucosuria, phosphaturia, generalized aminoaciduria, bicarbonate wasting, and hypophosphatemia are characteristic findings. Serum alkaline phosphatase levels are increased, and there are radiological findings of rickets. Mild fasting hypoglycemia and hyperlipidemia may be present, but these are not consistent findings. Uric acid levels are low. Liver transaminases and plasma lactate are

usually normal. Results of tissue biopsy show marked accumulation of glycogen in the hepatocytes and proximal renal tubular cells.

There is no known enzyme deficiency. All measured hepatic glycolytic enzyme activities are normal. Oral galactose tolerance tests typically show galactose intolerance, suggesting an impairment of galactose metabolism. Defective galactose oxidation can be demonstrated in vitro in fresh minced liver tissue and fibroblasts, despite normal activities of hepatic galactokinase, uridyltransferase, and uridyl di phospho-glucose 4-epimerase in homogenates of frozen liver.⁶

There is no specific therapy. Symptomatic replacement of water, electrolytes, vitamin D, and phosphate, restriction of galactose intake, and adequate caloric intake may improve growth. Long-term prognosis is not known.

Accepted for publication February 1, 1999.

Reprints: Figen Şahin, MD, Oyak Sitesi, 7 Blok No. 7, 06550, Çankaya, Ankara, Turkey (e-mail: figens@med.gazi.edu.tr).

REFERENCES

1. Fanconi G, Bickel H. Die chronische aminoacidurie (Aminosäure-diabetes oder nephrotisch-glucosurischer Zwergwuchs) bei der Glykogenese und der Cystinkrankheit. *Helv Paediatr Acta.* 1949;4:359.
2. Sokol PJ. Inborn errors of metabolism. In: Roy CC, Silverman A, Alagille D, eds. *Pediatric Clinical Gastroenterology.* 4th ed. St Louis, Mo: Mosby Year-Book Inc; 1995:812-876.
3. Kliegman RM. Defects in metabolism of carbohydrates. In: Behrman RE, Kliegman RM, Arvin AM, eds. *Nelson Textbook of Pediatrics.* 15th ed. Philadelphia, Pa: WB Saunders Co; 1996:385-397.
4. Chen YT, Burchell A. Glycogen storage diseases. In: Scriver CR, Beaudet AL, Sly WS, Valle D, eds. *The Metabolic and Molecular Basis of Inherited Disease.* 7th ed. New York, NY: McGraw Hill; 1995:935-965.
5. Hurvitz H, Elpeleg ON, Barash V, et al. Glycogen storage disease, Fanconi nephropathy, abnormal galactose metabolism and mitochondrial myopathy. *Eur J Pediatr.* 1989;149:48-51.
6. Brivet M, Moatti N, Corriat A, Lemormier A, Odievre M. Defective galactose oxidation in a patient with glycogen storage disease and Fanconi syndrome. *Pediatr Res.* 1983;17:157-161.