

SECTION EDITOR: BEVERLY P. WOOD, MD

Radiological Case of the Month

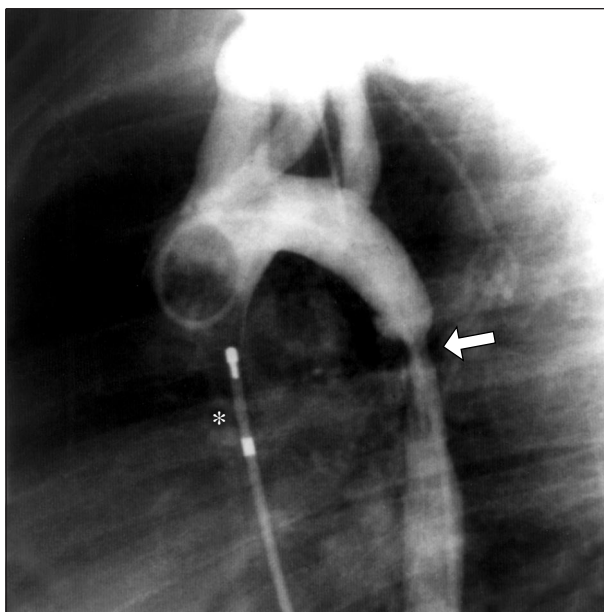
Elizabeth A. Braunlin, MD, PhD; William Krivit, MD; Barbara A. Burke, MD;
Albert P. Rocchini, MD; John E. Foker, MD, PhD; Chester B. Whitley, MD, PhD

A 21-MONTH-OLD boy was referred to our hospital for evaluation of hydrocephalus and unusual facies. A diagnosis of Hurler syndrome was established on the basis of deficient leukocyte α -L-iduronidase enzyme activity, elevated urinary excretion of glycosaminoglycans, and clinical features. The upper extremity blood pressure at initial evaluation was 90/42 mm Hg, and findings from cardiac auscultation revealed a grade II to III/VI

pansystolic murmur heard at the cardiac apex. The liver was enlarged. Pulses were equal to palpation in the upper and lower extremities. A 2-dimensional (D) cardiac sonogram showed thickening of the mitral valve with mild mitral regurgitation, concentric left ventricular hypertrophy, and a normal shortening fraction.

A bone marrow transplantation was performed at age 22 months using marrow obtained from the child's human leukocyte antigen–matched father. A 2-D sonogram, performed at age 23 months, confirmed the previous observations and also demonstrated a discrete acceleration of flow within the thoracic aorta. Fifteen months after the marrow transplantation, the child underwent cardiac catheterization and angiography (**Figure**).

From the Department of Pediatrics (Drs Braunlin, Krivit, Rocchini, and Whitley), Laboratory Medicine and Pathology (Dr Burke), and Surgery (Dr Foker), University of Minnesota Medical School, Minneapolis.



Denouement and Discussion

Coarctation of the Aorta in Hurler Syndrome

Aortogram (left anterior oblique position) demonstrates circumferential narrowing of the descending thoracic aorta (arrow) approximately 2 cm distal to the origin of the left subclavian artery. Centimeter marker catheter is positioned within the right atrium (asterisk).

The Doppler radar–estimated peak instantaneous gradient across this site was 64 mm Hg. Upper extremity hypertension was documented (right arm, 144/88 mm Hg; right leg, 100/50 mm Hg). Because of the recent bone marrow transplantation, the child received a 6-month course of immunosuppression to prevent graft-vs-host disease. The child remained under medical care until full bone marrow engraftment was achieved, immunosuppressive agents could be discontinued, and it was determined that there was neither regression of the stenosis nor reduction in the pressure gradient within the thoracic aorta.

The catheterization confirmed the presence of a 45 mm Hg peak systolic pressure gradient in the thoracic aorta. Aortography demonstrated a 2-cm-long segment of concentric narrowing of the thoracic aorta, originating 2 cm distal to the origin of the left subclavian artery. Balloon angioplasty was not attempted. There was no other region of narrowing within the abdominal aorta by magnetic resonance imaging. Surgical repair was performed by placement of a large prosthetic patch across the site of the narrowing. Six years later, blood pressure measurements and 2-D echocardiograms demonstrate no residual gradient across the operative site.

Deposition of glycosaminoglycans and collagen within the myointima of the epicardial coronary arteries, the atrioventricular and semilunar valves, the myocardium, and the aorta itself have been described in children with Hurler syndrome (mucopolysaccharidosis type I H).¹⁻³ Bone marrow transplantation has prolonged survival and reversed deposition of glycosaminoglycans in children with Hurler syndrome.⁴ Despite successful bone marrow transplantation, narrowing of the descending thoracic aorta was unchanged in our patient. Long-term relief of the obstruction was achieved by successful surgical repair.

Cardiac anomalies are not anticipated in children with mucopolysaccharidosis. Circumferential aortic narrowing may have been present in this child since birth; however, upper extremity blood pressure, measured on several occasions before bone marrow transplantation, was normal. It is more likely that aortic narrowing was an ongoing process related to progressive deposition of glycosaminoglycans and collagen, as in the coronary arteries and atrioventricular valves. A 21% incidence of aortic narrowing is reported for children with mucopolysaccharidosis I,³ although we have not found another case of “coarctation” in 58 children with Hurler syndrome who have undergone bone marrow transplantation. The young age of our patients undergoing bone marrow transplantation may explain the lack of deposition of mucopolysaccharide material in the aorta.

Aortic repair was by synthetic patch rather than anastomosis. Repair of coarctation in a patient with Sly syn-

drome (mucopolysaccharidosis type VII) required an extensive interposition graft owing to a friable aorta.² The unusual nature of the aortic lumen by angiography and magnetic resonance imaging provided assurance that isolated narrowing of the thoracic aorta was present and repair could be achieved. Microscopic evaluation of the involved site demonstrated diffuse myointimal proliferation, deposition of glycosaminoglycans, and cells with distended liposomes within the vessel wall. By contrast, classic coarctation of the aorta consists of a characteristic thickening of the aortic media, accompanied by the overgrowth of intima resulting in a diaphragmlike protrusion into the lumen of the vessel.⁵ Systemic hypertension from thoracic aortic obstruction in children with Hurler syndrome may accelerate damage to coronary arteries and cardiac valves already at risk from infiltration by glycosaminoglycans and collagen. Regression of the obstruction did not occur despite successful bone marrow engraftment.

Accepted for publication November 30, 1998.

Reprints: Elizabeth A. Braunlin, MD, PhD, Fairview-University Medical Center, Box 94, 420 Delaware St SE, Minneapolis, MN 55455.

REFERENCES

1. Renteria VG, Ferrans VJ, Roberts WC. The heart in the Hurler syndrome: gross, histologic and ultrastructural observations in five necropsy cases. *Am J Cardiol*. 1976;38:487-501.
2. Beaudet AL, DiFerrante NM, Ferry GD, Nichols BL Jr, Mullines CE. Variation in the phenotypic expression of B-glucuronidase deficiency. *J Pediatr*. 1975;86:388-394.
3. Taylor DB, Blaser SI, Burrows PE, Stringer DA, Clarke JTR, Thomer P. Arterio-entopathy and coarctation of the abdominal aorta in children with mucopolysaccharidoses: imaging findings. *AJR Am J Roentgenol*. 1991;157:819-823.
4. Hugh-Jones K, Hobbs JR, Vellodi A, Hancock M, Sheldon J, Jones S. Long-term follow-up of children with Hurler's disease treated with bone marrow transplantation. In: Hobbs JR, ed. *Correction of Certain Genetic Diseases by Transplantation*. London, England: COGENT; 1989:103-111.
5. Edwards JE, Christensen NA, Clagett OT, McDonald JR. Pathologic considerations in coarctation of the aorta. *Proc Mayo Clin*. 1948;23:324-332.

Submissions

The Editors welcome contributions to *Pathological Case of the Month*, *Picture of the Month*, and *Radiological Case of the Month*. Those who wish to contribute should send their manuscripts to Dr Gilbert-Barness (*Pathological Case of the Month*), Department of Pathology, Tampa General Hospital, University of South Florida, Davis Island, Tampa, FL 33606; Dr Tunnessen (*Picture of the Month*), The American Board of Pediatrics, 111 Silver Cedar Ct, Chapel Hill, NC 27514-1651; or Dr Wood (*Radiological Case of the Month*), KAM 211, USC-HSC, 1975 Zonal Ave, Los Angeles, CA 90089-9024. Articles and photographs accepted for publication will bear the contributor's name. There is no charge for reproduction and printing of color illustrations.