

SECTION EDITOR: ENID GILBERT-BARNES, MD

Pathological Case of the Month

Kin-Sun Wong, MD; Hui-Ping Liu, MD; Ka-Shun Cheng, MD; Chuen Hsueh, MD

A PREVIOUSLY healthy 11-year-old girl had sudden-onset left-sided chest pain in the morning. On physical examination, a normal-appearing girl had tachypnea and shallow respirations. The trachea was shifted to the right, and her breath sounds were decreased in the left thorax. No clubbing of the fingers was present. Findings from frontal chest radiograph revealed a left tension pneumothorax (**Figure 1**). Her dyspnea was relieved after a left thoracostomy tube was inserted. Computed tomography of the chest disclosed clusters of emphysematous bullae in the left lower lobe (**Figure 2**). Resection of the bullae was performed using a video-assisted thoracoscope (**Figure 3**). Her α_1 -antitrypsin level was 154 mg/dL, which was within reference limits. Results of a pathologic examination of the excised lung showed a prominent emphysematous change

with rupture of alveolar septae that resulted in multiple bullous formations (**Figure 4**). In between the bullae, the lung parenchyma was compressed but structurally normal. The bullae ranged from 0.5 cm to 3.0 cm in diameter without a respiratory epithelium lining.

From the Division of Pediatric Pulmonology (Dr Wong), Chang Gung Children's Hospital, Taoyuan, Taiwan, and the Departments of Thoracic and Cardiovascular Surgery (Dr Liu), Anesthesiology (Dr Cheng), and Pathology (Dr Hsueh), Chang Gung Memorial Hospital, Taipei, Taiwan.

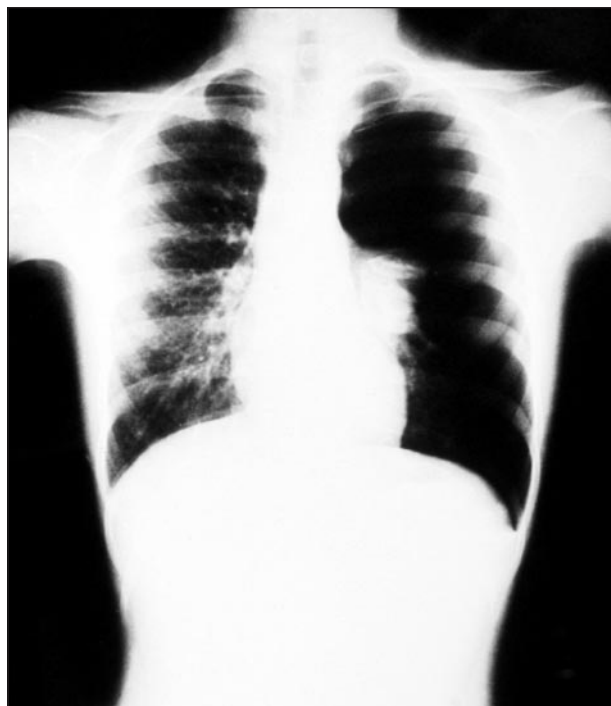

Figure 1.

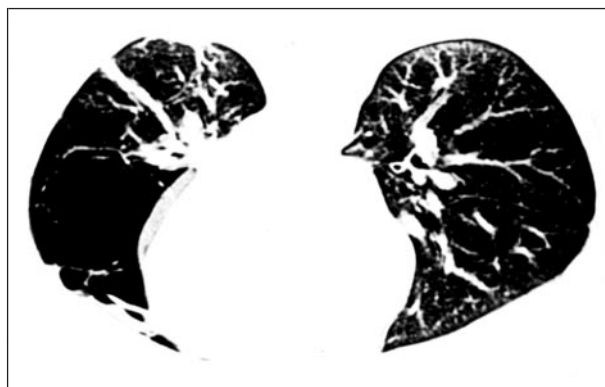

Figure 2.

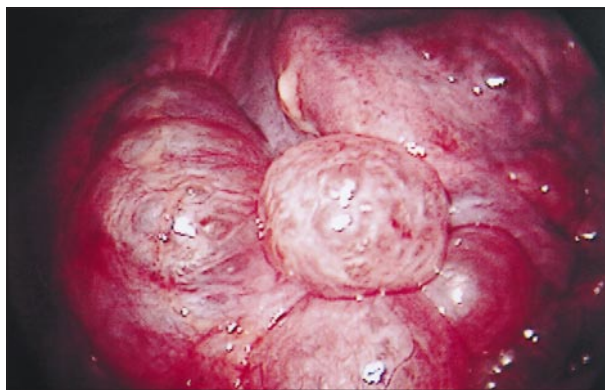


Figure 3.

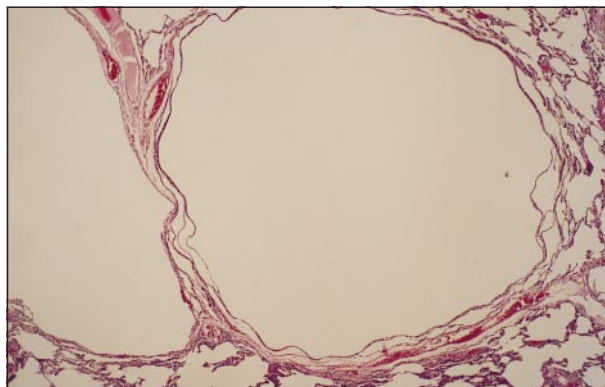


Figure 4.

Denouement and Discussion

Primary Bullous Emphysema With Spontaneous Pneumothorax

Figure 1. Frontal view of chest shows hyperlucent left hemithorax with loss of lung markings, shift of mediastinum to the right, and multiloculated bullous lesions in the collapsed lower lung.

Figure 2. After chest tube insertion, computed tomographic scan of the chest reveals full expansion of the left lung and variable-sized emphysematous bullae in the lingular and superior segment of the left lower lobe.

Figure 3. Operative photograph shows multiple emphysematous bullae in the lingular and superior segment of left lower lobe using a video-assisted thoracoscope.

Figure 4. Microscopic examination revealed several emphysematous bullae as a result of distension and rupture of alveoli (hematoxylin-eosin, original magnification $\times 64$).

Spontaneous pneumothorax is a rare condition in the pediatric population.¹ Apical pulmonary blebs are the most common cause of primary spontaneous pneumothorax in children.² Other causes include cystic fibrosis, Marfan syndrome, bronchial asthma, congenital lung cysts, pyogenic pulmonary infections, and pulmonary tuberculosis.^{2,3} Rarely, cystic adenomatoid malformation or Ewing sarcoma may induce spontaneous pneumothorax in children.^{4,5} Primary bullous emphysema has seldom been reported as a cause of spontaneous pneumothorax in children.

Historically, the terms *bulla*, *bleb*, and *cyst* have been used interchangeably, which has often led to confusion. More precisely, bullae are spaces greater than 1 cm in diameter distal to the terminal bronchioles associated with pulmonary tissue destruction; blebs are localized collections of air between the layers of the visceral pleura; and cysts are lined by recognizable bronchial epithelium or by a fibrous wall.⁶ Furthermore, patients with bullae can be divided into 2 groups: (1) those with structurally normal lung parenchyma in addition to bullae, who account for 20% of cases and are amenable to good surgical results; and (2) those with abnormal parenchyma who are usually refractory to surgical interventions.⁷ Despite various mechanisms suggested for bullous emphysema, the pathogenesis of bullous formation remains unknown.⁷

The most common presenting symptoms of spontaneous pneumothorax are cough, chest pain, and breathlessness. The chest radiograph of spontaneous pneumothorax should be carefully examined for evidence of

pulmonary blebs, which are most commonly seen in the apex of an upper lobe. Computed tomography of the chest is often recommended in the preoperative evaluation of primary spontaneous pneumothorax; however, surgery is indicated owing to the risk of recurrence.

The guidelines for the appropriate management of the spontaneous pneumothorax in older children or early adolescence is similar to adults. The initial treatment of spontaneous pneumothorax depends on the size of pneumothorax and the underlying lung parenchymal abnormalities. Observation is often sufficient if the pneumothorax is less than 15% of the hemithorax and there is no related tension. Thoracotomies may become necessary when an underlying cause is found.⁸ Bullectomy can be performed by traditional thoracotomy or using video-assisted thoracoscopic surgery.⁹ Good results with minimal morbidity and mortality can usually be expected using this technique.

Accepted for publication May 18, 1999.

Reprints: Kin-Sun Wong, MD, Chang Gung Children's Hospital, Division of Pediatric Pulmonology, 5 Fu Hsin St, Taoyuan, Taiwan.

REFERENCES

1. Congenital malformations of the bronchi, lungs, diaphragm and rib cage. In: Phelan PD, Landau LI, Olinsky A, eds. *Respiratory Illness in Children*. London, England: Blackwell Scientific Publications; 1990:311-347.
2. Poenaru D, Yazbeck S, Murphy S. Primary spontaneous pneumothorax in children. *J Pediatr Surg*. 1994;29:1183-1185.
3. Beg MH, Reyazuddin, Faridi MMA, et al. Spontaneous pneumothorax in children: a review of 95 cases. *Ann Trop Paediatr*. 1988;8:18-21.
4. Bentur L, Canny G, Thorner P, Superina R, Babyn P, Levison H. Spontaneous pneumothorax in cystic adenomatoid malformation. *Chest*. 1991;99:1292-1293.
5. Arias de la Vega F, Illarramendi JJ, Martinez E, Vila E, Martinez-Penuela JM, Dominguez MA. Spontaneous pneumothorax as the first manifestation of Ewing's sarcoma. *Pediatr Pulmonol*. 1995;19:182-184.
6. Shamji FM. Classification of cystic and bullous lung disease. *Chest Surg Clin North Am*. 1995;5:701-716.
7. Deslauriers J, Leblanc P. Management of bullous disease. *Chest Surg Clin North Am*. 1994;4:539-559.
8. Wilcox DT, Glick PL, Karamanoukian HL, Allen JE, Azizkhan RG. Spontaneous pneumothorax: a single-institution, 12-year experience in patients under 16 years of age. *J Pediatr Surg*. 1995;30:1452-1454.
9. Waller DA, Forty J, Soni AK, Conacher ID, Morritt GN. Videothoracoscopic operation for secondary spontaneous pneumothorax. *Ann Thorac Surg*. 1994;57:1612-1615.