

SECTION EDITOR: BEVERLY P. WOOD, MD

# Radiological Case of the Month

Sarah G. Klein, MD; Ira N. Adler, MD

**A** 10-YEAR-OLD boy was seen for a 3-day history of right-sided abdominal pain, widespread cutaneous petechiae, and a 2-day history of fever (temperatures up to 39°C). A pertinent finding from medical history was a diagnosis of lymphoblastic lymphoma 2½ years previously. He had a relapse 1 year previously with acute myeloblastic leukemia and underwent bone marrow transplantation 8 months previously. He had another relapse with acute myeloblastic lymphoma 1 month prior to this admission, and subsequently received chemotherapy 1

*From the Department of Radiology, Arkansas Children's Hospital, Little Rock.*

week prior to being seen for right-sided abdominal pain. On physical examination, his abdomen was nondistended but diffusely tender, especially on the right. Diffuse petechiae of the lower extremities were also present. Laboratory results showed pancytopenia with neutropenia (hematocrit level, 0.20; white blood cell count,  $1.83 \times 10^9/L$ ; and platelet level,  $2 \times 10^9/L$ ). After a transfusion of platelets and packed red blood cells, he felt subjectively better. His abdomen remained soft with mild tenderness. Abdominal ultrasonography was performed to rule out cholecystitis or possible appendicitis (**Figure 1** and **Figure 2**). Abdominal and pelvic computed tomography (CT) were also performed (**Figure 3** and **Figure 4**).

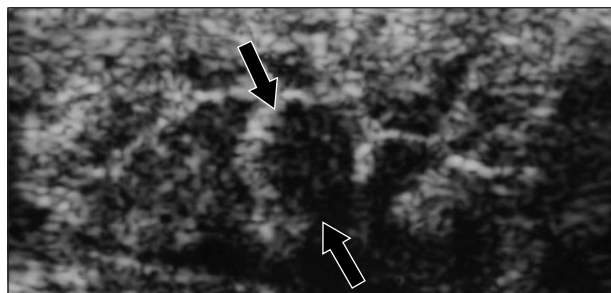


Figure 1.

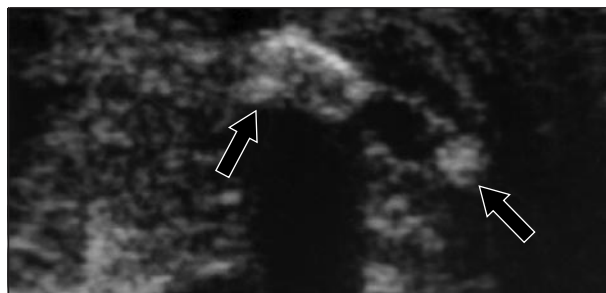


Figure 2.

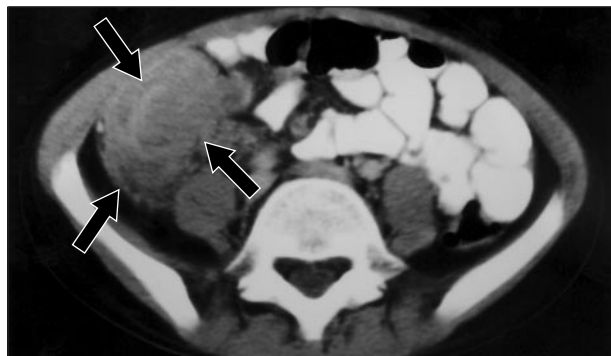


Figure 3.

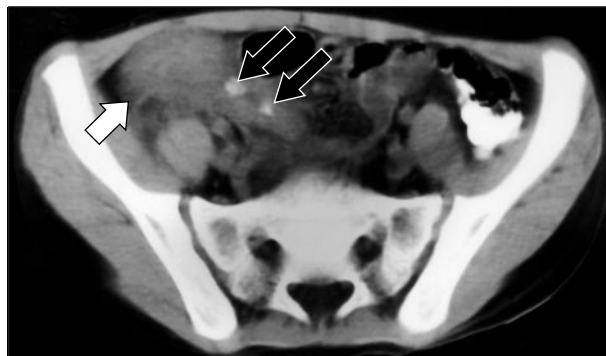

Figure 4.

# Denouement and Discussion

## Typhlitis With Concurrent Appendicitis

**Figure 1.** Ultrasound of right lower quadrant demonstrated hypoechoic mucosal thickening and polypoid appearance (black arrows) of the cecal mucosa.

**Figure 2.** Same ultrasound of right lower quadrant (more inferiorly) showed the appendix with 2 echogenic round appendicoliths (black arrows) producing posterior acoustical shadowing.

**Figure 3.** Computed tomographic scan at the same anatomical location of Figure 1 ultrasound showed thickening of the wall and mucosa of cecum (black arrows).

**Figure 4.** Computed tomographic scan at the same anatomical location of Figure 2 ultrasound demonstrated thick cecum (open white arrow) and appendix, with 2 hyperdense appendicoliths (black arrows) within the appendix.

The patient was given clindamycin hydrochloride as antibiotic coverage for the presumed diagnosis. The patient was also given pain control medication. Transfusions continued, with rising hematocrit level and platelet count, but there was persistent pancytopenia. Right lower quadrant guarding and tenderness subsided over 1 week, and the patient was discharged home.

Typhlitis is a necrotizing inflammation of the colon and ileum in neutropenic patients. The cecum (*typhlon* in Greek) is the region most frequently involved. It occurs in patients with leukemia but may also develop in patients with lymphoma, aplastic anemia, cyclic neutropenia, and acquired immunodeficiency syndrome or after organ transplantation. The cause is bacterial invasion of the colonic wall, compromised by chemotherapy. Cytomegalovirus and *Mycobacterium tuberculosis* are the pathogens isolated most commonly.<sup>1</sup> The most frequent symptoms include fever, abdominal pain, and distention.<sup>2</sup> Typhlitis, appendicitis, intussusception, perforation, and intestinal obstruction all may present with symptoms in the right lower quadrant, leaving the surgeon with a diagnostic dilemma.<sup>3</sup> The treatment for typhlitis is usually supportive using antibiotics, and surgery is reserved for secondary perforation and peritonitis.<sup>2</sup>

Radiographic findings of typhlitis may include a paucity of bowel gas in the right lower quadrant, small bowel ileus, ascites, and mechanical obstruction. The prominent mucosal thickening and polypoid appearance of the mucosa make the ultrasonographic picture of typhlitis different from other diseases affecting the cecal area, such as granulomatous colitis, appendicitis, and intussusception. Typically, the edema and thickening of the bowel wall in these conditions is hypoechoic as opposed to the echogenic thickening in typhlitis.<sup>3,4</sup> Computed tomography of typhlitis has shown thickening of the bowel wall and mucosa of the cecum and ascending colon.

With ultrasonography, the normal appendix is compressible, with a wall less than 3-mm thick. Ultrasound visualization of the appendix with a total diameter greater than 6 mm in a patient with right lower quadrant pain is

highly suggestive of acute appendicitis. Visualization of an appendicolith, regardless of appendiceal diameter, should also be regarded as a positive finding.<sup>1</sup> Compared with ultrasound, similar sensitivities and specificities have been shown with prospective studies using CT to diagnose appendicitis in children. A normal appendix can be seen in 50% of healthy children on CT examinations. It appears as a tubular structure, with a thin wall surrounded by homogeneous low-attenuation fat. Findings from CT of appendicitis can be classified as primary or secondary. Primary signs are pathognomonic and include either visualization of an inflamed appendix or appendicolith associated with inflammatory changes. Secondary signs are suggestive but not diagnostic and can be seen with other inflammatory processes such as Crohn disease and pelvic inflammatory disease. These include inflammatory changes or abscess in the right lower quadrant or pelvis without visualization of an abnormal appendix or appendicolith.<sup>5</sup>

Accepted for publication November 30, 1998.

Reprints: Sarah G. Klein, MD, Department of Radiology, Arkansas Children's Hospital, 800 Marshall St, Slot 700, Little Rock, AR 72202 (e-mail: KleinSarahG@exchange.uams.edu).

## REFERENCES

1. Rumack CM. *Diagnostic Ultrasound, 2nd ed.* Vol 1. St Louis, Mo: Mosby-Year Book Inc; 1998:304, 316.
2. Kirks DR. *Practical Pediatric Imaging.* Philadelphia, Pa: Lippincott-Raven Publishers; 1998:945.
3. Alexander JE, Williamson SL, Seibert JJ, et al. The ultrasonographic diagnosis of typhlitis (neutropenic colitis). *Pediatr Radiol.* 1988;18:200-204.
4. Rodgers B, Seibert JJ. Unusual combination of an appendicolith in a leukemic patient with typhlitis: ultrasound diagnosis. *J Clin Ultrasound.* 1980;18:191-193.
5. Friedland JA, Siegel MJ. CT appearance of acute appendicitis in childhood. *Am J Radiol.* 1997;168:439-442.

## Submissions

The Editors welcome contributions to Pathological Case of the Month, Picture of the Month, and Radiological Case of the Month. Those who wish to contribute should send their manuscripts to Dr Gilbert-Barness (Pathological Case of the Month), Department of Pathology, Tampa General Hospital, University of South Florida, Davis Island, Tampa, FL 33606; Dr Tunnessen (Picture of the Month), The American Board of Pediatrics, 111 Silver Cedar Ct, Chapel Hill, NC 27514-1651; or Dr Wood (Radiological Case of the Month), KAM 211, USC-HSC, 1975 Zonal Ave, Los Angeles, CA 90089-9024. Articles and photographs accepted for publication will bear the contributor's name. There is no charge for reproduction and printing of color illustrations.