SECTION EDITOR: ENID GILBERT-BARNESS, MD

Pathological Case of the Month

Kappa P. Meadows, MD; Conleth A. Egan, MB, MRCPI; Sheryll L. Vanderhooft, MD

A 4-YEAR-OLD white girl had an enlarged frontal bone at birth. She had reconstructive surgery, and findings from bone biopsy showed fibrous dysplasia. Physicians in the dermatology department were consulted because of an 18-month history of "growths" on both feet. On examination, she had a dysmorphic facies with frontal bossing and a broad nasal root. An epidermal nevus followed Blaschko lines on the right posterior neck (**Figure 1**). There was cerebriform hyperplasia of both soles, with macrodactyly most notable on the right second toe (**Figure 2**). A faint port-wine stain was also observed on the left upper lateral thigh. A specimen from shave biopsy was obtained from the hypertrophic soft tissue on the toe. There was marked, dense, dermal fibrosis with mild disorganization and minimal cellularity (**Figure 3**). The fibrosis was well visualized by trichrome stain (**Figure 4**).

From the Department of Dermatology, University of Utah Health Sciences Center, Salt Lake City.

Figure 1.

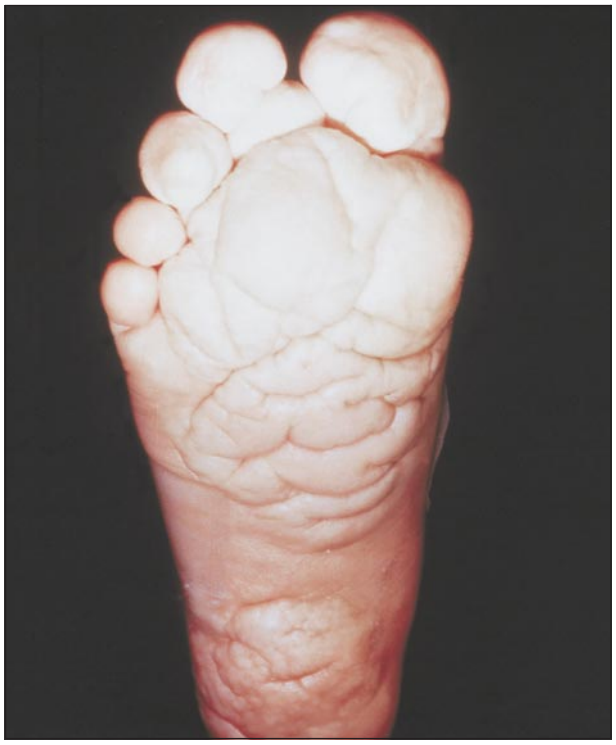

Figure 2.

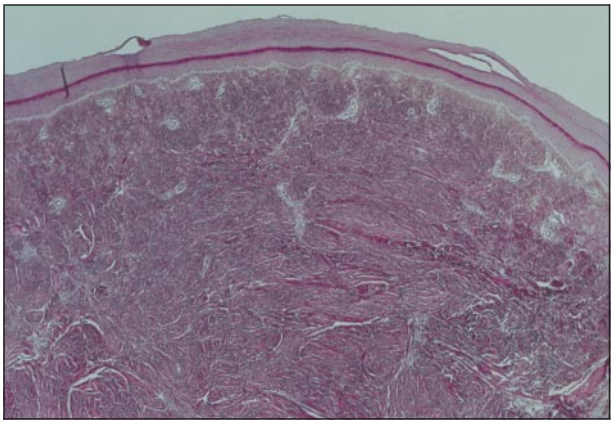

Figure 3.

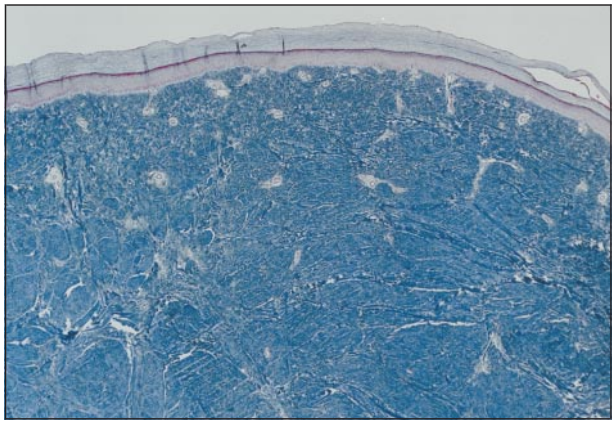

Figure 4.

©2000 American Medical Association. All rights reserved.
Downloaded From: http://archpedi.jamanetwork.com/ on 01/24/2017

Diagnosis and Discussion

Proteus Syndrome

Figure 1. *Epidermal nevus on right posterior neck.*

Figure 2. *Cerebriform hyperplasia of the right sole.*

Figure 3. *Findings from biopsy specimen obtained from the right second toe showing dermal fibrosis (hematoxylin-eosin, original magnification ×150).*

Figure 4. *Trichrome stain of biopsy specimen seen in Figure 3 showing dermal fibrosis (original magnification ×150).*

In Greek mythology, Proteus was the "Old Man of the Sea." He could change shape at will to avoid capture. The term *Proteus syndrome* was first used by Wiedmann et al[1] in 1983 to describe this condition with polymorphous clinical manifestations. It is a congenital hamartomatous condition of unknown cause that affects all 3 germ layers and results in asymmetrical overgrowth of almost any part of the body.

Proteus syndrome is a heterogeneous collection of clinical findings. Darmstadt and Lane[2] have developed a scoring system to aid in its diagnosis (**Table**). Based on this system, our patient scored 15.5 points. Proteus syndrome shares features in common with many other hamartomatous conditions, such as Klippel-Trenaunay syndrome, Parkes-Weber syndrome, neurofibromatosis type I, and encephalocraniocutaneous lipomatosis. However, cerebriform hyperplasia of the soles and/or palms is only found in Proteus syndrome, and it is considered by some to be a pathognomonic sign of this disorder.[3] This finding may not develop as quickly as the other features of Proteus syndrome, as was the case in our patient. The most important aspect in caring for these patients is to adapt a multidisciplinary approach. Reconstructive surgery offers the best chance of rehabilitation; therefore, early consultation with plastic and orthopedic surgeons is important. Although the cause is unknown, 2 cases of possible parent-to-child transmission have been reported, indicating that this may be in some cases an inherited disorder, and therefore, consultation with a geneticist may also be important.[4,5]

Scoring System for Diagnosis of Proteus Syndrome*

Feature	Score
Macrodactyly and/or hemihypertrophy	5.0
Skin thickening (plantar and/or palmar cerebriform hyperplasia)	4.0
Lipomas and subcutaneous tumors	4.0
Verrucous epidermal nevus	3.0
Macrocephaly or skull exostoses	2.5
Miscellaneous minor abnormalities (ptosis, epicanthal folds, low-set ears, malformed teeth)	1.0

**Total of 13 points needed for diagnosis.*

Accepted for publication September 1, 1998.

Presented as a poster at the 56th Annual Meeting of the American Academy of Dermatology, Orlando, Fla, February 27-March 4, 1998.

Reprints: Sheryll L. Vanderhooft, MD, Department of Dermatology, University of Utah Health Sciences Center, 50 N Medical Dr, Salt Lake City, UT 84132.

REFERENCES

1. Wiedmann HR, Burgio GR, Aldenhoff P, et al. The Proteus syndrome. *Eur J Pediatr.* 1983;140:5-12.
2. Darmstadt GL, Lane AT. Proteus syndrome. *Pediatr Dermatol.* 1994;11:222-226.
3. Hotamisligil GS. Proteus syndrome and hamartoses with overgrowth. *Dysmorphol Clin Genet.* 1990;4:87-102.
4. Goodship J, Redfearn A, Milligan D, et al. Transmission of Proteus syndrome from father to son? *J Med Genet.* 1991;28:781-785.
5. Pelz GKL, Wiedmann HR. Transmission of Proteus syndrome from mother to son? *Am J Med Genet.* 1993;45:117-118.

©2000 American Medical Association. All rights reserved.
Downloaded From: http://archpedi.jamanetwork.com/ on 01/24/2017