

SECTION EDITOR: WALTER W. TUNNESSEN, JR, MD

## Picture of the Month

Chi-Yu Huang, MD; Yann-Jinn Lee, MD; Hung-Chang Lee, MD; Fu-Yuan Huang, MD

**A** 7-DAY-OLD infant was noted to have bluish discoloration of the scrotal, inguinal, and perineal areas, bilaterally (**Figure 1**). The testes were palpable, nontender, and seemed to have normal consistency. The infant was born after 40 weeks' gestation to a gravida 2, para 2 woman. He was delivered vaginally with the aid of vacuum extraction and weighed 3800 g, with Apgar scores of 9 and 10 at 1 and 5 minutes, respectively. Other than mild swelling of the scrotum noted soon after birth, findings from physical examination were unremark-

able. The neonatal course was complicated by decreasing appetite and jaundice. Findings from ultrasonographic scan of the abdomen obtained on day 7 showed masses with mixed echogenic patterns above both kidneys (**Figure 2**). Findings from repeated ultrasonographic scan 4 days later showed cystic changes in the masses (**Figure 3**).

From the Department of Pediatrics, Mackey Memorial Hospital, Taipei, Taiwan.

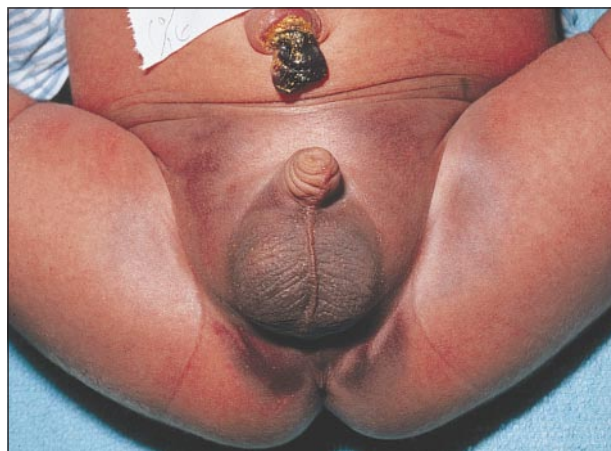


Figure 1.

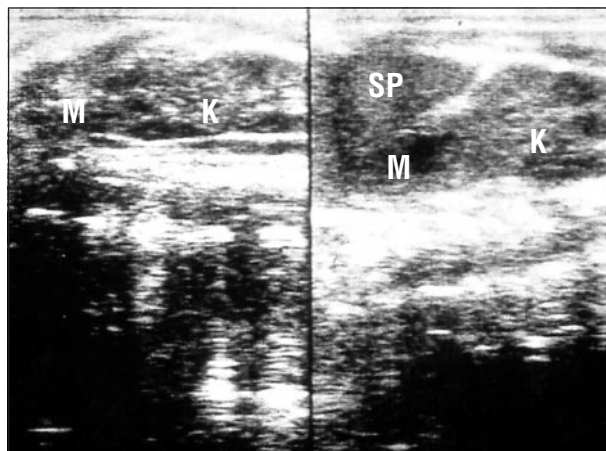


Figure 2.

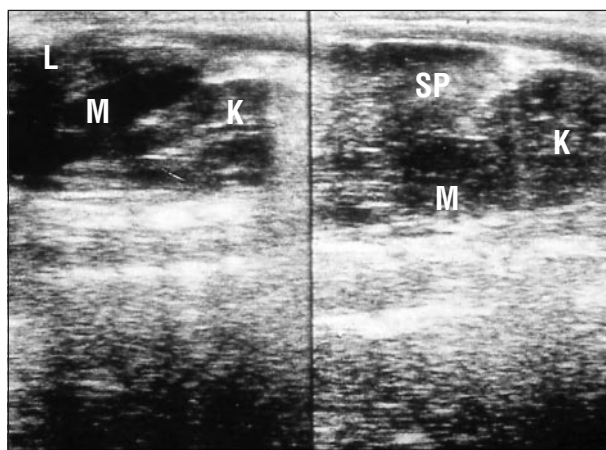


Figure 3.

# Denouement and Discussion

## Neonatal Adrenal Hemorrhage

**Figure 1.** A scrotal hematoma is present with bluish discoloration of the groin and perineal skin.

**Figure 2.** Ultrasonogram shows hemorrhage in both adrenal glands with partial liquefaction. K indicates kidney; L, liver; SP, spleen; and M, hemorrhagic mass.

**Figure 3.** A repeated ultrasonogram 4 days later shows more complete liquefaction of the hemorrhage in both adrenal glands. K indicates kidney; L, liver; SP, spleen; and M, hemorrhagic mass.

The incidence of discovering neonatal adrenal hemorrhage at autopsy<sup>1</sup> and by ultrasonographic screening<sup>2</sup> is 1.7 and 1.9 per 1000 births, respectively. Its pathogenesis is not known, but the relatively large size and extensive vascularity of the adrenal gland may result in vulnerability to mechanical compression and changes in venous pressure during delivery. Predisposing factors include difficult labor or delivery, high birth weight, asphyxia, septicemia, and hemorrhagic disorders. The right adrenal gland is 3 to 4 times more frequently involved than the left; only 5% to 10% of cases reported have bilateral hemorrhage.<sup>3</sup> Prenatal diagnosis of adrenal hemorrhage may be made by findings from fetal ultrasonography.<sup>4</sup>

In a report of 12 cases of adrenal hemorrhage presenting as scrotal hematomas, 6 underwent surgical exploration for suspected torsion of the testis.<sup>5</sup> The testes were normal in all 6, and findings from postoperative ultrasonography revealed ipsilateral adrenal hemorrhage. Surgical exploration of 4 infants revealed hematomas localized outside the tunica vaginalis of the testis with retroperitoneal communication. In 2 cases, hematomas were localized within the tunica vaginalis with peritoneal cavity communication. These findings suggest that blood from the adrenal bed can dissect along the fat tissue and reach the scrotum through the inguinal canal, or it can reach the scrotum through a patent processus vaginalis testis from the peritoneal cavity through a rupture of the posterior parietal peritoneum. The passage of blood down the inguinal canal into the scrotum often results in discoloration of the abdominal skin or groin.

### CLINICAL FEATURES

Clinical features of adrenal hemorrhage are variable. Minor bleeding into the adrenal cortex may be asymptomatic, only to be noted by adrenal calcification later in life. Massive adrenal hemorrhage is an uncommon but life-threatening event. Affected infants may show signs of hypovolemic shock. The more common presentation is one of pallor, apnea, and hypothermia with a falling hematocrit level and persistent indirect hyperbilirubinemia.<sup>3,6</sup> Adrenal hemorrhage is typically contained within the capsule of the gland so that a flank mass may be palpated, most commonly on the right side.<sup>2,3</sup> Rarely, the capsule of the adrenal gland may burst, spreading blood into the retroperitoneum or peritoneal cavity, which may descend into the groin or scrotum, presenting as a scrotal hematoma.

### DIFFERENTIAL DIAGNOSIS

Scrotal swelling in newborns may arise from several disorders, including torsion of the testis, orchitis, scrotal or testicular edema, hydrocele, inguinal hernia, meconium peritonitis, hemocele, testicular tumor, and traumatic hematoma.<sup>7</sup> In neonates, liver laceration with intra-abdominal hemorrhage causing a scrotal mass<sup>8</sup> and antenatal perforation of a Meckel diverticulum presenting as an inflamed hydrocele<sup>9</sup> have been reported. A thorough history, physical examination, and ultrasonography of the abdomen and/or testes are essential for diagnosis. Ultrasonography may be the most suitable imaging technique for the diagnosis and follow-up of neonatal adrenal hemorrhage.<sup>10</sup> When clinical uncertainty persists, nuclear scanning or color Doppler studies are required to exclude testicular torsion, which is a true surgical emergency.<sup>7</sup>

### TREATMENT

Adrenal hemorrhage is usually self-limited; surgical exploration should only be performed if the hemorrhage is not controlled or a hematoma develops into an infected abscess and needs to be drained.<sup>3</sup> Blood or volume replacement may be indicated if the infant has signs of hypovolemic shock. Adrenal insufficiency is rare, transient, and responds well to steroid replacement therapy.<sup>3</sup> Ultrasonographic examination of the abdomen and scrotum should be performed in infants with scrotal swelling or ecchymoses to detect adrenal hemorrhage. Consideration of this diagnosis and early detection will permit conservative treatment without surgical exploration.

Accepted for publication September 10, 1999.

Reprints: Yann-Jinn Lee, MD, Department of Pediatrics, Mackey Memorial Hospital, 92 Chung-Shan North Rd, Section 2, Taipei 10449, Taiwan.

### REFERENCES

1. DeSa DJ, Nicholls S. Hemorrhagic necrosis of the adrenal gland in perinatal infant: a clinico-pathological study. *J Pathol.* 1972;106:133-149.
2. Felc Z. Ultrasound in screening for neonatal adrenal hemorrhage. *Am J Perinatol.* 1995;12:363-366.
3. Khuri FJ, Alton DJ, Hardy BE, Cook GT, Churchill BM. Adrenal hemorrhage in neonates: report of 5 cases and review of the literature. *J Urol.* 1980;124:684-687.
4. Sherer DM, Kendig JW, Sickel JZ, Salafia CM, Donahue ML. In utero adrenal hemorrhage associated with fetal distress, subsequent transient neonatal hypertension, and a nonfunctioning ipsilateral kidney. *Am J Perinatol.* 1994;11:302-304.
5. Miele V, Galluzzo M, Patti G, Mazzoni G, Calisti A, Valenti M. Scrotal hematoma due to neonatal adrenal hemorrhage. *Pediatr Radiol.* 1997;27:672-674.
6. Black J, Williams DI. Natural history of adrenal hemorrhage in the newborn. *Arch Dis Child.* 1973;48:183-190.
7. Gilchrist BF, Lobe TE. The acute groin in pediatrics. *Clin Pediatr (Phila).* 1992; 31:488-496.
8. Eraklis AJ. Abdominal injury related to the trauma of birth. *Pediatrics.* 1967;39: 421-424.
9. Wright JE, Bhagwande SB. Antenatal perforation of Meckel's diverticulum presenting as an inflamed hydrocele. *J Pediatr Surg.* 1986;21:989-990.
10. Wang PA, Lee HC. Sonography of neonatal adrenal hemorrhage: analysis of 30 cases and differential diagnosis. *J Med Ultrasound.* 1994;2:169-175.