

SECTION EDITOR: ENID GILBERT-BARNES, MD

## Pathological Case of the Month

R. K. Vasishtha, MD, FRCPath; Nandita Kakkar, MD; A. K. Banerjee, MD, FRCPath; R. K. Marwaha, MD

**A** 2-MONTH-OLD male infant presented with fever, which he had since age 1 month, and recurrent generalized seizures. On physical examination, jaundice, low-set ears, and a flattened nasal bridge were seen. The liver (4 cm below the right costal margin) and spleen (9 cm below the right costal margin) were palpable below the respective costal margins. Punched out ulcers in the perianal region were also seen. He was third in the birth order, with 2 older siblings who are still alive and healthy. There was no family history of consanguinity. Investigations revealed pancytopenia, a hemoglobin level of 40 g/L; a platelet count of  $10 \times 10^9/L$ ; total leukocyte count of  $0.0027 \times 10^9/L$ , with 0.16 polymorphonuclear leukocytes, 0.78 lymphocytes, 0.04 myelocytes, and 0.2 monocytes; a prothrombin time of 25 seconds (control, 14 seconds), and a prothrombin thromboplastin time with a kaolin level 120 seconds (control, 35 seconds). There was hypofibrinogenemia (120 mg/L) with increased levels of serum bilirubin (131.67  $\mu\text{mol/L}$  [7.7 mg/dL]) and alkaline phosphatase (27 King-Armstrong units). A Venereal Disease Research Laboratory test was

nonreactive; toxoplasma and herpes simplex virus titers and human immunodeficiency virus and urine tests for CMV were negative. Computed tomographic scan of the head revealed a mild hydrocephalous with periventricular lucencies.

### PATHOLOGIC FINDINGS

The brain weighed 505 g and exhibited mild hydrocephalus, periventricular sclerosis, and focal softening. The central white matter was focally soft with degeneration and fissuring (**Figure 1**). Microscopically, meningeal infiltration by lymphohistiocytes was seen (**Figure 2**). There was widespread periventricular and intraparenchymal (gray and white matter) perivascular lymphohistiocytic infiltration mimicking an encephalitic process (**Figure 3**). The brain between the perivascular infiltration showed astrocytic proliferation admixed with diffusely infiltrating as well as nodular histiocyte aggregates (**Figure 4**). Similar perivascular infiltration was observed in the thalamus, globus pallidus, midbrain, and pons. The liver and spleen were enlarged (**Figure 5**). There was a heavy benign lymphohistiocytic infiltrate in the liver sinusoids (**Figure 6**), spleen, red pulp, bone marrow, lymph nodes, skin, adrenal glands, pancreas, intestines, kidneys, and perianal area. The infiltrate revealed prominent erythrophagocytosis.

---

*From the Departments of Histopathology (Drs Vasishtha, Kakkar, and Banerjee) and Pediatrics (Dr Marwaha), Postgraduate Institute of Medical Education and Research, Chandigarh, India.*

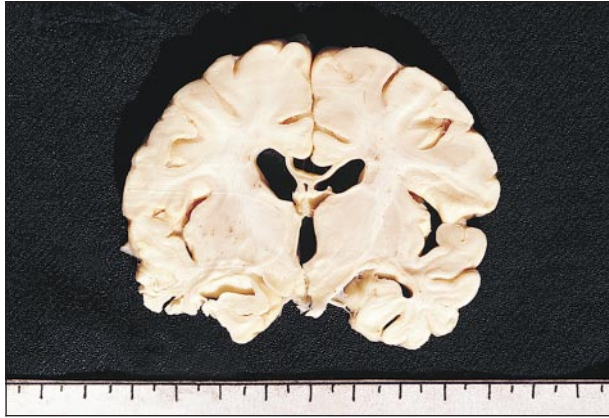

Figure 1.

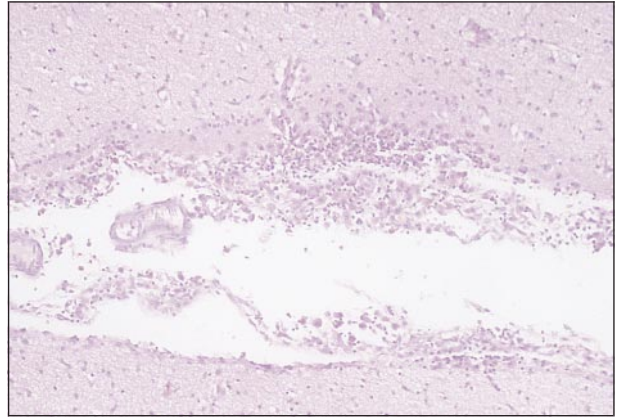


Figure 2.

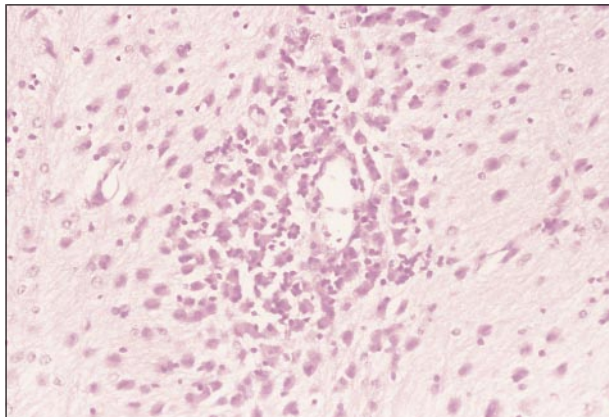


Figure 3.

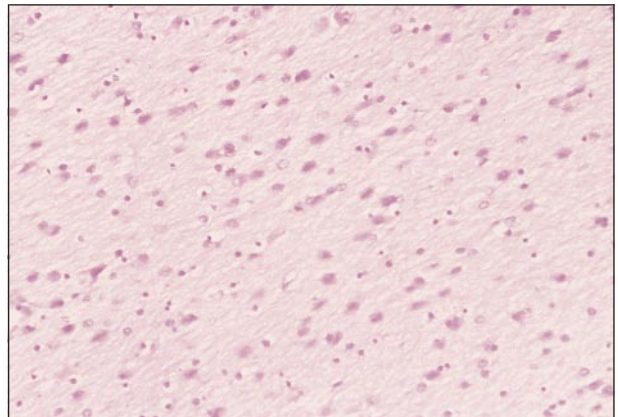


Figure 4.

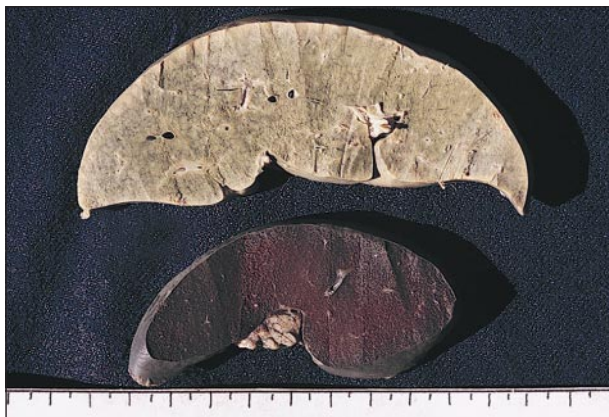

Figure 5.

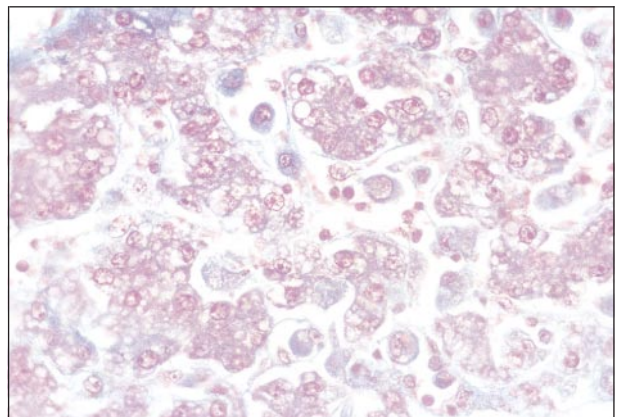


Figure 6.

# Diagnosis and Discussion

## Neuropathology of Familial Hemophagocytic Lymphohistiocytosis

**Figure 1.** Coronal slice of the brain showing mild dilation of the ventricles and periventricular sclerosis. Focal softening with degeneration is also seen.

**Figure 2.** Microphotograph showing heavy lymphohistiocytic infiltrate in the meninges (hematoxylin-eosin, original magnification  $\times 140$ ).

**Figure 3.** Microphotograph of the brain showing a heavy perivascular lymphohistiocytic infiltrate (hematoxylin-eosin, original magnification  $\times 280$ ).

**Figure 4.** Microphotograph of the brain showing a lymphohistiocytic infiltrate diffusely infiltrating the parenchyma and intermingling with the proliferating astrocytes (hematoxylin-eosin, original magnification  $\times 280$ ).

**Figure 5.** Gross photograph of a slice of the enlarged liver and spleen.

**Figure 6.** Microphotograph of the liver with sinusoids packed with histiocytes showing prominent erythrophagocytosis (Masson trichrome, original magnification  $\times 280$ ).

**F**amilial hemophagocytic lymphohistiocytosis (FHL) is an autosomal recessive disorder that is indistinguishable from viral-associated hemophagocytic syndrome (VAHS). Both disorders are included in the broad category of hemophagocytic lymphohistiocytosis (class 2 histiocytosis).<sup>1</sup> Familial hemophagocytic lymphohistiocytosis is a disease seen in infants and young children and the age of onset ranges from 1 day<sup>2</sup> to 7 years,<sup>3</sup> with more than 80% of cases presenting before age 2 years. It is usually fatal, with extensive brain involvement. Viral-associated hemophagocytic syndrome can occur in any age group, but is rare and patients usually recover. Diagnostic guidelines<sup>1</sup> for hemophagocytic lymphohistiocytosis are fever ( $>7$  days,  $>38.5^{\circ}\text{C}$ ), splenomegaly ( $>3$  cm), cytopenia ( $>2$  or 3 lineages in the peripheral blood and unassociated with a hypocellular or dysplastic marrow), hypertriglyceridemia [ $>2$  mmol/L], and hypofibrinogenemia [ $<1.5$  g/L]). Pathologically, hemophagocytic lymphohistiocytosis is in bone marrow, spleen, or lymph nodes with no evidence of malignancy. Histiocytes have morphologic immunophenotypic and ultrastructural features of normal sinus histiocytes<sup>4</sup> and show prominent erythrophagocytosis. Clinically, patients with FHL present with fever, hepatosplenomegaly, pancytopenia, abnormal liver function test results, coagulopathies, and hypertriglyceridemia. Thirty percent of cases have shown neurologic abnormalities such as alteration of the level of consciousness, nuchal rigidity, seizures, and hemiparesis.<sup>5-7</sup> Major changes were meningeal, perivascular, and intraparenchymal lymphohistiocytic infiltrates.<sup>8</sup> Erythrophagocytosis was a variable finding.

The pathogenesis of FHL remains uncertain. Multiple immune defects have been reported in FHL.<sup>9-11</sup> These are impaired natural killer cell activity, decreased T-lymphocyte response to mitogens, impaired monocyte-mediated, antibody-dependent cellular cytotoxicity, impaired interleukin 1 and interferon production, and an abnormal interleukin 2–interleukin 2 receptor system. A defect in immunomodulation results in an unrestricted release of inflammatory cytokines.

Differential diagnosis of FHL includes VAHS that was first associated with viral infection, but may also occur with bacterial, fungal, and parasitic infections or with an immunodeficiency. The accelerated phase of Chédiak-Steinbrinck-Higashi syndrome may also mimic FHL and VAHS. This suggests that these 3 disorders associated with immunodeficiency may all share the common pathway of an abnormal immune response to a stimulus, resulting in marked unregulated histiocytic activation.

Familial hemophagocytic lymphohistiocytosis is a rapidly fatal disorder. All temporary treatment protocols for FHL that are successful have employed epipodophyllotoxin with additional intrathecal methotrexate and cranial irradiation therapy.<sup>12</sup> This does not cure the disease and despite remissions lasting up to 57 months, relapses have eventually occurred in most patients.<sup>13</sup> Bone marrow transplantation may be a potential treatment for this disorder, as it could possibly correct the underlying immune defect.<sup>10,14</sup>

Accepted for publication October 1, 1998.

Corresponding author: R. K. Vasishta, MD, MRC-Path, Department of Histopathology, Postgraduate Institute of Medical Education and Research, Chandigarh 160012, India.

## REFERENCES

1. Henter J, Elinder G, Ost A. Diagnostic guidelines for hemophagocytic lymphohistiocytosis. *Semin Oncol.* 1991;18:29-33.
2. Goldberg J, Nezelof C. Lymphohistiocytosis. *Hematol Oncol.* 1986;4:275-289.
3. Nelson P, Santa Maria A, Olson RL, et al. Generalized lymphohistiocytic infiltration. *Pediatrics.* 1961;27:931-950.
4. Wiecek R, Alba Greco M, McCarthy K, et al. Familial erythrophagocytic lymphohistiocytosis: immunophenotypic, immunohistochemical and ultrastructural demonstration of the relation to sinus histiocytes. *Hum Pathol.* 1986;17:55-63.
5. Perry MC, Harrison EG, Burgert EO, et al. Familial erythrophagocytic lymphohistiocytosis. *Cancer.* 1976;38:209-218.
6. Neff JC, Senhauser DA. Familial hemophagocytic reticulosis [abstract]. *Am J Clin Pathol.* 1967;47:360-361.
7. Bell RJM, Brafield AJE, Barnes ND, et al. Familial haemophagocytic reticulosis. *Arch Dis Child.* 199;43:601-606.
8. Akima M, Sumi SM. Neuropathology of familial erythrophagocytic lymphohistiocytosis: six cases and review of the literature. *Hum Pathol.* 1984;15:161-168.
9. Ladisch S, Poplack DG, Holiman B, et al. Immunodeficiency in familial erythrophagocytic lymphohistiocytosis. *Lancet.* 1978;1:581-583.
10. Kataoka Y, Todo S, Morioka Y, et al. Impaired natural killer activity and expression of interleukin-2 receptor antigen in familial erythrophagocytic lymphohistiocytosis. *Cancer.* 1990;65:1937-1941.
11. Mvclain K, Gehr R, Grierson H, et al. Virus associated histiocytic proliferations in children: frequent association with Epstein-Barr virus and congenital or acquired immunodeficiencies. *Am J Pediatr Hemato Oncol.* 1988;10:196-205.
12. Fischer A, Virelizier JL, Arenzana-Seisdedos F, et al. Treatment of four patients with erythrophagocytic lymphohistiocytosis by a combination of epipodophyllotoxin, steroids, intrathecal methotrexate, and cranial irradiation. *Pediatrics.* 1986;76:263-268.
13. Ware R, Friedman HS, Kinney TR, et al. Familial erythrophagocytic lymphohistiocytosis: late relapse despite continuous high-dose VP-16 chemotherapy. *Med Pediatr Oncol.* 1990;18:27-29.
14. Fischer A, Cerf-Bensussan N, Blanche S, et al. Allogeneic bone marrow transplantation for erythrophagocytic lymphohistiocytosis. *J Pediatr.* 1986;108:267-270.