

SECTION EDITOR: WALTER W. TUNNESSEN, JR, MD

Picture of the Month

Hassib Narchi, MD; Walter W. Tunnessen, Jr, MD

A 10-YEAR-OLD boy who had normal developmental milestones except for a speech delay was referred for evaluation of an asymptomatic heart murmur. His parents, who are first cousins, have 2 other healthy children.

On physical examination, the child was well nourished and without dysmorphic features. The cardiac ex-

amination revealed a grade 2/6 systolic murmur at the left lower sternal border. His peripheral pulses were equal, and the blood pressure in all 4 extremities showed no abnormalities. Findings of the remainder of the examination were unremarkable.

A chest radiograph; echocardiogram; and serum calcium, magnesium, and electrolyte measures showed no abnormalities. A representative electrocardiogram is shown in the **Figure**. An audiogram demonstrated severe sensorineural deafness in both ears.

From the Al-Hasa Specialty Services Division, Saudi Aramco-Al-Hasa Health Center, Saudi Aramco Medical Services Organization, Mubarratz, Saudi Arabia.

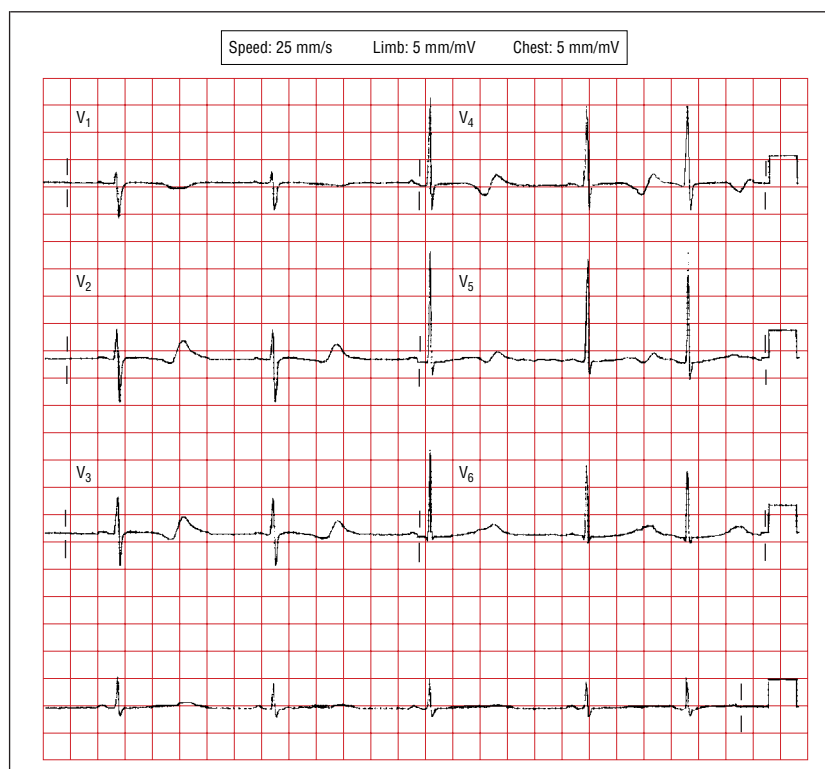


Figure.

Denouement and Discussion

Jervell and Lange-Nielsen Syndrome (Long QT Syndrome)

Figure. An electrocardiogram shows a heart rate of 53 beats/min, with a QT interval of 0.6 seconds and a corrected QT interval of 0.52 seconds.

The association of a long QT interval and congenital sensorineural deafness was described by Jervell and Lange-Nielsen¹ in 1957. The estimated incidence of this rare syndrome, with an autosomal recessive mode of inheritance, is 1.6 to 6 cases per million.² A more common form of long QT syndrome (LQTS) without congenital deafness, known as the Romano-Ward syndrome, is inherited through an autosomal dominant mode and has an estimated incidence of 1 case per 10 000 persons.³

The QT interval is prolonged in both inherited conditions, but it may be normal at rest, and variability in the interval may be found in the same individual at different times of measurement. In this disorder, the QT interval usually does not shorten appropriately with exercise. The corrected QT interval has been used to correct for heart rate (corrected QT = QT/√RR). A value greater than 0.44 seconds is considered prolonged.

Congenital prolongation of the QT interval must be differentiated from secondary forms that may occur with hypocalcemia, hypomagnesemia, hypokalemia, liquid protein fast diet, acute myocarditis, inflammation of the epicardial ganglia, and drug toxicity (tricyclic antidepressants, phenothiazines, quinidine sulfate, disopyramide phosphate, or procainamide hydrochloride).⁴

CLINICAL MANIFESTATIONS AND COMPLICATIONS

Most patients with LQTS are unaware of having the abnormality. The disorder is usually discovered by a routine electrocardiographic tracing following an evaluation for a syncopal episode, or in the evaluation of family members of individuals who have been found to have LQTS. Syncope associated with LQTS is almost always the result of a transient malignant arrhythmia, and sudden death is a frequent presentation of this disorder, usually the result of a torsade de pointes type of ventricular tachycardia. The arrhythmia may be precipitated by exercise, sudden loud noise or fright, and during anesthesia.⁵ Compelling evidence for prolonged QT interval playing a role in the sudden infant death syndrome has recently been presented.⁶

The LQTS should be considered a possibility in children with unexplained syncope, ventricular arrhythmias, sudden life-altering events, and, perhaps, nonfebrile seizures. In a prospective study of 350 congenitally deaf children, 2 (0.6%) were found to have significant prolongation of the QT interval.⁷

MOLECULAR BASIS

At least 5 genes have been shown to be involved in the pathogenesis of inherited LQTS. The genes involve chromosomes 11p15.5, 7q35-6, 3p21-24, 4q25-27, and 21.⁷ Four of these genes have been found to encode ion channel proteins, 3 involving potassium and 1 involving sodium. The cardiac ion channels play a key role in myocardial repolarization. The Romano-Ward syndrome occurs as a result of heterozygous mutations in these genes, while the Jervell and Lange-Nielsen syndrome is thought to result from a homozygous mutation of one of the genes encoding a cardiac potassium channel.^{3,4}

MANAGEMENT

Once an individual is determined to have primary LQTS, a decision must be made as to possible treatment because of the risk of sudden death. Medical treatment is indicated in any patients with prolonged QT syndrome who develop syncope or have an aborted cardiac arrest, those with congenital deafness, or those who have a family history of sudden death at a young age.⁸ Three possible therapeutic options are available to prevent life-threatening arrhythmias: β -blocking agents, pacemakers, and left cervicothoracic sympathetic ganglionectomy.⁸ Propranolol hydrochloride is the first line of therapy.

Parents and children should receive instruction regarding triggering factors of arrhythmias and should also be taught basic cardiopulmonary resuscitation. Genetic counseling should be offered to all family members, even if they are asymptomatic. Screening electrocardiograms and hearing tests should be considered.

Accepted for publication September 18, 1998.

Reprints: Hassib Narchi, MD, Al-Hasa Specialty Services Division, Saudi Aramco-Al-Hasa Health Center, Saudi Aramco Medical Services Organization, Box 6030, Mubarak 31311, Saudi Arabia.

REFERENCES

1. Jervell A, Lange-Nielsen F. Congenital deaf-mutism, functional heart disease with prolongation of Q-T interval and sudden death. *Am Heart J.* 1957;54:59-68.
2. Splawski I, Timothy KW, Vincent GM, Atkinson DL, Keating MT. Molecular basis of the long-QT syndrome associated with deafness. *N Engl J Med.* 1997;336:1562-1567.
3. Ackerman MJ, Schroeder JJ, Berry R, et al. A novel mutation in KVLQT1 is the molecular basis of inherited long QT syndrome in a near-drowning patient's family. *Pediatr Res.* 1998;44:148-153.
4. Denes P. Congenital and acquired syndrome of a long Q-T interval. *Chest.* 1977; 71:126-127.
5. Holland JJ. Cardiac arrest under anesthesia in a child with previously undiagnosed Jervell and Lange-Nielsen syndrome. *Anaesthesia.* 1993;48:149-151.
6. Schwartz PJ, Stramba-Badiale M, Segantini A, et al. Prolongation of the QT interval and the sudden infant death syndrome. *N Engl J Med.* 1998;338:1709-1714.
7. Öcal B, İmamoglu A, Atalay S, Tutar HE. Prevalence of idiopathic long QT syndrome in children with congenital deafness. *Pediatr Cardiol.* 1997;18:401-405.
8. Moss AJ, Robinson J. Clinical features of the idiopathic long QT syndrome. *Circulation.* 1992;85(suppl I):I140-I144.