

SECTION EDITOR: ENID GILBERT-BARNES, MD

## Pathological Case of the Month

Sami B. Elhassani, MD

**A**T 38 WEEKS of an uncomplicated gestation, a white male infant was born via a second cesarean section to a 26-year-old, gravida 4, para 1, white woman. The infant was the product of healthy, unrelated parents with no history of any familial diseases or major congenital anomalies. The birth weight of the infant was 3370 g and the Apgar scores were 9/9 at 1 and

5 minutes, respectively. The only abnormal physical findings were the several skin lesions on the abdomen, back, and the lower extremities (**Figure 1**). Results of skin biopsy specimen are also shown (**Figure 2**).

*From the Department of Neonatology, Mary Black Memorial Hospital, Spartanburg, SC.*

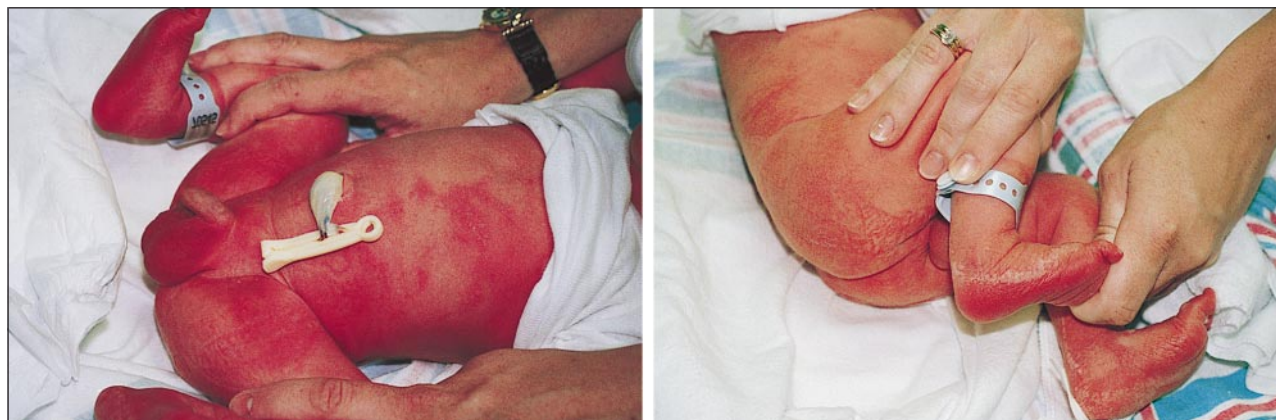

Figure 1.

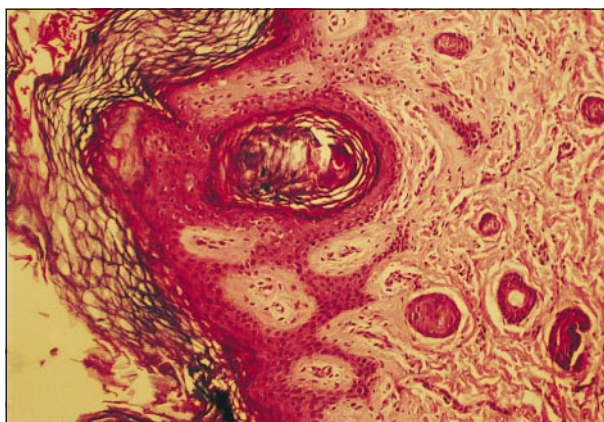


Figure 2.

# Diagnosis and Discussion

## Epidermal Nevi

**Figure 1.** Left, Erythematous rash with a distinctive pattern of whorls and streaks on the abdomen and upper part of the lower extremities. Right, A linear hypopigmented verrucous lesion on the lateral border of the right foot. Note the erythema on the soles of both feet.

**Figure 2.** A microscopic view of the verrucous linear lesion showing benign papillary epidermal hyperplasia with hyperkeratosis and acanthosis. Note the large keratin plug (hematoxylin-eosin, original magnification  $\times 40$ ).

**E**pidermal nevi are benign congenital hamartomas derived from the embryonal ectoderm and characterized by circumscribed warty hyperkeratotic plaques and hypertrophy of the epidermis. Most commonly, epidermal nevi present at birth as multiple lesions on the trunk or limbs, and usually are arranged in a linear or nevoid distribution following cutaneous lines of morphogenesis (ie, the lines of Blaschko).<sup>1</sup> Clinically, the nevi may be deeply or slightly pigmented and distributed either unilaterally or bilaterally. Affecting both sexes equally and sporadically, the lesions do not seem to be genetically transmitted.

The clinical and histopathologic classification of epidermal nevi depends on the predominant epidermal component(s) involved, such as whether the lesion is composed primarily of keratinocytes, hair follicle elements, sweat glands, or sebaceous glands.<sup>2</sup> Thus, various specific descriptive terms exist, such as "nevus verrucosus," usually present at birth as a solitary hyperpigmented warty growth composed of keratinocytic elements with a tendency to become darker and more verrucous with time. When the scalp, face, or trunk is involved, adnexal tissues such as the sebaceous glands may be affected and the condition is termed "linear nevus sebaceous." Nevi composed of dilated follicles are termed "nevus comedonicus." Histologically, the predominant features of epidermal nevi are hyperkeratosis, papillomatosis, and acanthosis.

Because some large epidermal nevi may be associated with anomalies of musculoskeletal, nervous, ocular, and cardiovascular systems (epidermal nevus syndrome), a careful family history, a thorough physical

evaluation, and a long-term follow-up of patients with the lesions are advisable.

Malignant change in epidermal nevi is a rare occurrence, and when it occurs, it usually consists of a benign or low-grade malignant tumor, such as Bowen disease keratoacanthoma, and basal or squamous cell carcinoma.<sup>3</sup>

Treatment depends on the extent of the lesions, age of the patient, associated anomalies, and when malignant changes are suspected. The treatment of choice is surgical excision of the lesions.

Accepted for publication August 24, 1998.

Reprints: Sami B. Elhassani, MD, 100 Willow Ln, Spartanburg, SC 29307.

### REFERENCES

1. Jackson R. The lines of Blaschko: a review of reconsideration. *Br J Dermatol.* 1976;95:349.
2. Happle R. Epidermal nevus syndromes. *Semin Dermatol.* 1995;14:111-121.
3. Horn MS, Sousker WF, Pierson DL. Basal cell epithelioma arising in a linear epidermal nevus. *Arch Dermatol.* 1981;117:247.

### Submissions

The Editors welcome contributions to Pathological Case of the Month, Picture of the Month, and Radiological Case of the Month. Those who wish to contribute should send their manuscripts to Dr Gilbert-Barness (Pathological Case of the Month), Department of Pathology, Tampa General Hospital, University of South Florida, Davis Island, Tampa, FL 33606; Dr Tunnessen (Picture of the Month), The American Board of Pediatrics, 111 Silver Cedar Ct, Chapel Hill, NC 27514-1651; or Dr Wood (Radiological Case of the Month), Department of Radiology, Childrens Hospital Los Angeles, 4650 Sunset Blvd, Los Angeles, CA 90027. Articles and photographs accepted for publication will bear the contributor's name. There is no charge for reproduction and printing of color illustrations.