

SECTION EDITOR: BEVERLY P. WOOD, MD

Radiological Case of the Month

Kathleen G. Reichard, DO; Jacqueline Weingarten-Arams, MD

A HEALTHY 21-month-old boy presented with a 4-day history of cough and a 2-day history of fever. His medical history was significant for being a seronegative 32-week term gestational product of a human immunodeficiency virus–positive mother, and for 1 hospitalization for gastroenteritis. During the course of his illness he had decreased oral intake and was ob-

From the Division of Pediatric Emergency Medicine (Dr Reichard), and the Division of Pediatric Critical Care Medicine (Dr Weingarten-Arams), The Children's Medical Center at Montefiore, Albert Einstein College of Medicine, Yeshiva University, Bronx, NY.

served to grab his throat and complain of pain, while playing with his toys and sucking on a pacifier. Physical examination findings showed his temperature was 35°C; heart rate, 100 beats per minute; respiratory rate, 28/min; and oxygen saturation rate, 100% while breathing room air. Examination of the lungs showed no stridor or wheezing, but he had hoarseness on vocalization. His neck was supple, with small, shotty, palpable lymphadenopathy, and his pharynx was mildly erythematous. Laboratory studies disclosed the following values: white blood cells, $4.3 \times 10^9/L$ with a normal differential cell count. A radiograph of the lateral aspect of the neck (**Figure 1**) and laryngoscopic examination were performed (**Figure 2**).

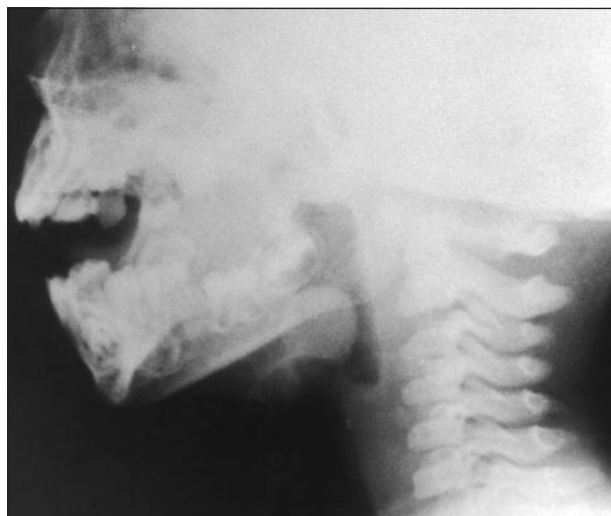

Figure 1.

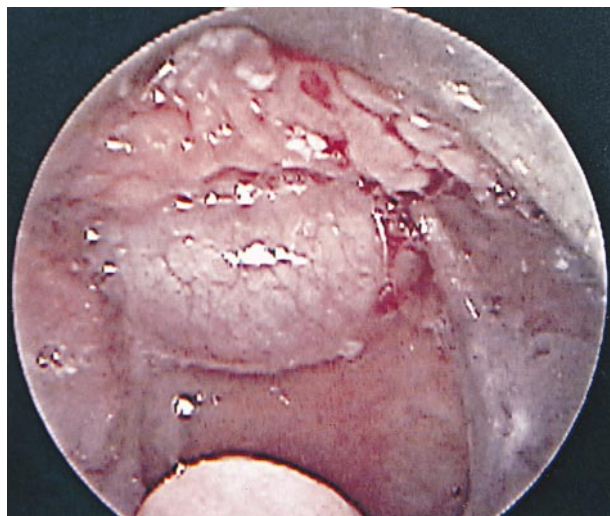


Figure 2.

Denouement and Discussion

Epiglottic Cyst

Figure 1. A rounded, smooth enlargement of the epiglottis. The remaining supraglottic, glottic, and infraglottic soft tissues are normal. The aryepiglottic folds are thin and concave.

Figure 2. The lingual surface of the epiglottis reveals a 1-cm epiglottic cyst.

As surgical treatment, an incision was made on the lingual surface of the epiglottis and a 1-cm cyst was removed. The cyst at excision was punctured, a large amount of mucoid material was suctioned, and the remaining mucosa of the cyst was excised. The patient received intravenous antibiotics and corticosteroids and was extubated 24 hours later without any respiratory compromise. At that time, indirect laryngoscopy showed the epiglottis decreased in size and wound healing progressing. He was observed for 24 hours and was discharged from the hospital without any sequelae. The pathologic specimen was a 1.2×0.8×0.3-cm epiglottic cyst, with no epithelial lining to allow further classification.

The causes of laryngeal voice disorders are categorized into 2 general groups: congenital or acquired structural abnormalities and neuromuscular functional problems.¹ DeSanto et al² reviewed 20 years of laryngeal cyst cases at the Mayo Clinic, Rochester, Minn. Laryngeal cysts are believed to occur from mucous gland duct obstruction and glandular dilatation.³ Most cases were detected in the sixth decade of life; a laryngeal cyst is a rare finding in a child. Unlike our patient, almost two thirds of the patients described were asymptomatic. The 238 cysts were classified as saccular or ductal, with a rare case that was classified as a thyroid cartilage foraminal cyst. There were 67 cysts located at the epiglottis and all were classified as ductal. These epiglottic cysts were found in the vallecula or on the lingual surface of the epiglottis. Symptoms vary with cyst size, patient age, and airway extension.³ In adults the asymptomatic cysts were identified during routine dental examination or while inducing anesthesia for surgery. Macneil et al⁴ described a 62-year-old patient with

epiglottitis and a previously asymptomatic epiglottic cyst. As children have narrower airways, they usually present with some form of respiratory distress, such as stridor. Conway et al⁵ describe a 6-week-old girl who exhibited stridor, a hoarse cry, and mild respiratory distress. At surgery she had a 2×2×1.5-cm epiglottic cyst that was removed from the epiglottis, vallecula, and the base of the tongue.

Evaluation of a suspected structural laryngeal disorder begins with radiographs of the neck in the lateral view, then computed tomographic scan or laryngoscopy. The surgical management of a laryngeal cyst can include aspiration, marsupialization, or laser treatment. Since the introduction of *Haemophilus influenzae* type b vaccine, the incidence of infectious epiglottitis has sharply declined in children.⁶ This case demonstrates the continued importance of diseases of the epiglottis in airway compromise of children.

Accepted for publication October 24, 1997.

Reprints: Jacqueline Weingarten-Arams, MD, The Children's Medical Center at Montefiore, Division of Pediatric Critical Care NW-556, 111 E 210th St, Bronx, NY 10467.

REFERENCES

1. Sobol SM, Alleva M. Hoarseness and voice change. In: Lucente FE, Sobol SM, eds. *Essentials of Otolaryngology*. 2nd ed. New York, NY: Raven Press; 1988: 266-277.
2. DeSanto LW, Devine KD, Weiland WH. Cysts of the larynx—classification. *Laryngoscope*. 1970;80:145-176.
3. Henderson LT, Denny JC, Teichgraber J. Airway-obstructing epiglottic cyst. *Ann Otol Rhinol Laryngol*. 1985;94:473-476.
4. Macneil A, Campbell AM, Clark U. Adult acute epiglottitis in association with infection of an epiglottic cyst. *Anaesth Intensive Care*. 1989;17:211-212.
5. Conway EE Jr, Bye MR, Wirtshafer K, Gereau S, Basilla M. Epiglottic cyst: an unusual cause of stridor in an infant. *Pediatr Emerg Care*. 1991;7:85-86.
6. American Academy of Pediatrics. *Haemophilus influenzae* infections. In: 1997 *Red Book: Report of the Committee on Infectious Diseases*. 24th ed. Elk Grove Village, Ill: American Academy of Pediatrics; 1997:221.