

SECTION EDITOR: BEVERLY P. WOOD, MD

## Radiological Case of the Month

Tom N. Hilliard, MRCP; Michael J. Marsh, MRCP; Paul Malcolm, FRCR;  
Ian A. Murdoch, MRCP; Beverly P. Wood, MD

**A** 7-DAY-OLD boy presented with a 1-day history of poor breast-feeding. He was alert, with cold extremities, reduced skin turgor (**Figure 1**), dry mucous membranes, and a sunken anterior fontanelle. His weight was 2.66 kg, representing a loss of 25% from birth. The plasma sodium level was 174 mmol/L; urea nitrogen, 40 mmol/L (112 mg/dL); creatinine 111  $\mu$ mol/L (1.25 mg/dL); leukocyte count,  $12.3 \times 10^9/L$ ; and fibrinogen, 0.98 g/L (reference range, 1.5-4.5 g/L).

A blood culture was performed prior to administration of intravenous broad spectrum antibiotics. He was treated with intravenous fluids containing 40-mmol/L sodium, at 275 mL/kg per day. Ten hours after admission, his plasma sodium level had fallen to 156 mmol/L and 4 hours later the neonate had 2 brief generalized seizures. Rectal diazepam, intravenous mannitol, and phenytoin were given. He became apneic and required tracheal intubation, mechanical ventilation, and was transferred to the pediatric intensive care unit.

Renal diagnostic ultrasound showed no abnormalities. A cranial sonogram showed effacement of the subarachnoid spaces indicating moderate cerebral edema. An unenhanced computed tomogram (CT) of the brain also demonstrated cerebral edema, and high density and enlargement of the superior sagittal sinus with sparing of

the anterior portion (**Figure 2**). A diagnosis of acute sagittal sinus thrombosis was made. A subsequent color Doppler sonogram also demonstrated absence of flow in the superior sagittal sinus, except in the anterior portion. The sagittal sinus with color flow signal in adjacent cortical arteries is shown (**Figure 3**).

Intravenous fluids with 140-mmol/L sodium were given during a 72-hour period to correct dehydration. He was treated with ventilatory support and intravenous antibiotics for 2 days. One day after admission, the urinary sodium level was 50 mmol/L and urinary osmolality was 723 mmol/kg. His mother expressed very small volumes of breast milk, with a sodium content of 16 mmol/L. The plasma sodium approached more normal levels during the next 4 days, as progressively more hypotonic fluids and enteral feedings were given.

From the Pediatric Intensive Care Unit (Drs Hilliard and Marsh), and the Department of Radiology (Drs Malcolm and Murdoch), Guy's Hospital, London, England; and the Department of Radiology, Children's Hospital Los Angeles, Los Angeles, Calif (Dr Wood).

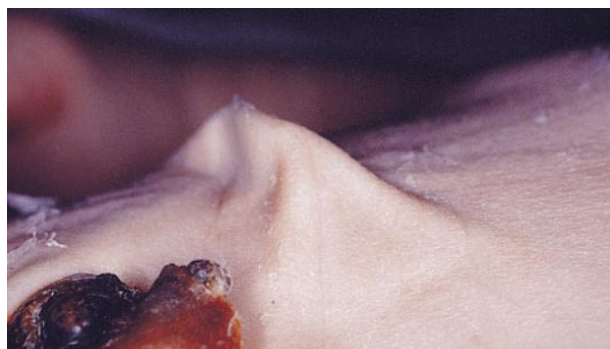


Figure 1.

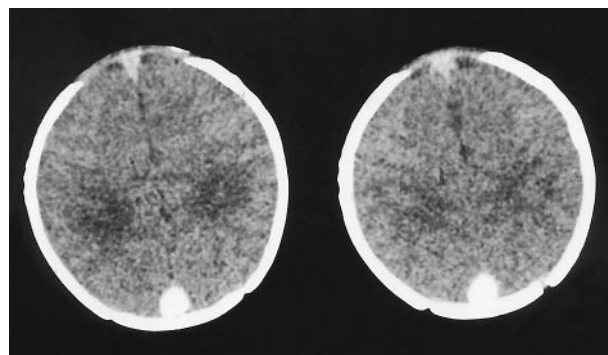


Figure 2.

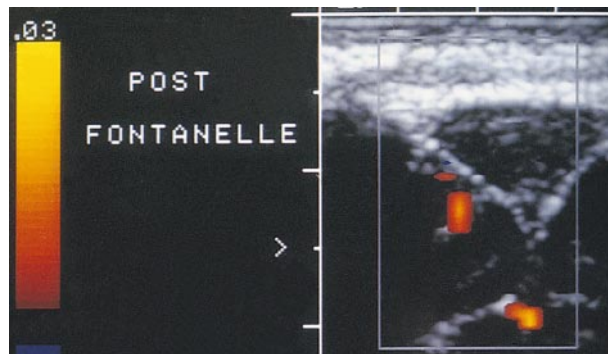


Figure 3.

# Denouement and Discussion

## Sagittal Sinus Thrombosis in Hypernatremic Dehydration

**Figure 1.** View of the anterior abdominal wall showing reduced skin turgor.

**Figure 2.** Axial unenhanced computed tomographic scan showing high density in the enlarged superior sagittal sinus characteristic of thrombosis. The anterior portion of the sinus is spared.

**Figure 3.** Color Doppler ultrasonograms demonstrate absence of flow in the superior sagittal sinus. There is color flow signal in the adjacent cortical arteries.

The clinical presentation of this neonate is similar to other reports of breast-fed infants with hypernatremic dehydration.<sup>1</sup> The mother's inability to express significant volumes of breast milk, and the milk's abnormal sodium content implicate insufficient lactation as the underlying problem. Neonatal hypernatremia is associated with significant neurological morbidity.<sup>2</sup> It is generally accepted that rehydration in hypernatremic dehydration should be performed slowly, decreasing the plasma sodium level by 0.5 to 1 mmol/L per hour, as a more rapid decrease may cause cerebral edema. This neonate had experienced a rapid reduction in plasma sodium concentration, which may have contributed to the onset of seizures. Sagittal sinus thrombosis may have been present prior to admission, as suggested by the low fibrinogen level and platelet count.

The association between dehydration and renal vein thrombosis is better recognized than that with dural sinus thrombosis. Sinus thrombosis was reported as early as 1931 in postmortem studies of infants.<sup>3</sup> There have been few clinical reports until the last decade, the largest series a review of 17 full-term neonates with dural sinus thrombosis diagnosed on CT scan.<sup>4</sup> Of this group, 15 patients presented with seizures, predominantly in the first week of life and 3 patients had an apparent predisposing condition (2 patients with polycythemia, 1 patient with congenital cyanotic heart disease). Only 3 infants had seizure recurrence after treatment, and of 13 infants with no history of perinatal asphyxia, 12 had a normal neurodevelopmental outcome.

Superior sagittal sinus thrombosis may be demonstrated by various modalities including carotid angiography, CT, magnetic resonance imaging, and color Dop-

pler ultrasonography. The appearance of high density within the sinus on unenhanced CT is a recognized appearance of acute thrombosis,<sup>4</sup> and is particularly striking in this case. A filling defect within the sinus, the "delta sign," may also be seen on the unenhanced scan. Thrombosis is better recognized on enhanced CT. Color Doppler ultrasonograms is a useful diagnostic method, though CT or magnetic resonance imaging scans provide more complete information regarding the deep cerebral venous system.<sup>5</sup>

Therapeutic use of heparin anticoagulation and instillation of fibrinolytic agents into the cerebral dural sinuses has been reported for therapy in infants, with apparent safety, and reestablished venous sinus drainage.<sup>6</sup> Since the outcome of neonates with dural sinus thrombosis alone being generally excellent, this treatment is not justified.

We conclude that neonatal dural sinus thrombosis is an increasingly reported phenomenon, and cranial imaging, including color Doppler ultrasonography, should be considered in neonates with severe dehydration or seizures.

Accepted for publication October 24, 1997.

Reprints: Michael J. Marsh, MRCP, Pediatric Intensive Care Unit, Guy's Hospital, St Thomas' Street, London SE1 9RT, England (e-mail: m.marsh@umds.ac.uk).

### REFERENCES

1. Molten KH. Initial management of hypernatraemic dehydration in the breast-fed infant. *Clin Pediatr (Phila)*. 1994;33:731-740.
2. Macaulay D, Watson M. Hypernatraemia in infants as a cause of brain damage. *Arch Dis Child*. 1967;43:485-491.
3. Baily OT, Hass GM. Dural sinus thrombosis in early life: the clinical manifestations and extent of brain injury in acute sinus thrombosis. *J Pediatr*. 1931;11:755-771.
4. Shevell MI, Silver K, O'Gorman AM, Watters GV, Montes JL. Neonatal dural sinus thrombosis. *Pediatr Neurol*. 1989;5:161-165.
5. Lam AH. Doppler imaging of superior sagittal sinus thrombosis. *J Ultrasound Med*. 1995;14:41-46.
6. Horowitz M, Purdy P, Unwin H, et al. Treatment of dural sinus thrombosis using selective catheterization and urokinase. *Ann Neurol*. 1995;38:58-67.