

SECTION EDITOR: ENID GILBERT-BARNES, MD

Pathological Case of the Month

Nasir Shaikh, MD; Mouied Alashari, MD

A 16-YEAR-OLD girl was referred to a pediatric surgeon with complaints of bloody diarrhea and abdominal pain for the past 3 days. She developed cramping abdominal pain and initially watery diarrhea after having eaten at a fast-food restaurant 3 days prior to

hospital admission. Physical examination revealed peri-umbilical epigastric tenderness. There was no history of fever or any other urinary tract symptoms. Computed tomographic scan revealed ileocolic intussusception with a mass in the cecum (**Figure 1**). She underwent limited right colectomy (**Figure 2** and **Figure 3**).

From the Department of Pathology, Children's Hospital of Buffalo, Buffalo, NY.

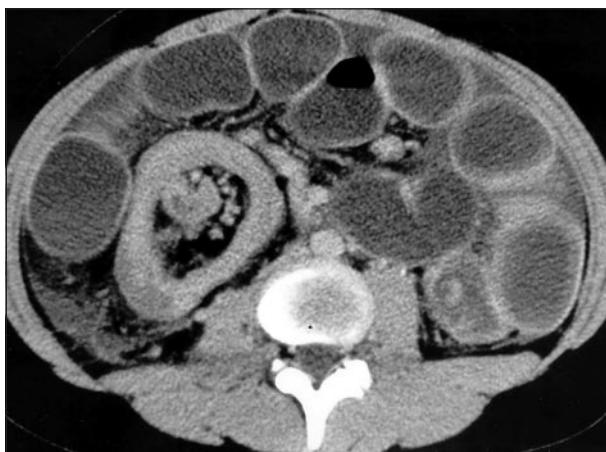

Figure 1.

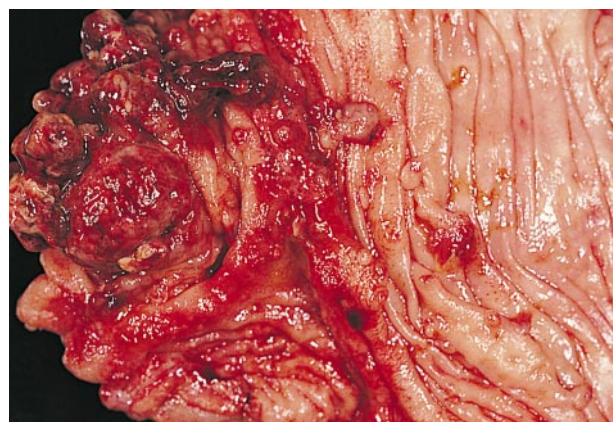


Figure 2.

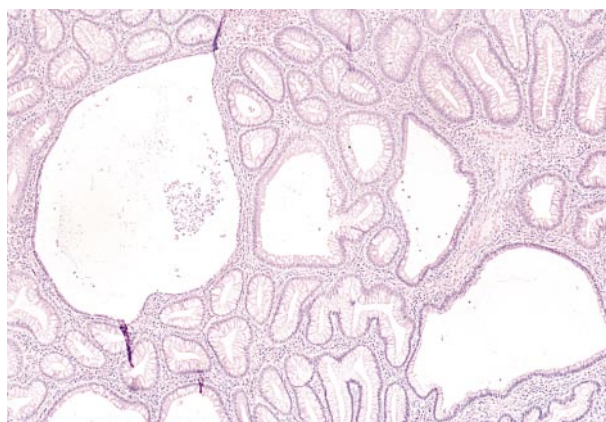


Figure 3.

Diagnosis and Discussion

Juvenile Polyposis Coli

Figure 1. Computed tomographic scan of abdomen showing mass in the cecum with distended proximal bowel.

Figure 2. Gross photograph of the specimen showing multiple pedunculated polyps in the cecum and ascending colon.

Figure 3. Microscopic photograph of a polyp showing cystically dilated crypts filled with mucus and inflammatory cells. There is abundant granulation tissue and inflammatory exudate composed of plasma cells, polymorphonuclear leukocytes, and histiocytes in the stroma (hematoxylin-eosin, original magnification $\times 100$).

JUVENILE POLYPS are the most common type of gastrointestinal polypoid lesions in childhood.¹⁻³ Most of them are solitary and confined to the rectosigmoid region. Juvenile polyps have been described as retention polyps or inflammatory polyps, and are routinely grouped with hamartomas in the literature.⁴ Juvenile polyposis syndrome is characterized by numerous polyps throughout the colon (juvenile polyposis coli)⁵ or the entire gastrointestinal tract (generalized juvenile polyposis)⁶ and presents with rectal bleeding, abdominal pain, and intussusception. Jass et al⁷ have suggested a working diagnostic criteria for juvenile polyposis syndrome that includes one of the following: (1) more than 5 juvenile polyps of the colon or rectum, (2) juvenile polyps throughout the gastrointestinal tract, or (3) any number of juvenile polyps with a family history of juvenile polyposis.

Goodman et al⁸ have suggested that juvenile polyps represent one step in a spectrum, beginning with hyperplasia, progressing to typical juvenile polyps that then develop adenomatous changes, and progressing eventually to a true adenoma. Familial juvenile polyposis is one of the inherited polyposis syndromes associated with a predisposition to gastrointestinal tract malignant neoplasms.⁹ It is inherited as an autosomal dominant trait, but no specific genetic defect has been identified. The risk of colon cancer is increased, although the magnitude of the increased risk is controversial.¹⁰

Once a diagnosis of juvenile polyposis syndrome is established, the entire gastrointestinal tract must be pe-

riodically examined by upper and lower endoscopy because of the increased risk of recurrence and subsequent development of a carcinoma.¹¹ Only prolonged observation will allow accurate assessment of the neoplastic potential of these lesions. Genetic studies may enlighten us further as to the nature of this condition and in particular its relationship to adenomatous polyposis coli.¹² No guidelines have been suggested on the indications for prophylactic colectomy.¹²

REFERENCES

1. Harrilleno EG, Eckert C, Ackerman LV. Polyps of the rectum and colon in children. *Cancer*. 1957;10:1210-1220.
2. Mauro J, Prior JT. Gastrointestinal polypoid lesions in childhood. *Cancer*. 1957; 10:131-137.
3. Louw JH. Polypoid lesions of the large bowel in children. *S Afr Med J*. 1972;46: 1347-1352.
4. Heiss KF, Schaffner D, Ricketts RR, Winn K. Malignant risk in juvenile polyposis coli: increasing documentation in the pediatric age group. *J Pediatr Surg*. 1993; 28:1188-1193.
5. Grotsky HW, Rickett RR, Smith WD, Newsome JF. Familial juvenile polyposis coli: a clinical and pathologic study of a large kindred. *Gastroenterology*. 1982; 82:495-501.
6. Kent TH, Mitros FA. Polyps of the colon and small bowel, polyps syndrome, and the polyp cancer sequence. In: Norris HT, ed. *Pathology of the Colon, Small Intestine, and Anus*. New York, NY: Churchill-Livingstone; 1983:167-199. *Contemporary Issues in Pathology*; vol 2.
7. Jass JR, Williams CB, Bussey JHR, et al. Juvenile polyposis: a precancerous condition. *Histopathology*. 1988;13:619-630.
8. Goodman ZD, Yardley JH, Milligan FD. Pathogenesis of colonic polyps in multiple juvenile polyposis: report of a case associated with gastric polyps and carcinoma of the rectum. *Cancer*. 1979;43:1906-1913.
9. Burt RW, Bishop DT, Lynch HT, Rozen P, Winawer SJ, and the WHO Collaborating Centre for the Prevention of Colorectal Cancer. Risk and surveillance of individuals with heritable factors for colorectal cancer. *Bull World Health Org*. 1990;68:655-665.
10. Leggett BA, Thomas LR, Knight N, Healey S, Chenevix-Trench G, Searle J. Exclusion of APC and MCC as the gene defect in one family with familial juvenile polyposis. *Gastrointest Endosc*. 1995;42:560-564.
11. Rodriguez-Bigas MA, Penetrante RB, Herrera L, Petrelli NJ. Intraoperative small-bowel enteroscopy in familial adenomatous and familial juvenile polyposis. *Gastrointest Endosc*. 1995;42:560-564.
12. O'Riordan DS, O'Dwyer PJ, Cullen AF, McDermott EW, Murphy JJ. Familial juvenile polyposis coli and colorectal cancer. *Cancer*. 1991;68:889-892.