

SECTION EDITOR: BEVERLY P. WOOD, MD

## Radiological Case of the Month

Mitchell Weiss, MD; David M. Danoff, MD; Beverly P. Wood, MD

**A** 9-YEAR-OLD girl presented with a 2-week history of considerable abdominal distress. She had been experiencing intermittent, sharp abdominal pain associated with nonbilious vomiting; the initial episode of pain was accompanied by a loose bowel movement and a low-grade fever. The patient's condition had been evaluated for similar symptoms on 2 prior occasions; on 1 occasion she required intravenous hydration. Her most recent visit occurred 3 days before this presentation. Then abdominal radiographs were reported to show considerable fecal retention and enemas were prescribed. Despite 16 enemas in the past 13 days, the abdominal distress continued, often waking her at night.

Physical examination revealed an epigastric mass to the left of the midline that, when palpated, reproduced her symptoms. An abdominal radiograph showed distention of her small and large bowel, but no obstruction

or notable fecal retention. The patient was admitted to the hospital for intravenous hydration and further evaluation. The next day, radiographic studies of the abdomen (**Figure 1**) and an upper gastrointestinal series were obtained (**Figure 2**). **Figure 3** indicates the cause of the abdominal distress.

*From the Department of Radiology, Bryn Mawr Hospital, Bryn Mawr, Pa (Drs Weiss and Danoff); and the Division of Medical Education, University of Southern California Health Sciences Campus, Los Angeles (Dr Wood).*

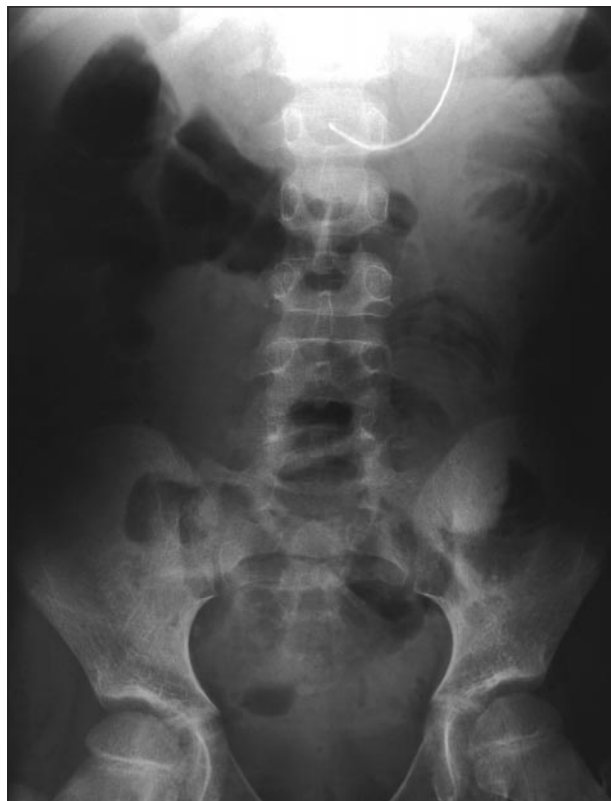

Figure 1.

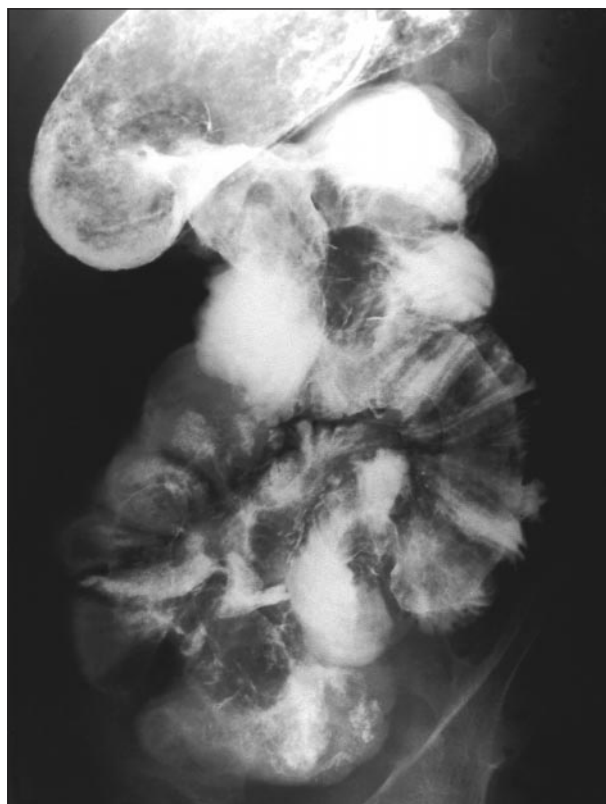


Figure 2.

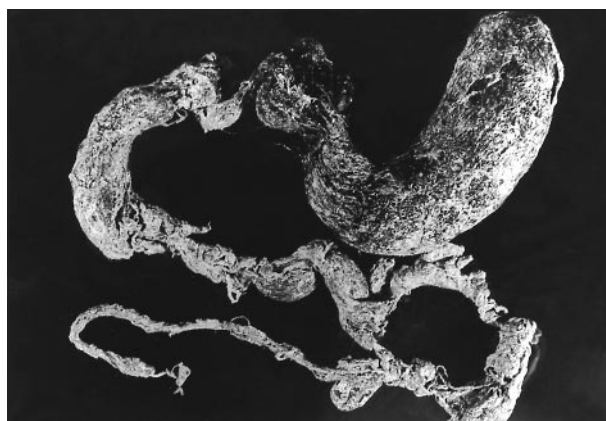


Figure 3.

# Denouement and Discussion

## Jejunojunal Intussusception Caused by a Trichobezoar With a Tail

**Figure 1.** Abdominal radiographs reveal multiple dilated loops of small bowel on the left side of the abdomen with a "coiled-spring" appearance.

**Figure 2.** Trichobezoar represented as an intraluminal filling defect in the stomach with an associated jejunojunal intussusception.

**Figure 3.** Specimen of trichobezoar with a long tail.

**B**ezoars consist of nondigestible foreign material present in the stomach or intestine and are categorized by content. Phytobezoars originate from vegetable and plant matter, trichobezoars result from the ingestion of hair, and trichophytobezoars are a collection of material from both categories but do not result from hairy fruit. Many other materials form intragastric concretions including gum, Gummi-bears (a type of chewy candy), popcorn kernels, sunflower seeds (when eaten with their shells), vitamins, aluminum hydroxide, magnesium hydroxide, bulk laxatives, sucralfate for antacid therapy, slow-release forms of nifedipine and procainamide hydrochloride, enteric-coated aspirin, and ion exchange resin.<sup>1-4</sup> There is an article reporting a bezoar formed from debris originating from a pancreatic pseudocyst following a Roux-en-Y gastrojejunostomy.<sup>5</sup> Unripened persimmons, known for the formation of phytobezoars, contain soluble tannin called "shibuol" that, on coming into contact with a weak acid, forms a gluey coagulum affixing other matter present in the stomach.<sup>6</sup>

Predisposing factors to bezoar, in addition to dietary behavior, include previous gastric surgery, particularly partial gastrectomy or truncal vagotomy with pyloroplasty.<sup>6</sup> Vagotomy decreases gastric motility allowing ingested materials more time to accumulate in the stomach; or, in the case of persimmon ingestion, a vagotomy allows more time for shibuol to come in contact with dilute hydrochloric acid. Pyloroplasty, which also alters gastric motility, may create an easier passage for fragments of a bezoar to pass into the small bowel. There is a report of a biliary phytobezoar, in which concretions of vegetable material obstructed the extrahepatic bile ducts in a patient who had a cholecystogastrostomy performed 15 years earlier.<sup>7</sup> An esophageal diverticulum may predispose to bezoar formation in the diverticulum.<sup>8</sup>

The complications from bezoar formation are mechanical and traumatic. Mechanical complications cause interference with peristalsis and the passage of intraluminal contents (ie, obstruction or ileus). Traumatic complications arise from direct irritation to gastrointestinal mucosa by the nonpliable mass and include ulceration, perforation, peritonitis, and hemorrhage.<sup>9</sup>

In a review of 311 cases by DeBakey and Ochsner,<sup>9</sup> the characteristic clinical presentation was a freely movable, firm abdominal mass, usually located in the epigastrium, and producing pain, nausea, and vomiting. Diarrhea or constipation occurred in about one third of the cases. A history of trichophagia was common in young girls who have a trichobezoar.

In this case, a history of trichophagia was eventually elicited. The radiographic and surgical pathologic findings showed a bezoar that formed a near-perfect cast of the stomach and duodenal cap (Figure 3). From the duodenal cap, the bezoar formed a tail that extended several centimeters into the jejunum. The tail contained many regions of clumped hair, giving it a beaded texture. Two other cases have been reported in which the bezoar extended into the small bowel forming a string or tail.<sup>10,11</sup> The operative findings indicated that the bezoar was the lead point for a small-bowel intussusception. It is likely that 1 of the terminal beaded areas created the nidus for the intussusception. The tail was reduced retrogradely to the gastrotomy site and then removed. The patient's recovery was complicated by transient symptoms of partial small-bowel obstruction, possibly related to colonic barium impaction. She was discharged from the hospital 13 days after her surgery.

Accepted for publication February 20, 1997.

Reprints: Mitchell Weiss, MD, Bryn Mawr Hospital, Department of Radiology, 130 S Bryn Mawr Ave, Bryn Mawr, PA 19010.

### REFERENCES

1. Silbergleit R, Lee DC. Bowel obstruction and radiopaque vitamin B<sub>12</sub> "pseudo-bezoar." *Am J Emerg Med.* 1995;13:112-113.
2. Sussman S, Goldberg RP, Glotzer DJ. Aluminum hydroxide gel bezoar—CT diagnosis. *J Can Assoc Radiol.* 1985;36:148-149.
3. Kaplan M, Ozeri Y, Agranat A, Brisk R, Eylath U. Antacid bezoar in a premature infant. *Am J Perinatol.* 1995;12:98-99.
4. Bogacz K, Caldron P. Enteric-coated aspirin bezoar: elevation of serum salicylate level by barium study. *Am J Med.* 1987;83:783-786.
5. Katras T, Stein M. Mechanical intestinal obstruction from pseudocyst bezoar following internal drainage of a traumatic pancreatic pseudocyst. *J Trauma.* 1988;28:406-407.
6. Verstanding AG, Bauch K, Bloom R, Hadas I, Libson E. Small-bowel phytobezoars: detection with radiography. *Radiology.* 1989;172:705-707.
7. Lamotte M, Kockx M, Hautekeete M, Holvoet J, Hubens H. Biliary phytobezoar: a medical curiosity. *Am J Gastroenterol.* 1995;90:1345-1348.
8. Tolliver BA, DiPalma JA. Zenker's bezoar. *South Med J.* 1995;88:751-752.
9. DeBakey M, Ochsner A. Bezoars and concretions. *Surgery.* 1939;5:132-160.
10. Mehta M, Patel RV. Intussusception and intestinal perforations caused by multiple trichobezoars. *J Pediatr Surg.* 1992;27:1234-1235.
11. Wolfson PJ, Fabius RJ, Leibowitz AN. The Rapunzel syndrome: an unusual trichobezoar. *Am J Gastroenterol.* 1987;82:365-367.