Denouement and Discussion

Omental Infarction

Axial CT scan of the upper abdomen at the level of the kidneys revealed a triangular area of increased density in the right-sided mesentery (Figure 1). It was located between the anterior abdominal wall and the antimesenteric border of the transverse colon (Figure 2). Axial CT scan at the level of the cecum did not show the noncompressible, blind-ending tubular structure larger than 6 mm that is characteristic of appendicitis. A few small mesenteric nodes were noted (not shown), but they were neither sizable nor great enough in quantity to suggest mesenteric adenitis. No thick bowel that was indicative of inflammatory bowel disease was seen. Laparoscopy showed an inflammatory mass of necrotic omentum adhering to the anterior abdominal wall (**Figure 3**). Following surgical resection, the patient's pain lessened. These findings are consistent with omental infarction.

Omental infarction, traditionally considered to be a fairly rare cause of abdominal pain in children, is being diagnosed with increasing frequency owing to the greater availability of CT and the rising prevalence of obesity, a known risk factor.[1] Pediatric patients account for 15% of cases. Omental infarction may be idiopathic in nature or may result from omental vessel thrombosis secondary to hypercoagulability, vasculitis,[2] anomalous arterial supply, venous kinking with increased intra-abdominal pressure (eg, from trauma or unaccustomed exercise), or postprandial vascular congestion.[1] It may also be caused by torsion of bifid or accessory omenta or prominent fat deposits on the anatomically normal omenta found in obese patients.

Because the right lateral aspect of the omentum is the most mobile, it is the omental portion that is most likely to torse. Omental infarction, therefore, typically presents with right-sided abdominal pain and local peritoneal signs.[3] The presentation is otherwise variable. Fever, leukocytosis, and gastrointestinal tract symptoms (nausea, vomiting, diarrhea, and constipation) are reported inconsistently.[1-3] In children, omental infarction is nearly always clinically mistaken for appendicitis.[4]

Radiological identification of omental infarction is best made using CT. It is classically described as a heterogenous (mixed-density) soft-tissue mass that is oval or triangular in shape within an area of omental fat, positioned between the antimesenteric border of the transverse or ascending colon and the anterior abdominal muscles.[4,5] Inflammatory mesenteric stranding is frequently seen. Parietal peritoneal thickening and/or adherence, as well as mass effect on the adjacent bowel, may be present. Ultrasonography, considered insensitive and somewhat nonspecific for the diagnosis, may demonstrate a solid, hyperechoic, noncompressible mass.[1,5] It is most helpful in identifying other specific differential diagnostic possibilities, such as nonperforated appendicitis.[2] Resolution may occur spontaneously with conservative management, but an argument may be made in favor of laparoscopic excision, which speeds clinical recovery and prevents the development of complicating abscesses or bowel-obstructing adhesions.[2,3,5]

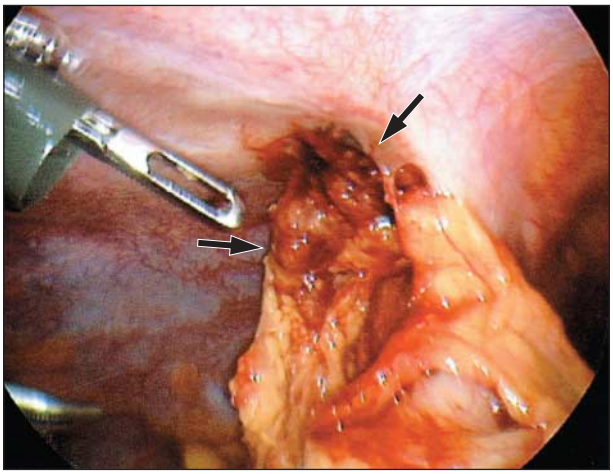

Figure 3. Surgical photograph of right upper quadrant. The inflamed, infarcted omentum (arrows) was noted to be adherent to the anterior abdominal wall, elevated on this image by laparoscopic insufflation.

Accepted for Publication: November 16, 2006.
Correspondence: Harris L. Cohen, MD, 78 Grove Ave, Cedarhurst, NY 11516-2311 (hcohenmb@optonline.net).
Author Contributions: *Study concept and design:* Hu and Cohen. *Acquisition of data:* Hu, Cohen, and Scriven. *Analysis and interpretation of data:* Cohen. *Drafting of the manuscript:* Hu. *Critical revision of the manuscript for important intellectual content:* Cohen and Scriven. *Administrative, technical, and material support:* Cohen and Scriven. *Study supervision:* Cohen and Scriven.
Financial Disclosure: None reported.

REFERENCES

1. McClure MJ, Khalili K, Sarrazin J, Hanbidge A. Radiological features of epiploic appendagitis and segmental omental infarction. *Clin Radiol.* 2001;56(10):819-827.
2. Myers MT. Segmental omental infarction. In: Cohen HL, Sivit CJ, eds. *Fetal & Pediatric Ultrasound: A Casebook Approach.* New York, NY: McGraw Hill; 2001:466-468.
3. Varjavandi V, Lessin M, Kooros K, Fusunyan R, McCauley R, Gilchrist B. Omental infarction: risk factors in children. *J Pediatr Surg.* 2003;38(2):233-235.
4. Sung T, Callahan MJ, Taylor GA. Clinical and imaging mimickers of acute appendicitis in the pediatric population. *AJR Am J Roentgenol.* 2006;186(1):67-74.
5. Grattan-Smith JD, Blews DE, Brand T. Omental infarction in pediatric patients: sonographic and CT findings. *AJR Am J Roentgenol.* 2002;178(6):1537-1539.

©2007 American Medical Association. All rights reserved.
Downloaded From: http://archpedi.jamanetwork.com/ on 04/26/2015