

Picture of the Month

Yue-Yung Hu, BS; Harris L. Cohen, MD; Richard J. Scriven, MD

A 13-YEAR-OLD GIRL PRESENTED WITH 5 DAYS of abdominal pain that originated in her right upper quadrant and progressed to her epigastrium. She denied experiencing nausea, vomiting, diarrhea, loss of appetite, fevers, or chills. She was afebrile. Her abdomen was tender to palpation in the midepigastrium, but without rebounding or guarding. White blood cell count and

lipase and liver function test results were normal. Her weight was 64.7 kg (~90th percentile for age), and her height was 158 cm (~50th percentile). **Figures 1 and 2** are images from her abdominal computed tomographic (CT) scan.

Author Affiliations: Stony Brook University School of Medicine (Ms Hu), and Department of Radiology, Division of Body Imaging (Dr Cohen), and Department of Surgery, Division of Pediatric Surgery (Dr Scriven), Stony Brook University School of Medicine, Stony Brook, New York.

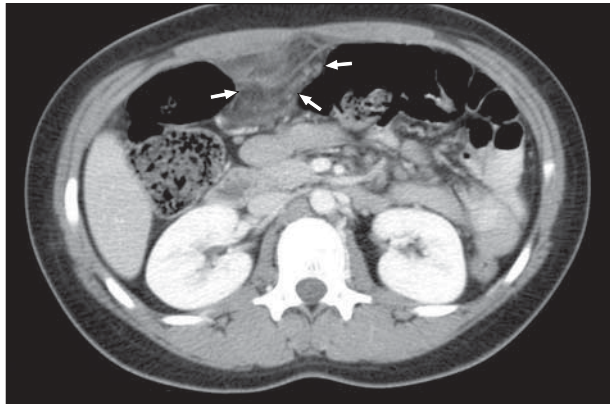

Figure 1. Axial computed tomography through the patient's upper abdomen at the level of the kidneys. Triangular area of radiodense omental fat (arrows) is seen anteriorly within the right abdomen.

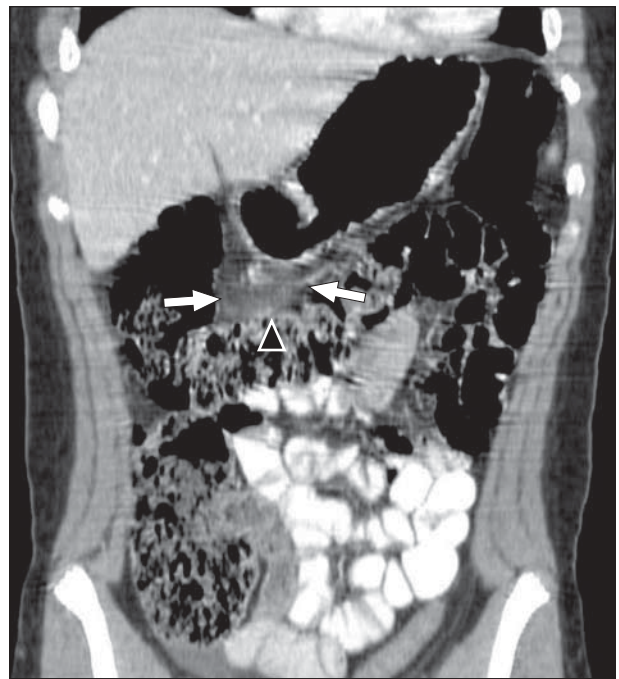


Figure 2. Two-dimensional coronal reconstruction of abdominal computed tomography. Note the position of the triangular hazy gray density (arrows) in relation to the stomach and the transverse colon (arrowhead).