

## Picture of the Month

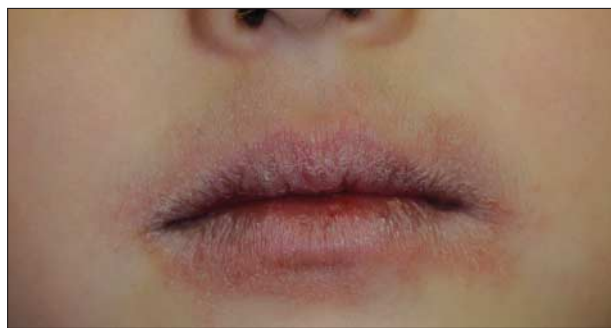Emma F. Johnson, BA; Erica G. Lau, DO; Aimee C. Smidt, MD

**A** 5-YEAR-OLD GIRL PRESENTED WITH A 2½-year history of persistently dry, itchy, tender skin around the mouth. The mother denied frequent lip licking. Treatment involved topical antibiotics, hydrocortisone cream, and lip balms, without improvement. She was afebrile and otherwise healthy. There was no family history of similar dermatologic conditions. Ex-

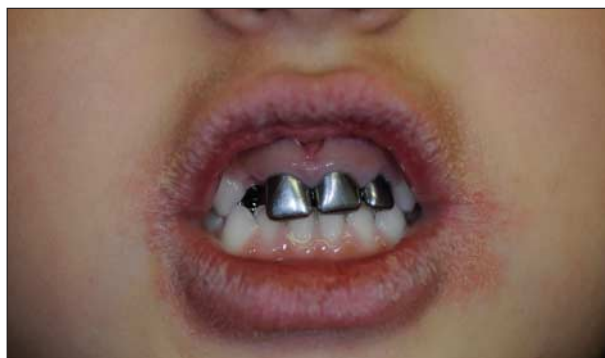amination demonstrated marked erythema and prominent scale periorally with blurring of the vermilion border (**Figure 1**). There was no warmth or drainage. Complete mucocutaneous examination revealed inflammation and edema of the upper gingival margins without ulceration. Her upper front teeth were covered with metal caps (**Figure 2**). Erythematous, scaly plaques on the bilateral earlobes were also noted (**Figure 3**).

**Author Affiliations:** Departments of Dermatology (Drs Lau and Smidt) and Pediatrics (Dr Smidt), University of New Mexico School of Medicine, Albuquerque. Ms Johnson is a medical student at the University of New Mexico School of Medicine.

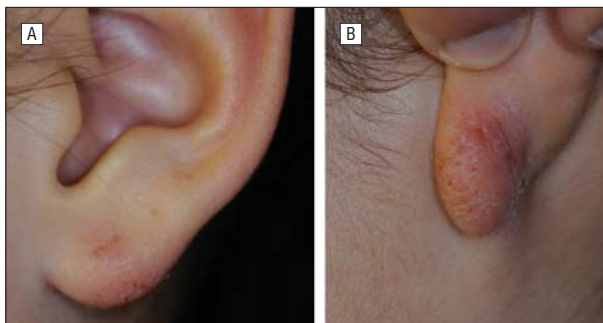
See [jamapeds.com](http://jamapeds.com) for the Picture of the Month Web Quiz: What is your diagnosis?



**Figure 1.** Well-demarcated perioral erythematous plaques with prominent scale and blurring of the vermilion border.



**Figure 2.** Upper gingival margin with inflammation and edema. Upper front teeth were covered with metal caps.



**Figure 3.** Eczematous plaques on the front (A) and back (B) of the earlobe.