Picture of the Month

Marc Tebruegge, MRCPCH, MD; Nigel Curtis, FRCPCH, PhD; David Wallace, FRACS; Mike Starr, FRACP; Penelope Bryant, MRCPCH, PhD

A PREVIOUSLY WELL 16-YEAR-OLD BOY PRESENTED to his local hospital with intermittent pyrexia, diffuse headache, and a left-sided swelling that had gradually enlarged over the previous 7 days. Two weeks earlier, his general practitioner had diagnosed sinusitis and had prescribed a combination of amoxicillin and clavulanate, administered orally, which the patient only partially completed.

Results of a physical examination revealed a large, tender, fluctuant lesion in the left parietal region of the skull. The remainder of the examination was unremarkable.

Author Affiliations: Infectious Diseases Unit, Department of General Medicine (Drs Tebruegge, Curtis, Starr, and Bryant), Department of Neurosurgery (Mr Wallace), Department of Pediatrics, The University of Melbourne (Drs Tebruegge, Curtis, and Bryant), and Murdoch Children's Research Institute (Drs Tebruegge, Curtis, and Bryant), Royal Children's Hospital Melbourne, Parkville, Victoria, Australia.

A computed tomographic scan of the head showed a large extracranial subgaleal abscess corresponding to the site of the swelling (**Figure 1**) and osteomyelitis of the underlying skull. The abscess was drained locally, and the patient was transferred to our center for further treatment.

On admission, the cranial magnetic resonance (MR) image showed mucosal swelling and opacities in his maxillary, ethmoid, and frontal sinuses bilaterally indicating pansinusitis. An unexpected abnormality was also detected (**Figure 2**).

What is your diagnosis?

See http://www.archpediatrics.org for the Picture of the Month Web Quiz: What is your diagnosis?

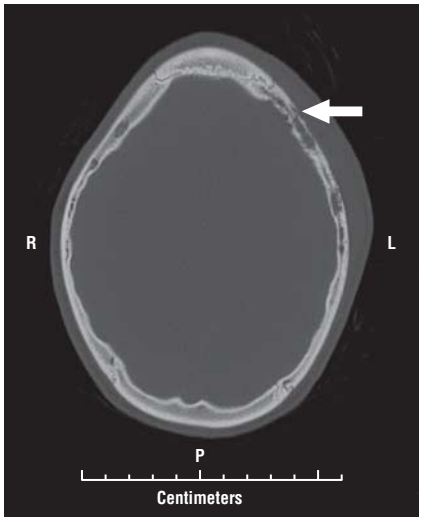

Figure 1. Cranial computed tomographic scan showing the left-sided extracranial abscess and osteolytic lesions indicative of osteomyelitis (arrow). L indicates left; P, posterior; and R, right.

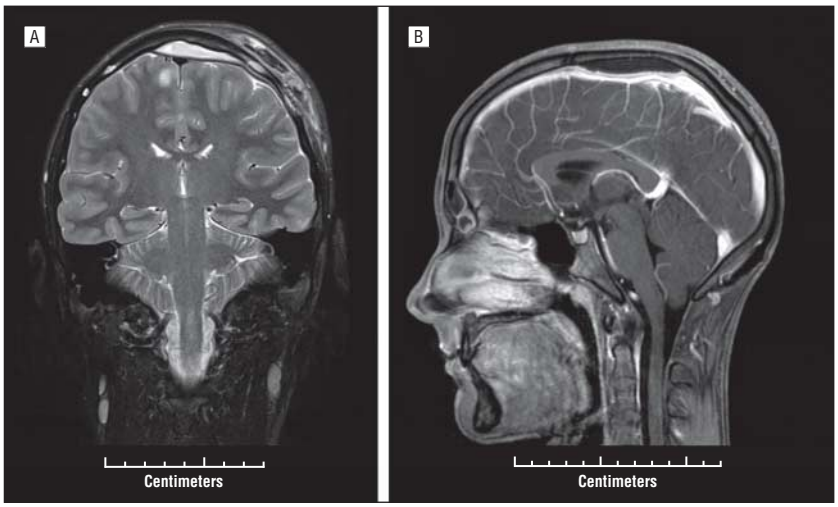

Figure 2. T2-weighted (A) and T1-weighted (B) cranial magnetic resonance images. The findings are described in detail in the "Denouement and Discussion" section.

©2010 American Medical Association. All rights reserved.

Downloaded From: http://archpedi.jamanetwork.com/ on 03/31/2015