Picture of the Month

Sunita Juliana Ferns, MD; Peter A. Noronha, MD

A 6-YEAR-OLD GIRL PRESENTED WITH A 3-week history of papular lesions that had begun on her right hand and subsequently spread to the rest of her body. The lesions had grown rapidly to attain the present size. The lesions were nonpruritic and not tender. The parents reported a history of weight loss and chronic diarrhea over the last 3 months. There were no associated fevers, blistering, or mucosal involvement. Physical examination showed an emaciated child with hyperkeratosis of the skin and angular cheilitis suggestive of nutritional deficiency. Multiple 0.5×0.5-cm cervical axillary and inguinal lymph nodes were palpable. She was covered with multiple umbilicated smooth nodules with a waxy surface ranging in size from 0.2 to 5 cm (**Figure 1**). The lesions were surrounded by an erythematous halo. More than 500 lesions were noted, covering the entire body with the exception of the palms and soles. Histological evaluation revealed inverted lobules of hyperplastic, acanthotic squamous epithelium arranged in a lobulated pattern. The centers of these bulbous structures were filled with enlarged, altered keratinocytes with eosinophilic viral inclusions (**Figure 2** and **Figure 3**).

What is the diagnosis?

Author Affiliations: Department of Pediatrics, University of Illinois at Chicago.

Figure 1. Smooth, waxy nodules with central umbilication and an erythematous base on the body, including the face.

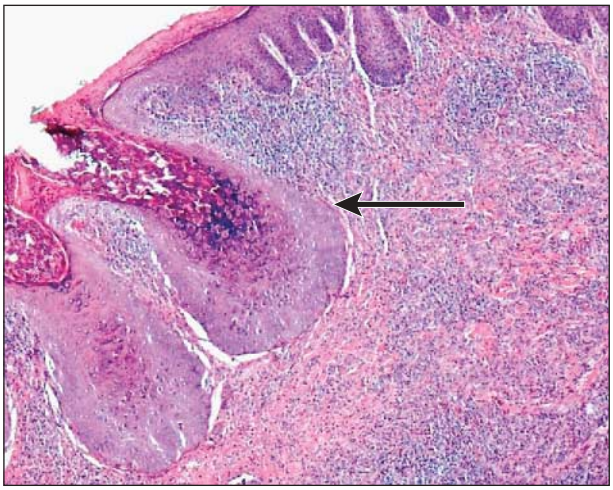

Figure 2. Inverted lobules of acanthotic squamous epithelium (arrow) with eosinophilic bodies in the upper epidermis (hematoxylin-eosin, original magnification ×40).

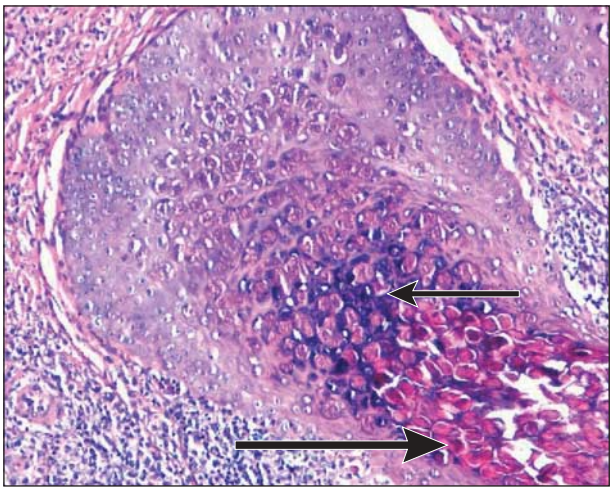

Figure 3. Intracytoplasmic eosinophilic bodies in the granular layer (thin arrow) and stratum corneum of the epidermis (thick arrow) (hematoxylin-eosin, original magnification ×100).

©2009 American Medical Association. All rights reserved.
Downloaded From: http://archpedi.jamanetwork.com/ on 05/29/2015