Picture of the Month

Iván Sánchez Fernández, MD; Jurriaan M. Peters, MD

A 2-MONTH-OLD, PREVIOUSLY HEALTHY INfant developed partial seizures, eventually controlled by phenobarbital, levetiracetam, and lamotrigine. The results of imaging studies and metabolic workup were normal. He was born full term after an uncomplicated pregnancy and delivery to healthy parents of Indian descent. His development had been unremarkable.

Author Affiliations: Department of Pediatrics, Hospital Sant Joan de Déu, Universitat de Barcelona, Barcelona, Spain (Dr Sánchez Fernández); and Department of Neurology, Children's Hospital Boston and Harvard Medical School, Boston, Massachusetts (Dr Peters).

At the age of 5 months, he had a left hemiparesis due to a right anterior cerebral artery stroke. At the age of 11 months, he presented with a right hemiparesis and focal right-sided seizures from a left middle cerebral artery stroke (**Figure 1**). The results of cardiologic evaluation, including cardiac ultrasonography, were normal. Extensive hematologic workup and genetic screening for a hypercoagulable state were unrevealing. Magnetic resonance imaging and the concurrent magnetic resonance angiogram prompted a conventional 4-vessel angiogram (**Figure 2**).

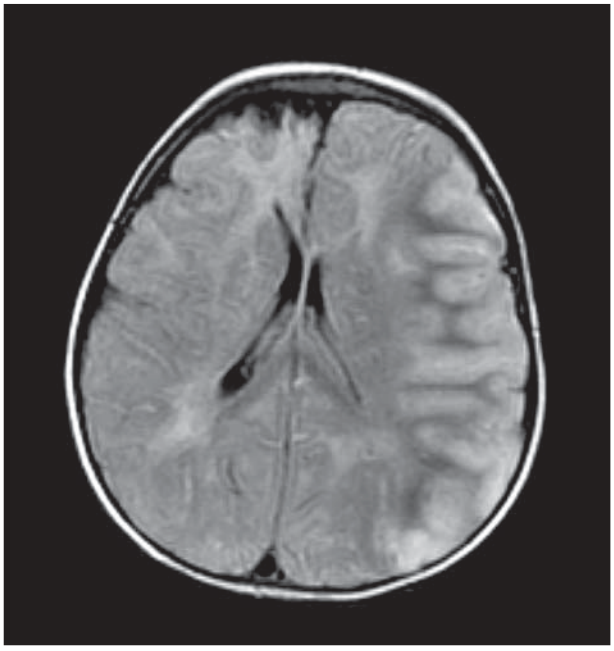

Figure 1. T2-weighted fluid-attenuated inversion recovery magnetic resonance imaging of the brain. A hyperintense region with volume loss is seen in the right frontal lobe representing gliosis from prior stroke. Extensive hyperintensity and swelling over the left hemisphere indicates subacute ischemic stroke of the left middle cerebral artery territory.

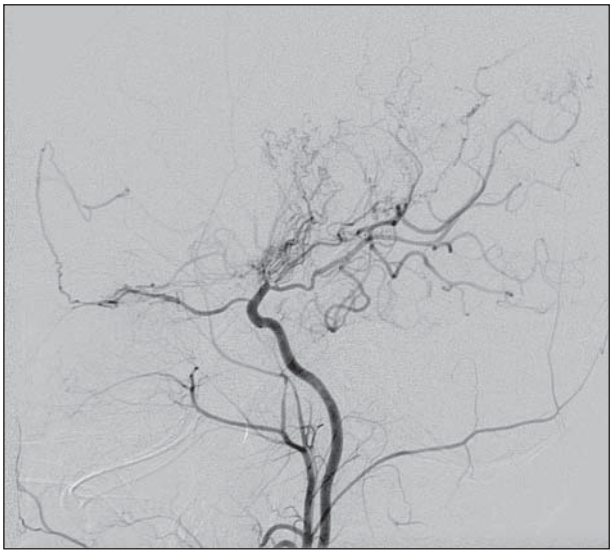

Figure 2. Arterial angiogram of the left internal carotid system. Findings are described in detail in the "Denouement and Comment" section.

©2009 American Medical Association. All rights reserved.
Downloaded From: http://archpedi.jamanetwork.com/ on 10/09/2015