# Denouement and Comment

## *Secondary Syphilis*

The differential diagnosis for this rash included erythema multiforme (EM), papular pityriasis rosea, viral eruption, hypersensitivity reaction, and secondary syphilis. Biopsy results from her right forearm revealed focal areas of lichenoid and interface dermatitis as well as areas of vacuolar degeneration of basal layer keratinocytes. Additionally, the upper dermis contained areas of granulomatous inflammation with collections of histiocytes, lymphocytes, and rare plasma cells. A periodic acid–Schiff test result for fungi was negative. Results of a immunohistochemical stain for *Treponema pallidum* were positive for spirochetes within the epidermis and dermis (**Figure 2**). The arrows in Figure 2 highlight the spirochetes, which stained red. Serology results confirmed the diagnosis of syphilis with a reactive fluorescent treponemal antibody absorption test and a reactive qualitative rapid plasma reagin titer of 1:32. The patient was treated with benzathine penicillin G, 2.4 million units, intramuscularly in a single dose. Her rash resolved within a few weeks of treatment.

Syphilis, "the great imitator," can present with a wide array of symptoms; without the appropriate testing, including immunohistochemical staining, it can be very difficult to diagnose. Immunohistochemistry with monoclonal antibody to *T pallidum* has been shown in multiple studies to be a better method for detecting spirochetes, with higher sensitivity, specificity, and less background artifact than traditional silver stains.[1,2] Diagnosis and subsequent treatment of secondary syphilis are critical to prevent occurrence of cardiac and neurologic sequelae of tertiary syphilis. In this case, the patient's presentation had a broad differential diagnosis including EM, papular pityriasis rosea, viral eruption, hypersensitivity reaction, and syphilis. A positive immunohistochemistry result for *T pallidum* helped confirm diagnosis.

Several recent case studies have suggested that targetoid lesions similar to those seen in this patient could be a novel presentation of EM caused by a reaction to the syphilis, as opposed to simply an unusual presentation of secondary syphilis.[3] The exact pathophysiology of EM is not well understood, but it is likely a type of hypersensitivity reaction. The clinical presentation in this patient of targetoid lesions was EM-like and many of the pathology changes, including vacuolar degeneration of basal layer keratinocytes and interface dermatitis seen on this patient's biopsy result, can be seen in both syphilis and EM. This suggests that the appearance of EM-like targetoid lesions may be caused by a specific immune response against *T pallidum*.[4] Four previously described patients exhibited targetoid lesions in their presentations of secondary syphilis, suggesting that this is not an isolated unique event and may link EM and *T pallidum*.[3,4]

After hitting a low point in 2000, US cases of syphilis have been steadily increasing during the past decade, with only a slight decline in 2010.[5] With the ever-changing clinical presentation, it is important for physicians in all practices, including pediatrics, to have a low threshold for testing for syphilis in patients with unusual skin findings. Syphilis is currently most prevalent in the Southern United States.[5] Young adults ages 20 to 24 years have the highest rates of syphilis, with 13.5 cases per 100 000 population in 2010. Although often viewed as an antiquated disease, syphilis is still very prevalent and the clinical picture is still evolving.

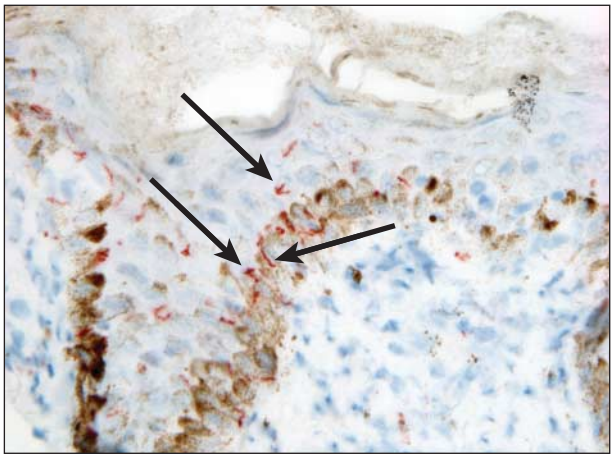

**Figure 2.** Photomicrograph of the immunohistochemistry stain from a skin biopsy performed from a targetoid papule (original magnification ×60).

**Accepted for Publication:** August 5, 2012.
**Correspondence:** Leslie Castelo-Soccio, MD, PhD, The Children's Hospital of Philadelphia, Division of Pediatrics, Section of Dermatology, 3550 Market St, 2nd Flr, Philadelphia, PA 19104 (castelosocciol@email.chop.edu).
**Author Contributions:** *Study concept and design:* Goff, Gormley, McMahon, Rubin, and Castelo-Soccio. *Acquisition of data:* Goff, Gormley, Rubin, and Castelo-Soccio. *Analysis and interpretation of data:* Gormley, Rubin, and Castelo-Soccio. *Drafting of the manuscript:* Goff, Gormley, Rubin, and Castelo-Soccio. *Critical revision of the manuscript for important intellectual content:* Gormley, McMahon, Rubin, and Castelo-Soccio. *Administrative, technical, and material support:* Goff, Gormley, Rubin, and Castelo-Soccio. *Study supervision:* McMahon, Rubin, and Castelo-Soccio.
**Conflict of Interest Disclosures:** None reported.

## REFERENCES

1. Hoang MP, High WA, Molberg KH. Secondary syphilis: a histologic and immunohistochemical evaluation. *J Cutan Pathol.* 2004;31(9):595-599.
2. Phelps RG, Knispel J, Tu ES, Cernainu G, Saruk M. Immunoperoxidase technique for detecting spirochetes in tissue sections: comparison with other methods. *Int J Dermatol.* 2000;39(8):609-613.
3. Bhate C, Tajirian AL, Kapila R, Lambert WC, Schwartz RA. Secondary syphilis resembling erythema multiforme. *Int J Dermatol.* 2010;49(11):1321-1324.
4. Kim YY, Lee JH, Yoon SY, Lee JD, Cho SH. Erythema multiforme-like targetoid lesions in secondary syphilis. *Acta Derm Venereol.* 2007;87(4):381-382.
5. Centers for Disease Control and Prevention. *Sexually Transmitted Disease Surveillance 2010.* Atlanta, GA: US Dept of Health and Human Services; 2011.



©2012 American Medical Association. All rights reserved.
Downloaded From: http://archpedi.jamanetwork.com/ on 09/04/2015