Picture of the Month

Wendy Kein Meng Liew, MRCPCH; Ngee Lek, MRCPCH; Saumya Shekhar Jamuar, MBBS, MRCPCH; Kim Whee Lim, FAMS

A 9.5-YEAR-OLD BOY WAS REFERRED TO THE neurology clinic for waddling gait and hip pain. He has had a history of constipation, cold intolerance, reduced energy, and poor concentration for at least 4 years. In addition, he has mild developmental delay but is able to cope in normal mainstream school.

On physical examination, he had rounded facies, dry skin, loss of the lateral third of his eyebrows, coarse hair, low-pitched voice, macro-orchidism, and a waddling gait. He did not have goiter, proximal myopathy, or a delayed relaxation phase of deep tendon reflexes. He was extremely short for his age. His height of 108.8 cm (SD score, –4.54) was also significantly lower than his parental target centile range of 151 cm (SD score, –3.53) to 171 cm (SD score, –0.79). His bone age was delayed at 2 years. Radiographs of the left hip (**Figure 1**) and the hand, lower limbs, spine, and skull (**Figure 2**) were obtained.

Author Affiliations: Neurology (Drs Liew and Lim), Endocrinology (Dr Lek), and Genetics (Dr Jamuar) Services, Department of Pediatric Medicine, KK Hospital, Singapore.

A. Perthes disease
B. Meyer dysplasia
C. Primary hypothyroidism
D. Multiple epiphyseal dysplasia

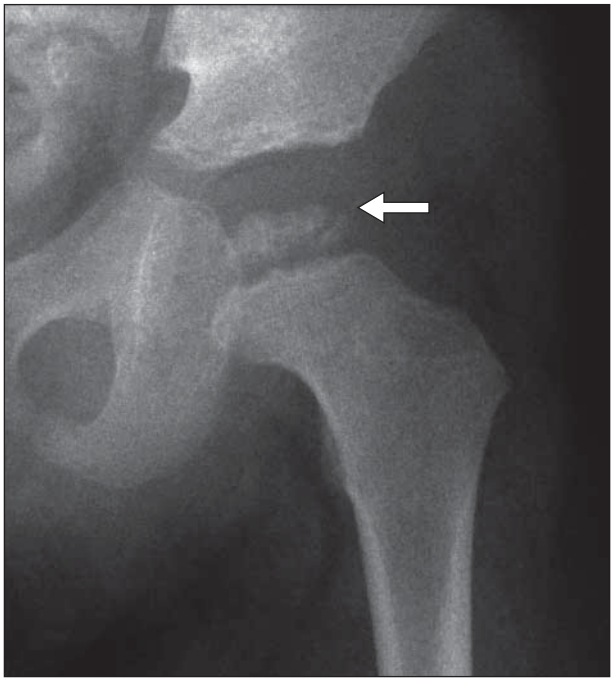

Figure 1. Radiograph of the left hip showed an irregular and fragmented left capital femoral epiphysis (arrow).

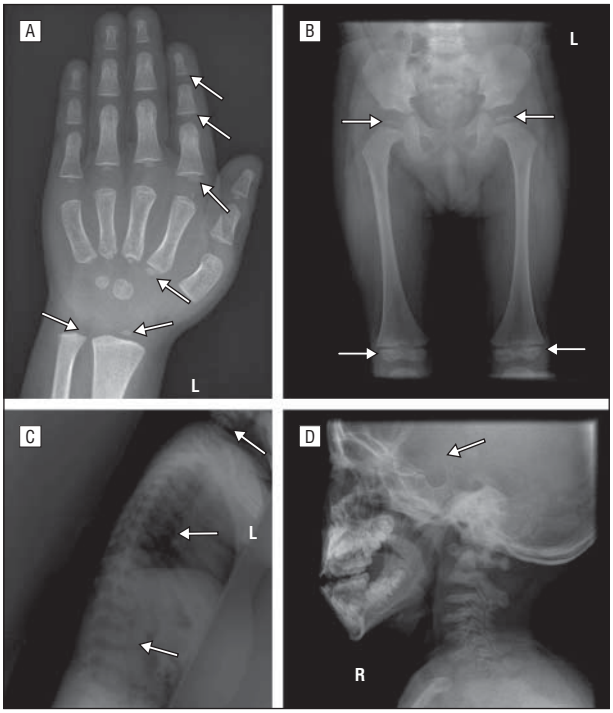

Figure 2. Radiographs of the hand, lower limbs, spine, and skull. A, Hand radiograph showed bone age delayed at 2 years and poorly ossified epiphyses of the phalanges, metacarpals, radius, and ulna (arrows). B, Lower limb radiograph featured bilateral irregular and fragmented epiphyses (arrows). L indicates left. C, Lateral radiograph of the spine showed varying degrees of flattening of the vertebral bodies (arrows). L indicates left. D, Lateral radiograph of the skull showed an enlarged sella turcica (arrow). R indicates right.

©2012 American Medical Association. All rights reserved.
Downloaded From: http://archpedi.jamanetwork.com/ on 07/23/2014