ARTICLE

Cramped Synchronized General Movements in Preterm Infants as an Early Marker for Cerebral Palsy

Fabrizio Ferrari, MD; Giovanni Cioni, MD; Christa Einspieler, PhD; M. Federica Roversi, MD; Arend F. Bos, MD, PhD; Paola B. Paolicelli, MD; Andrea Ranzi, PhD; Heinz F. R. Prechtl, MD, DPhil, FRCOG(Hon)

Objective: To ascertain whether specific abnormalities (ie, cramped synchronized general movements [GMs]) can predict cerebral palsy and the severity of later motor impairment in preterm infants affected by brain lesions.

Design: Traditional neurological examination was performed, and GMs were serially videotaped and blindly observed for 84 preterm infants with ultrasound abnormalities from birth until 56 to 60 weeks' postmenstrual age. The developmental course of GM abnormalities was compared with brain ultrasound findings alone and with findings from neurological examination, in relation to the patient's outcome at age 2 to 3 years.

Results: Infants with consistent or predominant (33 cases) cramped synchronized GMs developed cerebral palsy. The earlier cramped synchronized GMs were observed, the worse was the neurological outcome. Transient cramped synchronized character GMs (8 cases) were followed by mild cerebral palsy (fidgety movements were absent) or normal development (fidgety movements were present). Consistently normal GMs (13 cases) and poor repertoire GMs (30 cases) either lead to normal outcomes (84%) or cerebral palsy with mild motor impairment (16%). Observation of GMs was 100% sensitive, and the specificity of the cramped synchronized GMs was 92.5% to 100% throughout the age range, which is much higher than the specificity of neurological examination.

Conclusions: Consistent and predominant cramped synchronized GMs specifically predict cerebral palsy. The earlier this characteristic appears, the worse is the later impairment.

Arch Pediatr Adolesc Med. 2002;156:460-467

From the Institute of Paediatrics and Neonatal Medicine, University of Modena, Italy (Drs Ferrari, Roversi, and Ranzi); the Institute of Developmental Neurology, Psychiatry, and Educational Psychology, University of Pisa, and the Stella Maris Foundation, Calambrone, Pisa, Italy (Drs Cioni and Paolicelli); the Department of Physiology, University of Graz, Austria (Drs Einspieler and Prechtl); and the Department of Paediatrics, Beatrix Children's Hospital, University of Groningen, Groningen, the Netherlands (Dr Bos).

IN THE PAST 20 years, there has been a dramatic reduction in neonatal mortality of low-birth-weight and very low-birth-weight infants but a relative increase in the incidence of cerebral palsy among children with low birth weight and short gestation.[1-4] An increased survival rate is associated with an increased proportion of infants with cerebral palsy, and it has been suggested that the reduction in neonatal mortality and the concomitant relative increase in cerebral palsy might be associated[5] because the prevalence of cerebral palsy rises sharply the lower the weight of the infant at birth.[6-8] Cerebral palsy occurs in 8% to 10% of very preterm babies, and approximately 40% of all children with cerebral palsy were born preterm.[8,9]

For editorial comment see page 422

An early prediction of cerebral palsy will lead to earlier enrollment in rehabilitation programs. Unfortunately, reliable identification of cerebral palsy in very young infants is extremely difficult.[10] It is generally reported that cerebral palsy cannot be diagnosed before several months after birth[11-15] or even before the age of 2 years.[16] A so-called silent period, lasting 4 to 5 months or more, and a period of uncertainty until the turning point at 8 months of corrected age have also been identified.[12,13] The neurological symptoms observed in the first few months after birth in preterm infants who will develop cerebral palsy are neither sensitive nor specific enough to ensure reliable prognoses. Irritability, abnormal finger posture, spontaneous Babinski reflex,[17,18] weakness of the lower limbs,[19] transient abnormality of tone,[12,13,20-24] and delay in achieving motor milestones[11] are some of the neurological signs that have been described in these high-risk preterm in-

See the enhanced version at http://www.archpediatrics.com

©2002 American Medical Association. All rights reserved.
Downloaded From: http://archpedi.jamanetwork.com/ on 05/04/2015

SUBJECTS AND METHODS

High-risk preterm infants were enrolled at the University of Modena and the University of Pisa (Italy) for a prospective, collaborative study of GM observation. The scientific Research Committee of the Italian Ministry of Health, Rome, approved the study. Infants who fulfilled the following criteria—mother's last menstrual date reliably known, gestational age less than 37 completed weeks, ultrasound abnormalities highly suggestive of brain parenchymal insult, repeated GM assessment and neurological examination until about 56 to 60 weeks' postmenstrual age, and neurological follow-up until 2 to 3 years' corrected age—were included in the study. We excluded infants with chromosomal defects or major malformations of the brain or other organs. All infants with GM observation or neurological examination missing at more than 1 key age were also excluded. We enrolled 93 infants, but 9 were omitted because of missing data. Eighty-four infants were included in the final sample. The clinical data of the study group are listed in **Table 1**. Some infants had taken part in previous studies,[29,32,34] and all parents gave their informed consent.

ULTRASOUND SCANS

On the basis of serial ultrasound scans, performed with 5- to 7.5-MHz heads, we included infants with cystic (34 cases) or noncystic (34 cases) abnormalities of the white matter. Cystic lesions were categorized as small and localized, extensive periventricular, and/or subcortical cysts. Noncystic lesions consisted of increased periventricular echogenicity, characterized by globular, blotchy, coarse hyperechoic ultrasound images localized in the periventricular region that were seen both in coronal and parasagittal views, persisted for 2 weeks or longer, and resolved without subsequent development of cysts or enlargement of the lateral ventricles (adapted from Dammann and Leviton[41]). Sixteen infants with intraventricular hemorrhage grades 3 and 3+, according to Volpe,[42] were also included. Ultrasound abnormalities were reviewed blindly by an expert in ultrasounds (A.B.) who was unaware of the clinical history and development of the infants.

OBSERVATION OF GMs

Videotape recordings were usually made at 3-week to 5-week intervals from birth until the preterm infants were discharged from the hospital. During the study period, each infant was recorded 5 to 10 times. Serial assessments of GM quality were displayed on a time axis to trace individual developmental trajectories.[27] Because the functional repertoire changes at various ages, we divided our longitudinal data into 4 "key age" periods: preterm (up to 37 weeks' postmenstrual age), term age (38-42 weeks' postmenstrual age), 43 to 46 weeks' postmenstrual age, and 47 to 60 weeks' postmenstrual age. The quality of the GMs of infants recorded in Modena was assessed in Pisa (G.C.), and infants recorded in Pisa were assessed in Modena (F.F.). In addition, one of us (H.F.R.P.), who was unaware of the infants' clinical histories and ultrasound results, reassessed the quality of GMs. Interobserver agreement in the judgment of the quality of GMs was 90.2%. If investigators disagreed, an agreement was reached after reassessment and discussion. From birth until the end of the second month postterm, GMs were scored as normal, poor repertoire, or cramped synchronized. From 47 to 60 weeks' postmenstrual age, GMs of a fidgety character were scored as present (normal or abnormal) or absent. When more than 1 judgment per age period was available for a single subject, the first observation for this age period was used. In addition, GMs of a cramped synchronized character could be scored until 60 weeks' postmenstrual age (**Figure 1**).

DEFINITIONS

General movements are gross movements that involve the whole body; they may last from a few seconds to several minutes. They appear early in gestation (9-10 weeks' postmenstrual age) and are the most complex of the whole repertoire of endogenously generated distinct movements.

What is particular about normal GMs is the variable sequence of arm, neck, and trunk movements. They wax and wane in intensity, force, and speed, and they have a gradual beginning and end. The majority of the sequence of extension and flexion movements of arms and legs is complex, with superimposed rotations and, often, slight changes in the direction of the movement. These additional components make the movement fluent and elegant and create

Continued on next page

fants. All these symptoms may be encountered before the onset of cerebral palsy or during "transient dystonia,"[21] dissociated motor development,[25,26] and other transient neurological disturbances,[23,24] which disappear during the first or second year of life. Moreover, no correlations have been found among any of these symptoms and the severity of future motor impairment. Therefore, traditional neurological examination fails to predict the development and severity of cerebral palsy.[10,16]

Neurological examination of newborns and young infants is mostly based on the study of neonatal reflexes, such as grasping, Moro reflex, rooting, and tonic asymmetric response and evoked responses, such as those involved in passive and active muscle tone. Little attention is paid to the spontaneous activity of the baby. More than 10 years ago, Prechtl et al[27-29] introduced a new approach to neurological evaluation based on spontaneous motor activity, rather than reflexes and evoked responses. Theoretical and empirical considerations suggest that the quality of endogenously generated motor activity is a better indicator of neural function integrity than many items in the neurological examination.[27] In fact, fetuses and newborn infants exhibit a large number of endogenously generated motor patterns, which are produced by central pattern generators located in different parts of the brain. Moreover, substantial indications suggest that spontaneous activity is a more sensitive indicator of brain dysfunction than reactivity to sensory stimuli in reflex testing. Various studies[29-40] have demonstrated that in newborn

©2002 American Medical Association. All rights reserved.
Downloaded From: http://archpedi.jamanetwork.com/ on 05/04/2015

the impression of complexity and variability. Despite this variability, GMs must be considered as a distinct coordinated pattern that is easy to recognize each time it occurs.

In poor repertoire GMs, the sequence of the components of the successive movements is monotonous, and the movements of the different body parts do not occur in the complex way seen in normal GMs.

Cramped synchronized GMs appear rigid and lack the normal smooth and fluent character. All limb and trunk muscles contract and relax almost simultaneously.

Fidgety movements are an ongoing stream of small, circular, and elegant movements of the neck, trunk, and limbs; they emerge at 6 to 9 weeks' and disappear around 15 to 20 weeks' postterm age. Abnormal fidgety movements look like normal fidgety movements, but their amplitude, speed, and jerkiness are moderately or greatly exaggerated.

Abnormal GM quality could persist throughout the entire period of observation or just part of it. We called an individual developmental trajectory with the same GM abnormality throughout the study period *consistent*. When GM abnormality was observed transiently during preterm and/or term age only, we used the term *transient*. When cramped synchronized GMs (preceded by poor repertoire GMs) were present for even longer and did not disappear until 60 weeks' postmenstrual age, the term *predominant* was used.

NEUROLOGICAL EXAMINATION AND FOLLOW-UP

During the preterm and term periods, neurological examination was carried out in accordance with the Dubowitz and Dubowitz[43] and Prechtl[44] protocols, respectively. During the first 5 months' postterm and afterward, videotapes of spontaneous motility and clinical checks were accompanied by a standardized neurological assessment, based on items from Touwen.[45] The neurological assessment was also videotaped. Any abnormal signs in the neurological examinations were noted. During the preterm period, we looked for the following abnormalities from the Dubowitz protocol: abnormal posture, generalized or segmental hypotonia or hypertonia, hypokinesis, abnormal head control, frequent tremors or startles, absent or abnormal responses or reflexes, hyporeactivity to stimulation, and irritability.[43,46] The results of the Prechtl examination, performed at term, were classified according to the syndromes indicated in the summary form.[44] The neurological examination was scored as abnormal when at least 1 of the abnormalities mentioned above was present. Additionally, at the age of 2 to 3 years, a developmental test according to the Griffiths Developmental Scales[47] was performed. At this age, the outcome was classified as "normal" (no neurological signs) or "cerebral palsy." Cerebral palsy was defined as "a chronic disability characterized by aberrant control of movement or posture, appearing early in life and not the result of recognized progressive disease."[48(p707)] At 2 to 3 years of age, the severity of motor disability was scored in accordance with the classification system for gross motor function in children with cerebral palsy recently proposed by Palisano et al.[49] We distinguished mild (grade 1) and moderate to severe motor impairment (grades 2-5). In addition, we defined minor neurological deficits: mild sensory deficits, strabismus, severe postural delay without corticospinal tract dysfunction, and/or a score between 50 and 84 on the Griffiths Developmental Scales.

INTEROBSERVER RELIABILITY

The neurological examinations in Modena and in Pisa were performed by two of us (F.F. and G.C., respectively). To assess functional impairment in cerebral palsy, the same authors reviewed the neurodevelopmental records and videotapes of the infants at the time of the last clinical check. Preterm infants from Pisa were scored by one of us (F.F.), and while another of us (G.C.) scored infants from Modena; these scores were compared with the original scores given by local physical therapists and pediatric neurologists. In case of disagreement, an agreement was reached after reassessment and discussion.

STATISTICAL ANALYSIS

The receiver operating characteristic curve analysis was used to compare the power of ultrasounds and GMs to predict cerebral palsy.[50] Receiver operating characteristic curve analysis provides a powerful means of assessing a test's ability to discriminate between 2 groups of patients, with the advantage that the analysis does not depend on the threshold value selected. To test the correlation between the time of appearance of the cramped synchronized GMs and the severity of motor impairment in children with cerebral palsy, a Yates trend test (2-tailed)[51] was used. This test estimates the trend based on regression concepts and is more appropriate and sensitive than a χ^2 test for $p \times q$ contingency tables. A P value of $<.05$ was considered statistically significant. A standard formula was used to calculate the likelihood ratio of GMs, the cramped synchronized character of GMs, and findings from neurological examination.

infants affected by different brain lesions, spontaneous motility does not change in quantity, but it loses its elegance, fluency, and complexity. General movements (GMs) have been selected from among the whole repertoire of spontaneous motor patterns because of their complexity and frequent occurrence. A range of abnormalities in the quality of GMs, such as hypokinesis, poor repertoire, abnormal or absent fidgety movements, and chaotic and cramped synchronized GMs, have been described. Visual gestalt perception is a powerful and reliable instrument for detecting these alterations in the complexity of movements. Cramped synchronized character, the most severe motor abnormality, has been found to be predictive of severe neurological impairment.[29,32,34,35] Recently, the absence or abnormality of GMs of fidgety character, or fidgety movements, at 47 to 60 weeks' postmenstrual age has been shown to be a high-validity predictor of future neurological impairment, specifically cerebral palsy.[34]

A collaborative study with a large cohort of high-risk preterm infants was specifically designed to achieve a better understanding of the relationship among cramped synchronized GMs, later cerebral palsy, and the severity of functional impairment. More specifically, 3 main questions were addressed. First, are cramped synchronized GMs an early and specific marker of later cerebral palsy? Second, is the emergence and development of cramped synchronized GMs somehow related to the severity of cerebral palsy? And third, are GMs as powerful a prognostic tool as ultrasound abnormalities alone and tradi-

©2002 American Medical Association. All rights reserved.
Downloaded From: http://archpedi.jamanetwork.com/ on 05/04/2015

Table 1. Clinical Characteristics of 84 High-Risk Preterm Infants*

Characteristics	Infants
Postmenstrual age at birth, mean ± SD, wk	30.2 ± 2.7
Birth weight, mean ± SD, g	1410.14 ± 456.71
Outborn	14
Inborn	86
Boys	50
Girls	50
Preeclamptic toxemia	7
Multiple pregnancies	6
Acute fetal distress†	13
Appropriate size for gestational age	76
Small for gestational age	24
Severe respiratory distress syndrome‡	42
Severe infection§	33
Seizures	17
Patent ductus arteriosus	30
Bronchopulmonary dysplasia	13
Retinopathy of prematurity (grades 2-5)	17

*Data are given as percentage of subjects unless otherwise indicated.
†Acute fetal distress was indicated by late fetal heart deceleration.
‡Severe respiratory distress syndrome was indicated by more than 3 days of mechanical ventilation.
§Severe infections include positive blood culture; positive immature–total granulocyte ratio and reactive C protein; and 1 or more clinical signs of infection (respiratory distress, hypotension, metabolic acidosis, temperature instability, gastrointestinal symptoms, diminished activity or lethargy, and seizures).

tional neurological examination, or are they even more powerful?

RESULTS

NEUROLOGICAL OUTCOME

At 2 to 3 years of age, 40 infants were healthy, and 44 had spastic-type cerebral palsy (22 subjects had diplegia, 14 had tetraplegia, and 8 had hemiplegia). Fifteen infants showed grade 1 motor impairment, according to Palisano et al,[49] 5 infants had grade 2, 5 had grade 3, 9 had grade 4, and 10 had grade 5. With the exception of 1 infant with a mild hearing defect, no case of minor neurological disorder was observed.

Ultrasound Findings

Severe ultrasound abnormalities (ie, extensive cysts and germinal matrix–intraventricular hemorrhage grade 3+) were present in 31 infants and, with 1 exception, led to cerebral palsy. Minor ultrasound abnormalities (persisting increased echogenicity, small and localized cysts, and germinal matrix–intraventricular hemorrhage grade 3) were present in 53 infants. The majority of cases (39 infants) had a normal outcome; cerebral palsy with mild (7 infants) or moderate to severe (7 infants) impairment was also observed (**Table 2**).

Developmental Trajectories

The time course of GM quality in relation to the neurological outcome is provided in **Table 3** and **Figure 2**.

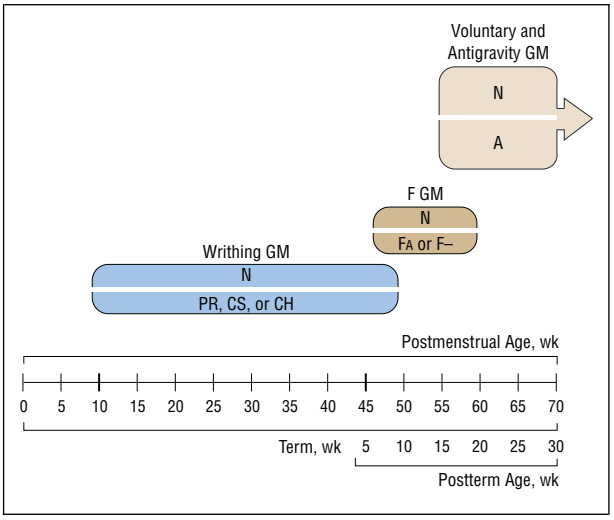

Figure 1. Types of normal (N) and abnormal (A) general movements (GMs) in 84 high-risk preterm infants during preterm, term, and the first 5 months of postterm age. F indicates fidgety; PR, poor repertoire; CS, cramped synchronized; and CH, chaotic.

The duration and consistency of GM quality determined to a high degree the normality or severity of the abnormal outcome. All 33 preterm infants who displayed predominant (19 cases) or consistent (14 cases) cramped synchronized character GMs throughout the study period developed cerebral palsy. None of them displayed fidgety movements between 47 to 60 weeks' postmenstrual age. By contrast, 13 infants with consistent normal GMs, 4 infants with transient poor repertoire GMs, 19 infants with consistent poor repertoire GMs, and 4 infants with transient cramped synchronized GMs had a normal outcome. Despite the different patterns of developmental trajectory, these infants had fidgety movements in common (3 showed abnormal fidgety movements). The only exception was 1 infant with no fidgety movements who showed a prolonged postural delay that disappeared at 3 years of age and was classified as normal (**Table 4**). Of the preterm infants with consistent poor repertoire GMs (7 cases) and transient cramped synchronized GMs (4 cases) who later developed cerebral palsy, 10 had no fidgety movements, and 1 had exaggerated fidgety movements. The relationship between the age of appearance of predominant or consistent cramped synchronized GMs and the severity of the neurological impairment demonstrates that the earlier the cramped synchronized quality GMs appear, the worse is the outcome. The Yates trend test (T, 3.207; $P < .005$) proved the statistical significance of this statement.

PREDICTIVE VALUE OF ULTRASOUND SCANS AND GMs

The areas under the receiver operating characteristic curve analysis for GMs and ultrasound scans were quite large (97.4 and 88.3, respectively), which shows that they are both accurate tests. A statistically significant difference was found between the 2 methods ($P = .001$). The quality of GMs was a better index to predict neurological outcome in a group of infants who were selected on the basis of abnormal ultrasound findings (**Figure 3**).

©2002 American Medical Association. All rights reserved.
Downloaded From: http://archpedi.jamanetwork.com/ on 05/04/2015

Table 2. Ultrasound Scan Results and Neurological Outcome in 84 High-Risk Preterm Infants*

	Neurological Outcome, No. of Subjects						
		CP Motor Impairment Grade					
Ultrasound Scan Results	**Normal Subjects**	**1**	**2**	**3**	**4**	**5**	**Total**
Persisting increased periventricular echogenicity	28	3	2	0	0	1	**34**
Small, localized periventricular cysts	7	1	3	0	0	0	**11**
GMH-IVH grade 3	4	3	0	1	0	0	**8**
GMH-IVH grade 3+, intraparenchymal echodensity	1	6	0	0	1	0	**8**
Extensive periventricular and/or subcortical cysts	0	2	0	4	8	9	**23**
Total	**40**	**15**	**5**	**5**	**9**	**10**	**84**

*GMH-IVH indicates germinal matrix–intraventricular hemorrhage, graded according to Volpe[42]; CP, cerebral palsy, graded according to Palisano et al.[49]

Table 3. Types of Developmental Trajectories and Neurological Outcome in 84 High-Risk Preterm Infants*

	Neurological Outcome, No. of Subjects	
Movement	**Cerebral Palsy**	**Normal**
Predominant and consistent CS	33	0
Consistent PR	7	19
Transient CS	4	4
Transient PR	0	4
Normal GM	0	13
Total	**44**	**40**

*CS indicates cramped synchronized; PR, poor repertoire; and GM, general movement.

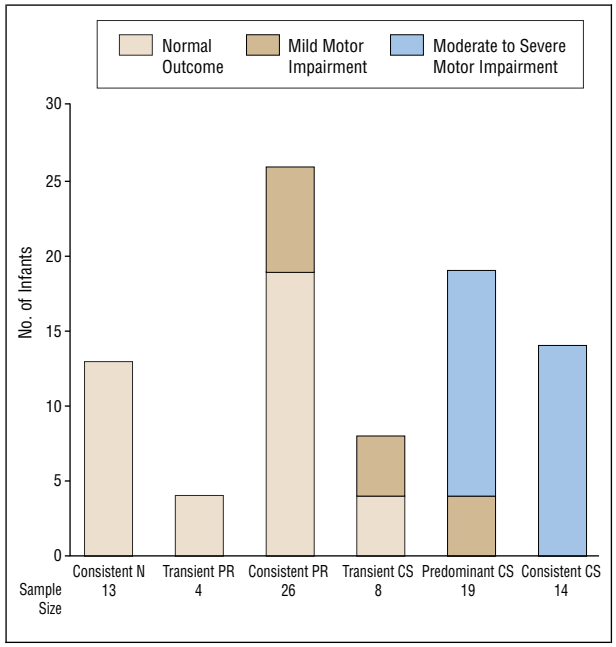

Figure 2. Types of developmental trajectories and neurological outcome in 84 high-risk preterm infants. N indicates normal movements; PR, poor repertoire; and CS, cramped synchronized.

Table 4. Fidgety Movements (FMs) and Neurological Outcome in 84 High-Risk Preterm Infants

	Neurological Outcome, No. of Subjects	
Movement	**Cerebral Palsy**	**Normal**
Normal FM	0	36
Abnormal FM	1	3
Absent FM	43	1
Total	**44**	**40**

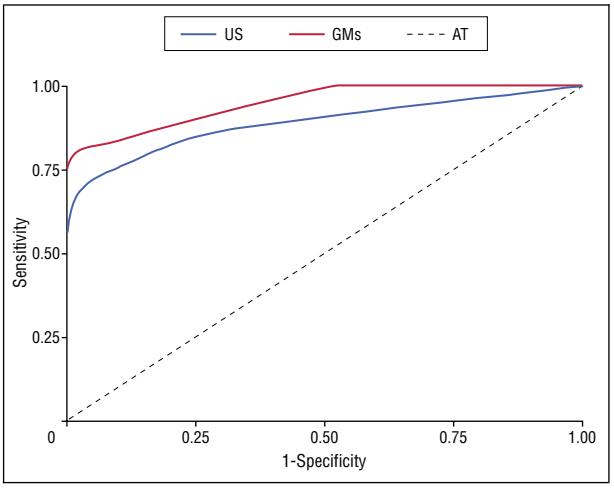

Figure 3. The area under the receiver operating characteristic (ROC) curve for quality of general movements (GMs) and ultrasound (US) scans in high-risk preterm infants. The ROC curve is generated by plotting the proportion of true-positive results against the proportion of false-positive results for each value of a test. The curve for an arbitrary test (AT) that is expected to have no discriminatory value appears as a diagonal line, whereas a useful test has an ROC curve that rises rapidly and reaches a plateau.

LIKELIHOOD RATIO AND ACCURACY OF GMs AND NEUROLOGICAL EXAMINATION IN PREDICTING CEREBRAL PALSY

The positive likelihood ratio of cramped synchronized GMs for predicting cerebral palsy is much higher than that of neurological examination throughout the age range. The negative likelihood ratio for predicting cerebral palsy based on GM quality was also much higher than that for neurological examination during the study period.

The GM observation was 100% sensitive throughout the age range; neurological examination was less sensitive during the study period. The sensitivity of cramped synchronized GMs was low (46.5%) in the preterm period because of those infants with cramped synchronized GMs preceded by poor repertoire GMs. Sensitivity rose to 65%, 78.7%, and 77.2% at term, early postterm

©2002 American Medical Association. All rights reserved.
Downloaded From: http://archpedi.jamanetwork.com/ on 05/04/2015

Table 5. Age Period–Related Likelihood Ratios (LRs) and Accuracy for General Movement (GM) Observation, Cramped Synchronized Character, and Neurological Examination With Respect to Cerebral Palsy*

	Age Period			
	Preterm	Term Age	Postterm	Fidgety
Postmenstrual age, wk	28-37	38-42	43-46	47-60
No. of infants†	83	79	70	84
GM assessment				
LR+ (95% CI)	1.5 (1.19-1.89)	1.52 (1.20-1.93)	2.11 (1.48-3.0)	7.8 (3.44-17.78)
LR– (95% CI)	<0.07 (0.01-0.48)	<0.07 (0.01-0.50)	<0.06 (0.01-0.39)	<0.02 (0.04-0.18)
Sensitivity, %	100	100	100	100
Specificity, %	38	41	53	82
Positive predictive value, %	63	63	55	86
Negative predictive value, %	100	100	100	100
Cramped synchronized character				
LR+ (95% CI)	4.97 (1.57-15.75)	22.4 (3.18-158)	>28 (4.02-195.6)	>30 (4.3-209)
LR– (95% CI)	0.68 (0.53-0.87)	0.44 (0.30-0.63)	0.25 (0.13-0.46)	0.26 (0.15-0.43)
Sensitivity, %	46	65	79	77
Specificity, %	92	97	100	100
Positive predictive value, %	87	96	100	100
Negative predictive value, %	62	73	84	80
Neurological examination results				
LR+ (95% CI)	1.06 (0.81-1.39)	1.71 (1.11-2.61)	1.82 (1.29-2.57)	1.66 (1.26-2.18)
LR– (95% CI)	0.85 (0.42-1.71)	0.51 (0.3-0.87)	0.18 (0.06-0.54)	0.11 (0.03-0.43)
Sensitivity, %	58	68	89	95
Specificity, %	45	63	52	70
Positive predictive value, %	54	66	67	77
Negative predictive value, %	48	65	84	93

*CI indicates confidence interval.

†The total number of infants ranges from 70 through 84 for the different observation periods because GM observation or neurological examination for 1 of the age periods was missing for some infants.

period, and fidgety age, respectively, because of preterm infants who developed cerebral palsy after transient cramped synchronized GMs or consistent poor repertoire GMs. Even more striking was the difference in specificity when cramped synchronized GMs were compared with neurological examination. The specificity of the former was extremely high (92.5% to 100%) for all age ranges; it was invariably much higher than that afforded by neurological examination (**Table 5**).

COMMENT

Two major findings emerge from this study. First, the cramped synchronized character of GMs, if consistent in time or predominant from preterm birth to 5 months' postterm age, specifically predicts later cerebral palsy. Second, the time of appearance of cramped synchronized GMs predicts the degree of later functional impairment caused by cerebral palsy: the earlier the appearance, the more severe the functional impairment.

Our study also confirmed observations from previous investigations.[32,52] Normal fidgety movements following transient abnormalities of GM quality point to a normal outcome, absence of fidgety movements suggests a neurological deficiency, and GMs are a more powerful prognostic tool than traditional neurological examination and ultrasound scan.[34]

The severity and prognostic value of the cramped synchronized character of GMs were known from previous studies.[29,32] However, the finding that this motor abnormality is a specific marker of later cerebral palsy is new. A detailed analysis of the developmental trajectories of GMs in a large group of preterm infants affected by major or minor abnormalities detected by ultrasound demonstrates that the consistent or predominant cramped synchronized character of GMs, irrespective of the severity of the ultrasound abnormalities, is always followed by cerebral palsy.

The study has practical and obvious implications. It offers clues about the selection criteria for a strict neurological follow-up. Preterm infants who are waiting for a definite diagnosis of brain integrity are usually enrolled in prospective neurological follow-up programs based on their clinical history and the ultrasound findings rather than a functional assessment, which involves the evaluation of mental and motor performance. Recent studies[53-55] have shown that mental retardation and learning deficiencies are common among preterm infants tested at school age. We are not sure whether normal, or only mildly abnormal, GMs at these early ages exclude these minor deficiencies at a later age. This study stresses the importance of functional assessment based on early observations of spontaneous motor behavior. The normal quality of GMs identifies those infants who are not affected by brain dysfunction and who will develop normally; they do not need strict neurological surveillance. In contrast, prolonged cramped synchronized character GMs identify infants who are most likely to develop cerebral palsy. They are the ones who need and can possibly benefit from early intervention.

The first videotape should be recorded as soon as possible after birth, when the effects of analgesia and/or

©2002 American Medical Association. All rights reserved.
Downloaded From: http://archpedi.jamanetwork.com/ on 05/04/2015

What This Study Adds

Cerebral palsy occurs in 8% to 10% of very preterm infants, whereas approximately 40% of all children with cerebral palsy are born preterm. An early prediction of cerebral palsy will lead to earlier rehabilitation programs. Unfortunately, reliable identification of cerebral palsy in very young infants is extremely difficult.[10] It is generally reported that cerebral palsy cannot be diagnosed before several months after birth[11-15] or even before the age of 2 years. In addition, traditional neurological examination fails to predict the development and severity of cerebral palsy

Our study demonstrates that the cramped synchronized character of GMs, if consistent in time or predominant from preterm birth to 5 months' postterm age, specifically predicts later cerebral palsy. Second, the time of appearance of cramped synchronized GMs predicts the degree of later functional impairment of cerebral palsy: the earlier the appearance, the more severe is the functional impairment.

The study has practical and obvious implications. It offers clues about the selection criteria for a strict neurological follow-up and helps the physician involved in the follow-up recognize the early signs of cerebral palsy and, consequently, begin early rehabilitation programs.

sedation have worn off and the small preterm infant is in stable physical condition. Regular videotape recordings will preferably be made until 47 to 60 weeks' postmenstrual age. When cramped synchronized GMs are spotted, it is wise to continue recording to determine whether they are transient or consistent and whether fidgety movements will appear.

A review of various studies[56] highlights that the technique of GM assessment is reliable (interscorer agreement, 78%-98%) and easy to learn. In our experience, a training course followed by a few months of practice on clinical material (ie, serial videotapes of a few infants) introduces the beginner to the clinical application of the method. The pattern of cramped synchronized GMs is the easiest to spot because all or most of the limbs contract and relax almost simultaneously with a monotonous sequence. The method has been widely accepted and recognized[29-40] as a simple, noninvasive, and powerful diagnostic and prognostic tool, and we think that assessment of spontaneous motility is a substantial part of the neurological examination. Medical staff involved in the neurological follow-up of high-risk newborn infants could benefit from the gestalt approach, which can be learned through specific training courses. Practice recognizing GMs from videotapes would enhance clinicians' abilities to detect the early signs of brain dysfunction.

Accepted for publication January 17, 2002.

This study was supported in part by the Italian Ministry of Health (Current Research Project 1994) and the ITI Company, Modena, Italy.

We thank Alberto Berardi, MD, who blindly evaluated the ultrasound scans, and Luca Ori, who made the videotapes of some infants in the intensive care unit and the outpatient clinic at the University of Modena. We also thank the staff of the neonatal intensive care unit of the University of Pisa, where some of the cases were observed, and Giovanni Battista Cavazzuti, MD (Department of Paediatrics, University of Modena), and Pietro Pfanner, MD (Department of Child Neuropsychiatry, Unversity of Pisa), for their continuous support of our research.

Corresponding author and reprints: Fabrizio Ferrari, MD, Institute of Paediatrics and Neonatal Medicine, University of Modena, Policlinico Universitario, 41100 Modena, Italy (e-mail: ferrarif@unimo.it).

REFERENCES

1. MacGillivray I, Campbell DM. The changing patterns of cerebral palsy in Avon. *Paediatr Perinat Epidemiol*. 1995;9:146-155.
2. Hagberg B, Hagberg G, Olow I, von Wendt L. The changing panorama of cerebral palsy in Sweden,V: the birth year period 1979-82. *Acta Paediatr Scand*. 1989; 78:283-290.
3. Hagberg B, Hagberg G, Olow I. The changing panorama of cerebral palsy in Sweden, VI: prevalence and origin during the birth year period 1983-86. *Acta Paediatr*. 1993;82:387-393.
4. Hagberg B, Hagberg G, Olow I, van Wendt L. Changing panorama of cerebral palsy in Sweden, VII: prevalence and origin in the birth year period 1987-90. *Acta Paediatr*. 1996;85:954-960.
5. Hagberg B, Hagberg G, Zetterstrom R. Decreasing perinatal mortality: increase in cerebral palsy morbidity? *Acta Paediatr Scand*. 1989;78:664-670.
6. Hagberg B, Hagberg G. Prenatal and perinatal risk factors in a survey of 681 Swedish cases. In: Stanley F, Alberman E, eds. *The Epidemiology of the Cerebral Palsies*. London, England: William Heinemann Medical Books; 1989:116-134. *Clinics in Developmental Medicine*; vol 87.
7. Emond A, Golding J, Peckham C. Cerebral palsy in 2 national cohort studies. *Arch Dis Child*. 1989;64:848-852.
8. Pharoah PO, Cooke T, Cooke RW, Rosenbloom L. Birthweight specific trends in cerebral palsy. *Arch Dis Child*. 1990;65:602-606.
9. Escobar GJ, Littenberg B, Petitti DB. Outcome among surviving very low birthweight infants: a meta-analysis. *Arch Dis Child*. 1991;66:F204-F211.
10. Illingworth RS. The diagnosis of cerebral palsy in the first year of life. *Dev Med Child Neurol*. 1966;8:178-194.
11. Allen M, Alexander GR. Using gross motor milestones to identify very preterm infants at risk for cerebral palsy. *Dev Med Child Neurol*. 1992;34:226-232.
12. Saint-Anne Dargassies S. Normality and normalization as seen in a long-term neurological follow-up of 286 truly premature infants. *Neuropadiatrie*. 1979;10: 226-244.
13. Saint-Anne Dargassies S. Neurodevelopmental symptoms during the first years of life. *Dev Med Child Neurol*. 1972;14:235-246.
14. Weisglas-Kuperus N, Baerts W, Sauer PJJ. Early assessment and neurodevelopmental outcome in very low birth-weight infants: implications for paediatric practice. *Acta Paediatr*. 1993;82:449-453.
15. Futagi Y, Tagawa T, Otani K. Primitive reflex profiles in infants: differences based on categories of neurological abnormality. *Brain Dev*. 1992;14:294-298.
16. Bennett FC. Developmental outcome. In: Avery GB, Fletcher MA, MacDonald G, eds. *Neonatology: Pathophysiology and Management of the Newborn*. Philadelphia, Pa: JB Lippincott Co; 1994:1367-1386.
17. Dubowitz LMS. Clinical assessment of the infant nervous system. In: Levine MJ, Bennett MJ, Punt J, eds. *Fetal and Neonatal Neurology and Neurosurgery*. Edinburgh, Scotland: Churchill Livingstone; 1988:41-58.
18. de Vries L, Dubowitz LM. Cystic leukomalacia in preterm infants: site of lesions in relation to prognosis. *Lancet*. 1985;2:1075-1076.
19. Volpe JJ. Hypoxic-ischemic encephalopathy: neuropathology and pathogenesis. In: *Neurology of the Newborn*. 3rd ed. Philadelphia, Pa: WB Saunders Co; 1995:279-313.
20. de Vries L, Regev R, Pennock JM. Ultrasound evolution and later outcome of infants with periventricular densities. *Early Hum Dev*. 1988;16:225-233.
21. Drillien CM. Abnormal neurological signs in the first year of life in low birthweight infants: possible prognostic significance. *Dev Med Child Neurol*. 1972; 14:575-584.
22. Ingram TT. The early manifestations in course of diplegia in childhood. *Arch Dis Child*. 1955;30:244-250.
23. Amiel-Tison C, Grenier A. *Neurological Evaluation of the Newborn and the Infant*. New York, NY: Masson; 1983.
24. Amiel-Tison C, Korobkin R, Esque-Vaucouloux MT. Neck extensor hypertonia: a

©2002 American Medical Association. All rights reserved.
Downloaded From: http://archpedi.jamanetwork.com/ on 05/04/2015

clinical sign of insult to the central nervous system of the newborn. *Early Hum Dev*. 1977;1:181-190.
25. Bobath B, Bobath K. *Motor Development in the Different Types of Cerebral Palsy*. London, England: William Heinemann Medical Books; 1975.
26. Hagberg B, Lundberg A. Dissociated motor development simulating cerebral palsy. *Neuropadiatrie*. 1969;1:187-199.
27. Prechtl HF. Qualitative changes of spontaneous movements in fetus and preterm infant are a marker of neurological dysfunction. *Early Hum Dev*. 1990;23:151-158.
28. Cioni G, Prechtl HF. Preterm and early postterm motor behavior in low-risk premature infants. *Early Hum Dev*. 1990;23:159-191.
29. Ferrari F, Cioni G, Prechtl HF. Qualitative changes of general movements in preterm infants with brain lesions. *Early Hum Dev*. 1990;23:193-231.
30. Albers S, Jorch G. Prognostic significance of spontaneous motility in very immature preterm infants under intensive care treatment. *Biol Neonate*. 1994;66:182-187.
31. Geerdink JJ, Hopkins B. Qualitative changes in general movements and their prognostic value in preterm infants. *Eur J Paediatr*. 1993;152:362-367.
32. Cioni G, Ferrari F, Einspieler C, Paolicelli PB, Barbani MT, Prechtl HF. Comparison between observation of spontaneous movements and neurologic examination in preterm infants. *J Pediatr*. 1997;130:704-711.
33. Bos AF, van Loon AJ, Hadders-Algra M, Martijn A, Okken A, Prechtl HF. Spontaneous motility in preterm, small-for-gestational age infants, II: qualitative aspects. *Early Hum Dev*. 1997;50:131-147.
34. Prechtl HF, Einspieler C, Cioni G, Bos AF, Ferrari F, Sontheimer D. An early marker of developing neurological deficits after perinatal brain lesions. *Lancet*. 1997;349:1361-1363.
35. Prechtl HF, Ferrari F, Cioni G. Predictive value of general movements in asphyxiated full-term infants. *Early Hum Dev*. 1993;35:91-120.
36. Ferrari F, Prechtl HF, Cioni G, et al. Posture, spontaneous movements and behavioral state organization in infants affected by brain malformation. *Early Hum Dev*. 1997;50:87-113.
37. Bos AF, Martijn A, van Asperen RM, Hadders-Algra M, Okken A, Prechtl HF. Qualitative assessment of general movements in high-risk preterm infants with chronic lung disease requiring dexamethasone therapy. *J Pediatr*. 1998;132:300-306.
38. Bos AF, Martijn A, Okken A, Prechtl HF. Quality of general movements in preterm infants with transient periventricular echodensities. *Acta Paediatr*. 1998;87:328-335.
39. Cioni G, Bos AF, Einspieler C, et al. Early neurological signs in preterm infants with unilateral intraparenchymal echodensity. *Neuropediatrics*. 2000;31:240-251.
40. Bos AF, Venema IM, Bergervoet M, Zweens MJ, Pratl B, van Eykern LA. Spontaneous motility in preterm infants treated with indomethacin. *Biol Neonate*. 2000;78:174-180.
41. Dammann O, Leviton A. Duration of transient hyperechoic image of white matter in very low birth weight infants: a proposed classification. *Dev Med Child Neurol*. 1997;39:2-5.
42. Volpe JJ. Intraventricular hemorrhage in the premature infant: current concepts, pt 2. *Ann Neurol*. 1989;25:109-116.
43. Dubowitz L, Dubowitz V. *The Neurological Assessment of the Preterm and Full-term Infant*. London, England: William Heinemann Medical Books; 1981. *Clinics in Developmental Medicine*; vol 79.
44. Prechtl HF. *The Neurological Examination of the Full-term Newborn Infant*. 2nd rev ed. London, England: William Heinemann Medical Books; 1977. *Clinics in Developmental Medicine*; vol 63.
45. Touwen BCL. *Neurological Development in Infancy*. London, England: William Heinemann Medical Books; 1976. *Clinics in Developmental Medicine*; vol 58.
46. de Vries LS, Dubowitz LM, Dubowitz V, Pennock JM. *A Colour Atlas of Brain Disorders in the Newborn*. London, England: Wolfe; 1990.
47. Griffiths R. *The Ability of Babies*. London, England: University Press, 1954.
48. Ellenberg JH, Nelson KB. Early recognition of infants at high risk for cerebral palsy: examination at age 4 months. *Dev Med Child Neurol*. 1981;23:705-716.
49. Palisano R, Rosenbaum P, Walter S, Russel S, Wood E, Galuppi B. Development and reliability of a system to classify gross motor function in children with cerebral palsy. *Dev Med Child Neurol*. 1997;39:214-223.
50. Metz CE. Basic principles of ROC analysis. *Semin Nucl Med*. 1978;8:283-298.
51. Yates F. The analysis of contingency tables with groupings based on quantitative characters. *Biometrika*. 1948;35:176-181.
52. Cioni G, Prechtl HF, Ferrari F, Paolicelli PB, Einspieler C, Roversi MF. Which better predicts later outcome in full-term infants: quality of general movements or neurological examination? *Early Hum Dev*. 1997;50:71-85.
53. Taylor HG, Klein N, Minich N, Hack M. Middle-school–age outcomes in children with very low birthweight. *Child Dev*. 2000;71:1495-1511.
54. Taylor HG, Klein N, Hack M. School age consequences of birth weight less than 750 grams: a review and update. *Dev Neuropsychol*. 2000;17:289-321.
55. Hack M, Taylor HG, Klein N, Mercuri-Minich N. Functional limitations and special health care needs of 10- to 14-year-old children weighing less than 750 grams at birth. *Pediatrics*. 2000;106:554-560.
56. Einspieler C, Prechtl HF, Ferrari F, Cioni G, Bos A. The qualitative assessment of general movements in preterm, term, and young infants: review of the methodology. *Early Hum Dev*. 1997;50:47-60.

©2002 American Medical Association. All rights reserved.
Downloaded From: http://archpedi.jamanetwork.com/ on 05/04/2015