

Intracranial Hemorrhage in Children Younger Than 3 Years

Prediction of Intent

Robert G. Wells, MD; Christine Vetter, MD; Prakash Laud, PhD

Objective: To determine whether certain computed tomographic imaging patterns in infants and young children with intracranial hemorrhage help predict intentional compared with unintentional injuries.

Design: Retrospective consecutive case series over a 10-year period.

Patients: Two hundred ninety-three children younger than 3 years with intracranial hemorrhage.

Main Outcome Measures: The sensitivity and specificity of computed tomographic imaging patterns for intentional head injury.

Setting: Regional pediatric medical center.

Results: Four variables used in the multiple logistic re-

gression analysis for predicting intentional head injury were statistically significant ($P < .05$): subdural hematoma located over the cerebral convexities, hematoma within the interhemispheric subdural space, hygroma (nonhemic subdural fluid) with intracranial hemorrhage, and absence of a skull fracture with intracranial hemorrhage. The prediction model for the diagnosis of intentional head trauma using combinations of these 4 variables and a .45 probability cutoff point indicated a sensitivity of 84% (95% confidence interval, 78%-90%) and a specificity of 83% (95% confidence interval, 74%-89%).

Conclusion: Computed tomographic imaging patterns of intracranial hemorrhage in children younger than 3 years help predict whether the injury was intentional.

Arch Pediatr Adolesc Med. 2002;156:252-257

THE DIFFERENTIATION between intentional and unintentional causes of head trauma in infants and young children is a common medical and legal dilemma. Most head trauma is caused by falls that rarely result in a significant intracranial pathologic condition; however, intentional injury is the most common cause of severe traumatic brain injury in infants.^{1,2} Billmire and Myers³ reported that 64% of infant head injuries of sufficient severity to warrant hospital admission (excluding uncomplicated skull fractures) and 95% of serious intracranial injuries are the result of child abuse. Accurate correlation of the computed tomographic (CT) findings with the reported mechanism of injury is an essential component of the care of the infant or young child with head trauma.

Results of studies based on surgical, radiological, and autopsy data suggest that different types of brain injuries tend to occur with intentional vs unintentional trauma. Most investigators believe this is caused by

a predominance of inertial forces with intentional brain injury, resulting in movement of the brain to yield concussion, edema, subdural hematoma, and diffuse axonal injury. Unintentional head trauma more often involves contact forces, which tend to produce focal injuries such as laceration, fracture, contusion, and epidural hematoma.⁴⁻⁶

We retrospectively reviewed all intracranial hemorrhages detected with CT in children younger than 3 years at our institution over a 10-year period. The main objective was to determine which CT imaging patterns help predict whether the injury was intentional.

RESULTS

PATIENT CHARACTERISTICS

The patient characteristics are summarized in **Table 1**. The study population consisted of 293 individuals, 177 male (60.4%) and 116 female (39.6%) patients. The mechanism of injury was intentional trauma

From the Radiology Department, Children's Hospital of Wisconsin, Milwaukee (Dr Wells); and the Division of Biostatistics, Medical College of Wisconsin, Milwaukee (Dr Laud). Dr Vetter is in private practice in Singapore.

PATIENTS AND METHODS

PATIENT SELECTION AND CLINICAL DIAGNOSIS

We reviewed the diagnostic imaging reports for all patients younger than 3 years who underwent cranial CT examinations at Children's Hospital of Wisconsin, Milwaukee, between February 1, 1991, and May 31, 2001. We selected all patients with radiological studies that demonstrated intracranial hemorrhage. We reviewed (blinded to the CT findings) the medical records of these children and recorded the patient's age and sex, the reported circumstances of the injury, the presence or absence of concurrent injuries, and the results of official child abuse investigations. We excluded children with hemorrhage because of prematurity, birth trauma, medical conditions, or intracranial surgical procedures. Each of the remaining patients was assigned to 1 of 3 mutually exclusive causative categories as follows: intentional injury, unintentional injury, and intent uncertain. We considered an injury to be unintentional if it was witnessed by someone other than the caretaker or there were no discrepancies between the described mechanism and the physical findings. We additionally categorized the unintentional injury group according to whether the injury was caused by a fall, motor vehicle collision, a fall in an infant walker, or by being struck by an object. We considered an injury to be intentional if there was a confession of abuse, the injuries were incompatible with the stated mechanism of injury, or the caretaker offered no explanation for the injuries. Those patients who could not clearly be assigned to the intentional or unintentional injury categories were assigned to the intent uncertain group.

CT IMAGE ANALYSIS

We reviewed (blinded to the clinical findings) the CT images of the study subjects and recorded the location of intracranial hemorrhage according to the following anatomical categories: epidural, subdural, subarachnoid,

intraventricular, and parenchymal. We recorded additional details of the intracranial hemorrhage according to the following subcategories: subdural hematoma located over the cerebral convexities, subdural hematoma located within the interhemispheric fissure, subdural hematoma in other locations, petechial parenchymal hemorrhage, and parenchymal hematoma. All study patients had at least one of these findings. In addition, the presence of subdural hygroma, brain edema, and skull fracture was recorded. For the purposes of categorization, we considered any subdural fluid collection with CT attenuation values less than those of the brain to be a hygroma. The only exceptions were hyperacute subdural hematomas (a mixture of clotted and unclotted blood), which were categorized as subdural hematomas only. Chronic subdural hematomas were included in the hygroma category. The CT imaging categories were not mutually exclusive.

PREDICTION RULE

We selected the following variables to test for an association with intentional trauma as the cause of intracranial hemorrhage: lack of an epidural hematoma, interhemispheric subdural hematoma, convexity subdural hematoma, lack of subarachnoid hemorrhage, intraventricular hemorrhage, lack of petechial hemorrhage, parenchymal hematoma, hygroma, edema, lack of a fracture, male sex, and patient age. We treated age as a continuous variable and all others as binary (yes/no) variables. Logistic regression was used to create a prediction rule; variables were studied individually and simultaneously. Our final prediction model included variables that, in the same model, had *P* values less than .05. We used this model to estimate probabilities of intentional injury based on combinations of these variables. The sensitivity and specificity for the diagnosis of intentional trauma were calculated. We then applied the model to the patients in the intent uncertain category. All calculations were performed using the LogXact software package (CYTEL Software Corp, Cambridge, Mass), which uses exact permutational distributions as opposed to the more commonly available asymptotic likelihood methods.

in 148 patients (50.5%), unintentional trauma in 109 (37.2%), and intent uncertain in 36 (12.3%). Comparing the children having intentional vs unintentional injuries, the former tended to be younger (mean age, 8.0 months vs 11.7 months, respectively) and were more frequently male (60.8% vs 55.0%, respectively).

CT IMAGING PATTERNS AND CAUSES

Four hundred sixty-nine intracranial hemorrhages classified by location were identified in the 293 study subjects. The imaging findings are correlated with the causes and are listed in **Table 2**. The most common site of hemorrhage was in the subdural spaces, identified in 184 patients (63%) (**Figure 1**). The most common type of subdural hemorrhage was in the interhemispheric region, which occurred in 143 children (49%). Most (105 patients [73%]) of these children had intentional injuries. Unintentional trauma was responsible for 21 (15%) of

the interhemispheric subdural hematomas; all were injuries associated with relatively high force—3 falls of more than 2 m, 12 motor vehicle collisions, 4 falls while in an infant walker, and 2 blows to the head.

Hemorrhage over the cerebral convexities was almost as common as interhemispheric hemorrhage, occurring in 137 children (47%). Convexity and interhemispheric subdural hematomas occurred simultaneously in 96 (52%) of the 184 patients with subdural hematoma. Intentional injury was the most common cause of convexity subdural hematoma, occurring in 99 patients (72%). Unintentional injuries accounted for only 14 (10%) of the convexity subdural hematomas; most were caused by severe injuries, such as motor vehicle collisions, falls from more than 2 m, or infant walker–stair injuries. Only 3 patients with this pattern of hemorrhage fell less than 2 m.

Acute intracranial hemorrhage with coexistent low attenuation subdural hygromas occurred in 43 patients (15% of the study population). Associated hemorrhages

Table 1. Patient Characteristics and Causes of Intracranial Hemorrhage

Causes	No. (%) of Patients	Mean Age, mo	Median Age, mo	Age SD, mo	Male Sex, No. (%)
Intentional injury	148 (50.5)	8.0	5	7.9	90 (60.8)
Unintentional injury	109 (37.2)	11.7	8	10.2	60 (55.0)
Intent uncertain	36 (12.3)	6.0	4	5.5	27 (75.0)
Total	293 (100)	9.2	6	8.8	177 (60.4)

Table 2. Computed Tomographic Imaging Findings Correlated to the Causative Categories of Injury*

Computed Tomographic Finding	Intentional Injuries	Unintentional Injuries						Intent Uncertain
		All	Fall <2 m	Fall ≥2 m	MVC†	Infant Walker–Stair Fall	Struck	
Epidural hematoma (n = 80)	14 (18)	62 (78)	28	11	5	12	6	4 (5)
Interhemispheric subdural hematoma (n = 143)	105 (73)	21 (15)	0	3	12	4	2	17 (12)
Convexity subdural hematoma (n = 137)	99 (72)	14 (10)	3	1	5	3	2	24 (18)
Other subdural hematoma (n = 10)	7 (70)	3 (30)	0	0	1	1	1	0
Subarachnoid hemorrhage (n = 36)	12 (33)	22 (61)	5	4	10	2	1	2 (6)
Intraventricular hemorrhage (n = 13)	6 (46)	6 (46)	1	1	4	0	0	1 (8)
Petechial hemorrhage (n = 45)	15 (33)	27 (60)	7	6	10	2	2	3 (7)
Parenchymal hematoma (n = 5)	1 (20)	1 (20)	0	0	1	0	0	3 (60)
Hygroma (n = 43)	35 (81)	0	0	0	0	0	0	8 (19)
Edema (n = 85)	66 (78)	11 (13)	0	0	8	1	2	8 (9)
Fracture (n = 140)	43 (31)	90 (64)	33	17	14	16	10	7 (5)

*Data are given as the number (row percentage) of patients unless otherwise indicated.

†MVC indicates motor vehicle collision.

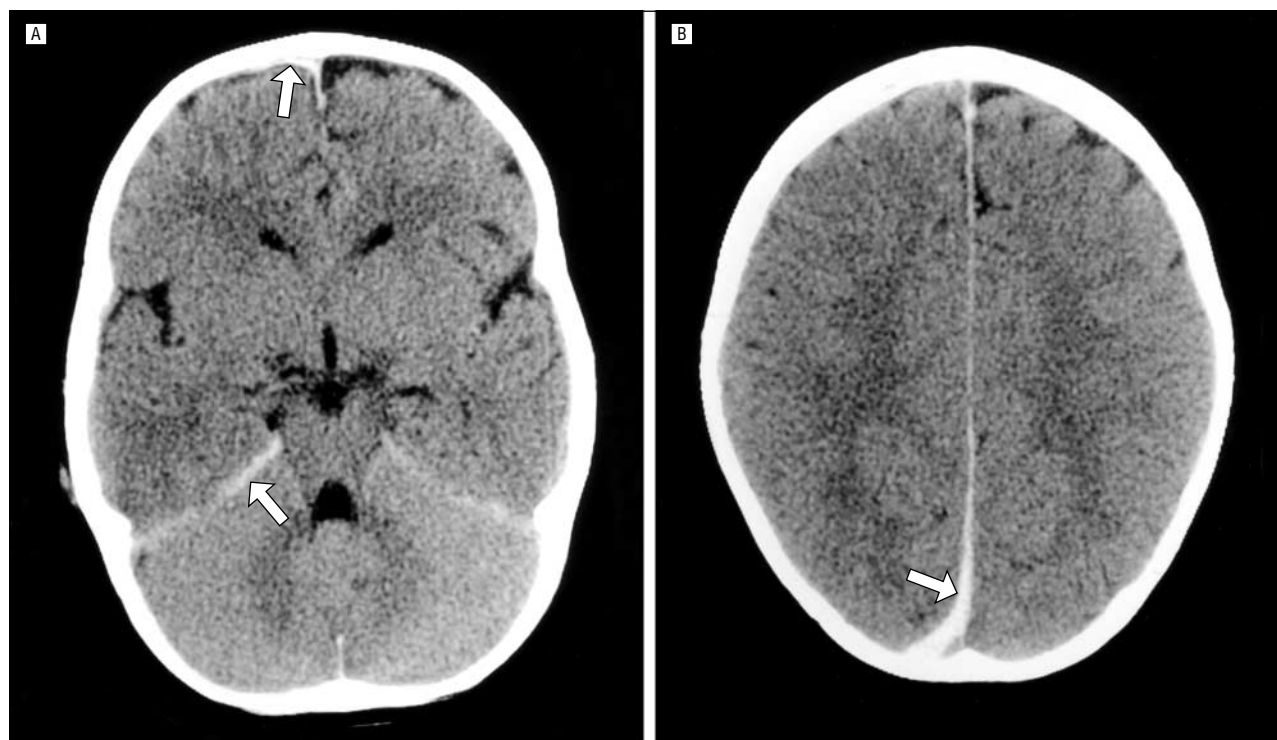


Figure 1. Common computed tomographic (CT) findings with intentional trauma. An 18-month-old boy was shaken and thrown to the floor by his mother's boyfriend 3 hours prior to the CT examination. Subsequent CT imaging (not shown) demonstrated worsening edema over the next few days. The child died 5 days later. A, Note the acute convexity subdural hemorrhage adjacent to the right frontal lobe and along the tentorium (arrows). B, A more superior CT image shows a right posterior interhemispheric subdural hematoma (arrow).

included 1 epidural hemorrhage, 29 interhemispheric subdural hematomas, 37 convexity subdural hematomas, 1 subarachnoid hemorrhage, 1 petechial hemorrhage, and 1 intraventricular hemorrhage. All patients with hygro-

mas were in the intentional injury or intent uncertain categories.

Epidural hematomas occurred in 80 patients (27%). Epidural hematomas were most frequently associated with

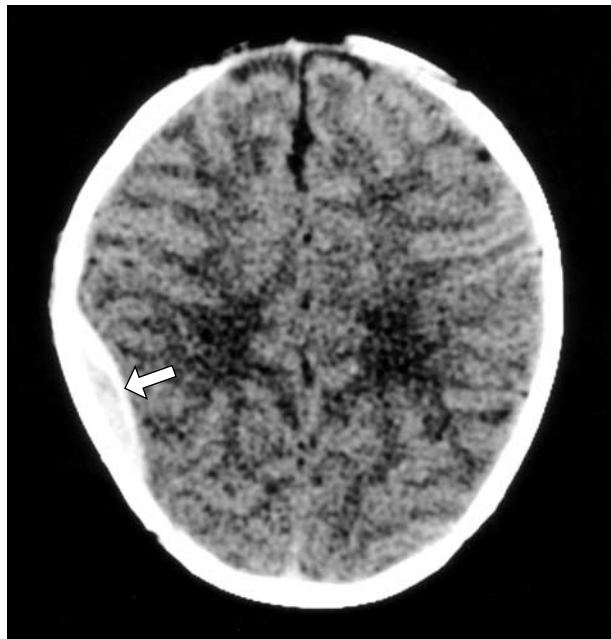


Figure 2. Common computed tomographic (CT) appearance of unintentional head trauma. A small (probably venous) epidural hematoma is present on the right side (arrow) in a 16-day-old boy who had fallen from his mother's arms onto a concrete floor. Bone windows (not shown) demonstrated a skull fracture. This hematoma resolved without surgical evacuation, and the child made a complete clinical recovery.

unintentional injuries (62 patients [78%]) and were uncommon with intentional injury (14 patients [18%]). Thirty-nine epidural hematomas (63%) related to unintentional injury were caused by a fall. Most of the epidural hematomas were small, and not associated with other injuries; 69 (86%) were less than 1 cm thick and were isolated (**Figure 2**).

Subarachnoid hemorrhage occurred in 36 patients (12%); a coexisting intracranial injury (edema or other area of hemorrhage) was identified in 27 (75%) of these 36 patients. Unintentional injuries were more common than intentional injuries in patients with subarachnoid hemorrhage (61% vs 33%). Nine (41%) of the 22 patients with subarachnoid hemorrhage who had unintentional injuries had fallen; 10 (45%) were involved in motor vehicle collisions.

Petechial parenchymal hemorrhage was identified in 45 (15%) of the 293 patients. Twenty-seven patients (60%) with petechial hemorrhage had unintentional trauma and 15 (33%) had intentional trauma. Thirty-two patients (71%) with petechial hemorrhage had a skull fracture.

Edema accompanied intracranial hemorrhage in 85 patients (29%). In 80 patients (94%) the edema occurred in conjunction with an interhemispheric subdural hematoma or a convexity subdural hematoma. Sixty-six patients (78%) with edema were classified in the intentional injury category.

A skull fracture was identified in 140 patients (48%). Seventy-nine (99%) of the 80 patients with an epidural hematoma had a skull fracture. Forty-three (29%) of the 148 patients having a diagnosis of intentional trauma had a skull fracture.

Table 3. Logistic Regression Analysis of Variables Studied Individually for a Diagnosis of Intentional Trauma

Variable	Univariate Odds Ratio	95% Confidence Interval of the Univariate Odds Ratio	Multiple Regression P Values*
No epidural hematoma	12.7	6.5-24.7	.93
Interhemispheric subdural hematoma	9.9	5.5-17.9	<.001
Convexity subdural hematoma	13.7	7.1-26.4	<.001
No subarachnoid hemorrhage	2.9	1.3-6.1	.24
Intraventricular hemorrhage	0.7	0.2-2.3	.22
No petechial hemorrhage	2.9	1.5-5.8	.96
Parenchymal hematoma	0.7	0.05-11.9	.99
Hygroma	42.3	2.0-∞	<.001
Edema	7.2	3.5-14.5	.19
No fracture	11.6	6.3-21.4	<.001
Male	0.8	0.5-1.3	.99
Age†	0.96	0.929-0.983	.14

*Reported P values are for individual variables controlling for all significant variables in the final model.

†For the continuous variable age (in months), the odds ratio represents the relative change in odds of intentional injury for 1-SD change in age. The SD of age is 9.11 months.

Table 4. Multiple Logistic Regression Analysis for a Diagnosis of Intentional Trauma

Variable	Odds Ratio (95% Confidence Interval)	Regression Coefficients*
Hygroma	47.4 (7.6-∞)†	3.86
Convexity subdural hematoma without hygroma	4.4 (1.9-10.2)	1.47
No fracture	4.3 (2.0-9.5)	1.46
Interhemispheric subdural hematoma	3.7 (1.7-8.2)	1.32

*The intercept equals -1.66. All variables are binary, with 1 representing yes to the column 1 finding and 0 representing no.

†There is no upper limit on the confidence interval for hygroma because all of these patients were in the intentional injury category.

PREDICTION RULE

The logistic regression analysis results are given in **Table 3**. Evaluation of the variables individually showed P values less than .05 for all variables except intraventricular hemorrhage, parenchymal hematoma, and male sex. However, in multiple regression, only 4 variables were statistically significant: convexity subdural hematoma, interhemispheric subdural hematoma, lack of a skull fracture, and hygroma. The final model is summarized in **Table 4**. Note that the hygroma and no fracture variables include the requirement for coexistent acute intracranial hemorrhage. The model is based on the imaging findings at the time of clinical presentation; therefore, patients with intracranial hemorrhage who subse-

Table 5. Model-Based Estimates of Probabilities of Intentional Trauma*

Convexity Subdural Hematoma Without Hygroma	Hygroma	Interhemispheric Subdural Hematoma	Skull Fracture	Patients With Finding(s), No.	Patients With Intentional Trauma, No.	Probability of Intentional Trauma
No	Yes	Yes	No	18	18	.993
No	Yes	No	No	6	6	.975
No	Yes	Yes	Yes	5	5	.971
Yes	No	Yes	No	46	42	.930
Yes	No	Yes	No	46	42	.930
No	Yes	No	Yes	3	3	.900
Yes	No	No	No	17	13	.781
Yes	No	Yes	Yes	17	13	.756
No	No	Yes	No	26	21	.753
Yes	No	No	Yes	6	4	.453
No	No	No	No	11	5	.450
No	No	Yes	Yes	13	5	.415
No	No	No	Yes	89	13	.160

*A .45 cutoff point prediction rule (combinations above the double line) gives a sensitivity of 84% (95% confidence interval, 78%-90%) and a specificity of 83% (95% confidence interval, 74%-89%).

quently develop hygromas should not be considered to have a hygroma when applying the prediction rule.

The model-based estimates of the probabilities of intentional trauma according to combinations of the 4 selected variables are listed in **Table 5**. To maximize both sensitivity and specificity, we classified patients as having intentional injuries when their predicted probability of intentional injury in the logistic model was greater than .45. Using this cutoff point, the sensitivity of the prediction model for the diagnosis of intentional trauma is 84% (95% confidence interval, 78%-90%) and the specificity is 83% (95% confidence interval, 74%-89%). The cutoff point was selected to provide a reasonable balance between the sensitivity and specificity. Application of the prediction rule to the patients in the intent uncertain category estimates that 25 (69%) of the 36 patients had intentional trauma.

COMMENT

We propose a prediction rule for the diagnosis of intentional trauma in children younger than 3 years with intracranial hemorrhage. The model requires the exclusion on clinical grounds of patients with hemorrhage due to prematurity, birth trauma, surgery, or nontraumatic medical causes. No other clinical information is assumed. We thus attempted to reproduce the common clinical scenario at the time of presentation of the infant or young child with head trauma, when the available objective clinical information is incomplete and the reported history of the injury may be viewed with some skepticism.

The 4 variables that exhibited statistical significance in multiple logistic regression are compatible with the work of other investigators and theoretical considerations. The common occurrence of subdural hemorrhages and lack of skull fractures support the concept that acceleration-deceleration forces predominate with intentional head injuries. Unintentional injuries more often involve translational forces, thereby favoring skull fractures and epidural hematomas. The association of hygroma with the diagnosis of intentional trauma sup-

ports the medical dictum that acute intracranial hemorrhage in combination with nonhemic subdural fluid (eg, acute and chronic subdural hematomas) indicates that at least 2 significant episodes of trauma have occurred, unless there is a clear history of a preexisting medical condition that resulted in a subdural effusion or hygroma.

To our knowledge, this article reports the largest case series in the medical literature to investigate the correlation between CT imaging findings and causes of intracranial hemorrhage in infants and young children. There are, however, several limitations of this study. A validation sample to test the predication rule is lacking. The outcome event, intentional trauma, is subject to variations in medical, legal, and societal definitions. The creation of the prediction rule assumes that the predictive findings were defined properly and accurately assessed, that is, the CT images were properly interpreted. Clinical usefulness of the model requires others using the prediction rule to use the same definitions of the significant variables.

The separation of the assessment of outcome and clinical prediction is imperfect in this study. We were blinded to the CT imaging findings while reviewing the medical records and assigning a diagnosis (the outcome). However, the clinicians and social service professionals who investigated the circumstances of the injuries were aware of, and likely influenced by, the CT imaging findings. This potential error is mitigated by the use of objective factors to assure a correct diagnosis of intentional injury, such as a confession by the perpetrator, or the presence of suspicious skeletal injuries, retinal hemorrhages, or soft tissue injuries. Other limitations are (1) the lack of uniformity in the veracity of investigation among the subjects in this retrospective study, and (2) the potential influence of the CT findings on the clinical decision regarding initiation of a formal child abuse investigation.

Specific confirmatory information in the medical literature for our findings is lacking; we could find no reports proposing a prediction rule for neuroimaging findings in the diagnosis of intentional injury. Several studies evaluating head trauma in abused children have shown

What This Study Adds

The neuroimaging findings for infants and young children with traumatic intracranial hemorrhage provide important clues to the mechanism of the injury. Several studies of children having intentional trauma have shown a high incidence of subdural hematoma; however, the sensitivity and specificity of this and other specific patterns of intracranial injury for the diagnosis of intentional trauma is unknown. In this study, we evaluated the CT imaging findings in 293 children younger than 3 years who had intracranial hemorrhage. We propose a prediction model for the diagnosis of intentional trauma based on 4 CT imaging patterns.

a high incidence of subdural hematoma.⁷⁻⁹ Zimmerman et al⁹ first reported the important correlation between child abuse and subdural hemorrhage in the interhemispheric space; this has been confirmed by other investigators.¹⁰ There is wide variation in the reported incidence of chronic nonhemispheric subdural fluid collections with intentional head trauma, although the correlation is widely accepted.¹¹⁻¹³

There are a few series in the medical literature that compare head injuries in children having intentional vs unintentional trauma that include statistical analysis of the results. Ewing-Cobbs et al¹⁴ evaluated 60 patients between 0 and 6 years of age who had brain injuries and found significantly ($P < .05$) more subdural hematomas and hygromas in the patients with intentional injuries than in those with unintentional injuries. Duhaime et al¹⁵ studied 100 children 24 months of age and younger who were admitted to the hospital with head trauma and found a statistically significant ($P < .001$) relationship between intentional injury and the presence of intradural (subdural, subarachnoid, contusion) hemorrhage. Hymel et al¹⁰ found interhemispheric hemorrhage, subdural hemorrhage, "large (nonacute) extra-axial fluid," and basal ganglia edema to occur significantly more frequently ($P \leq .05$) in 39 children having a diagnosis of intentional trauma than in the control group of 39 patients with unintentional injuries. Reece and Sege¹⁶ evaluated 195 children younger than 3 years who had head trauma and found that hemorrhage in the subdural and subarachnoid spaces occurred with a significantly ($P = .001$) higher incidence in patients with intentional injuries.

Application of the prediction rule to the study patients in the intent uncertain group estimates that 69% of these children had had intentional injuries. This is in keeping with the findings of other investigators that child abuse is significantly underdiagnosed.¹⁷

CONCLUSIONS

Intentional trauma is the most common cause of intracranial hemorrhage in children younger than 3 years. The subdural space is the most common location of intracranial hemorrhage in children of this age group. Although all severe head injuries in infants and young children must be viewed with a high index of suspicion for intentional trauma, the CT imaging findings that are most useful in differentiating intentional from unintentional causes in those children with intracranial hemorrhage are convexity subdural hematoma, interhemispheric subdural hematoma, nonhemispheric subdural fluid (hygroma), and lack of a skull fracture.

Accepted for publication October 22, 2001.

Corresponding author and reprints: Robert G. Wells, MD, Radiology Department, MS 721, Children's Hospital of Wisconsin, 9000 W Wisconsin Ave, PO Box 1997, Milwaukee, WI 53201 (e-mail: rwells@chw.org).

REFERENCES

1. *Study of the National Incidence and Prevalence of Child Abuse and Neglect: 1988*. Washington, DC: National Center on Child Abuse and Neglect; 1988.
2. DiScala C, Sege R, Li G, Reece RM. Child abuse and unintentional injuries: a 10-year retrospective. *Arch Pediatr Adolesc Med*. 2000;154:16-22.
3. Billmire ME, Myers PA. Serious head injury in infants: accident or abuse? *Pediatrics*. 1985;75:340-342.
4. Ewing-Cobbs L, Kramer L, Prasad M, et al. Neuroimaging, physical, and developmental findings after inflicted and noninflicted traumatic brain injury in young children. *Pediatrics*. 1998;102(pt 1):300-307.
5. Duhaime AC, Gennarelli TA, Thibault LE, Bruce DA, Margulies SS, Wiser R. The shaken baby syndrome: a clinical, pathological, and biomechanical study. *J Neurosurg*. 1987;66:409-415.
6. Gennarelli TA, Thibault LE. Biomechanics of acute subdural hematoma. *J Trauma*. 1982;22:680-686.
7. Tsai FY, Zee CS, Apthorp JS, Dixon GH. Computed tomography in child abuse head trauma. *J Comput Tomogr*. 1980;4:277-286.
8. Merten DF, Osborne DR, Radkowski MA, Leonidas JC. Craniocerebral trauma in the child abuse syndrome: radiological observations. *Pediatr Radiol*. 1984;14:272-277.
9. Zimmerman RA, Bilaniuk LT, Bruce D, Schut L, Uzzell B, Goldberg HI. Computed tomography of craniocerebral injury in the abused child. *Radiology*. 1979;130:687-690.
10. Hymel KP, Rumack CM, Hay TC, Strain JD, Jenny C. Comparison of intracranial computed tomographic (CT) findings in pediatric abusive and accidental head trauma. *Pediatr Radiol*. 1997;27:743-747.
11. Duhaime AC, Christian CW, Rorke LB, Zimmerman RA. Nonaccidental head injury in infants—the "shaken-baby syndrome" [review]. *N Engl J Med*. 1998;338:1822-1829.
12. Zimmerman RA, Bilaniuk LT. Pediatric head trauma [review]. *Neuroimaging Clin N Am*. 1994;4:349-366.
13. Aoki N. Chronic subdural hematoma in infancy: clinical analysis of 30 cases in the CT era. *J Neurosurg*. 1990;73:201-205.
14. Ewing-Cobbs L, Prasad M, Kramer L, et al. Acute neuroradiologic findings in young children with inflicted or noninflicted traumatic brain injury. *Childs Nerv Syst*. 2000;16:25-34.
15. Duhaime AC, Alario AJ, Lewander WJ, et al. Head injury in very young children: mechanisms, injury types, and ophthalmologic findings in 100 hospitalized patients younger than 2 years of age. *Pediatrics*. 1992;90(pt 1):179-185.
16. Reece RM, Sege R. Childhood head injuries: accidental or inflicted? *Arch Pediatr Adolesc Med*. 2000;154:11-15.
17. Jenny C, Hymel KP, Ritzen A, Reinert SE, Hay TC. Analysis of missed cases of abusive head trauma. *JAMA*. 1999;281:621-626.