SECTION EDITOR: SAMIR S. SHAH, MD, MSCE

Picture of the Month

Raghu Varier, DO; Jenifer Butler, MD; Douglas Rivard, DO; Stephanie L. Page, MD

A 13-YEAR-OLD GIRL PRESENTED WITH A 2-week history of sharp, intermittent, periumbilical abdominal pain. The pain does not radiate; activity worsens the pain, whereas rest alleviates it. The pain is neither worsened by eating nor relieved by defecation. She reports approximately 6 episodes of nonbloody and nonbilious vomiting during these 2 weeks. She reports normal daily bowel movements. There has been no change in the frequency or volume of her stools since the onset of abdominal pain, but she has had occasional loose stools. She denies hematochezia and constipation, but says that occasionally she will feel the need to defecate but cannot. She has had a 3.15-kg (7-lb) weight loss in the past 3 months. She also describes recent onset of malaise and chills. She denies any rash, joint pain, or fever.

On examination, she is afebrile. There is mild tenderness in the right lower abdominal quadrant with no rebound tenderness or guarding. The remainder of her physical examination is normal. Laboratory investigation reveals an elevated erythrocyte sedimentation rate of 37 mm/h (normal, 0-13 mm/h) and an elevated C-reactive protein level of 3.6 mg/dL (normal, 0.0-1.0 mg/dL [to convert to nanomoles per liter, multiply by 9.524]). Complete blood cell count and basic metabolic profile are unremarkable. An upper gastrointestinal series with barium contrast suggests a diagnosis (**Figure 1** and **Figure 2**).

Author Affiliations: Departments of Pediatrics (Drs Varier, Butler, and Page) and Radiology (Dr Rivard), Children's Mercy Hospitals and Clinics and The University of Missouri–Kansas City.

See http://www.archpediatrics.org for the Picture of the Month Web Quiz: What is your diagnosis?

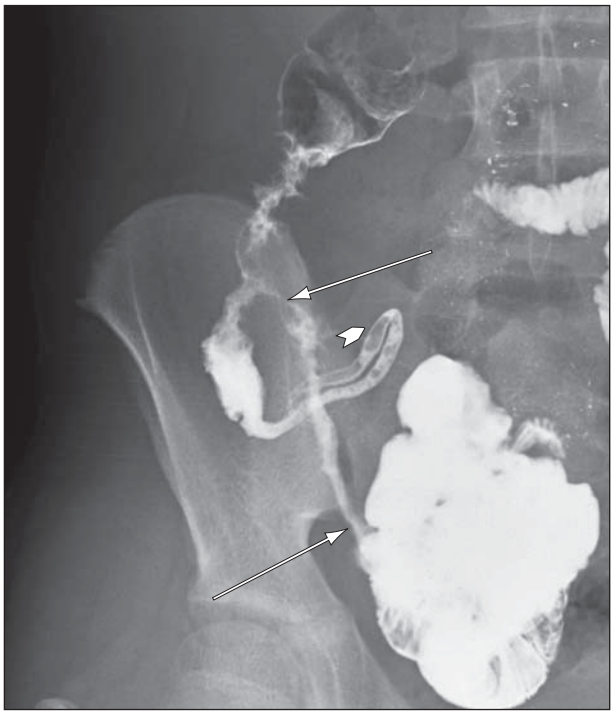

Figure 1. Anteroposterior radiographic image of the abdomen taken 3 hours after oral administration of enteric contrast showing diffuse nodular mucosal thickening and narrowing of a segment of distal ileum with adjacent similar changes in the cecum (arrows). Incidentally noted is a normal appendix (arrowhead).

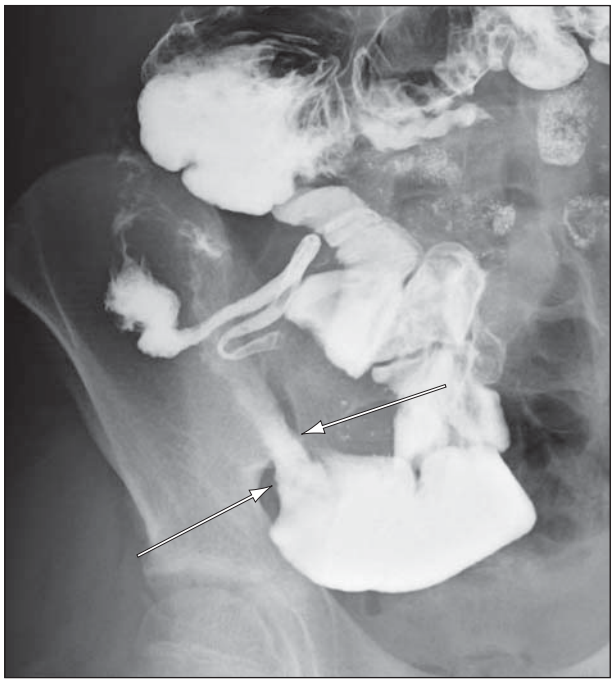

Figure 2. Anteroposterior radiographic image of the abdomen taken 4 hours after oral administration of enteric contrast showing a transition zone (arrows) between dilated proximal loops of ileum and the narrowed terminal ileum.

©2011 American Medical Association. All rights reserved.
Downloaded From: http://archpedi.jamanetwork.com/ on 07/03/2015