ARTICLE

High-Altitude Pulmonary Edema in Children With Underlying Cardiopulmonary Disorders and Pulmonary Hypertension Living at Altitude

Bibhuti B. Das, MD; Robert R. Wolfe, MD; Kak-Chen Chan, MD; Gary L. Larsen, MD; John T. Reeves, MD†; Dunbar Ivy, MD

Background: Pulmonary hypertension has not been described as a predisposing risk factor for high-altitude pulmonary edema (HAPE) in children. Previous studies have shown an association of HAPE with abnormally increased pulmonary vasoreactivity to hypoxia but generally normal pulmonary artery pressure (PAP) after recovery.

Objective: To describe HAPE of relatively rapid onset and its management in a series of children residing at moderate to high altitudes, all of whom had underlying pulmonary hypertension.

Methods and Results: From 1997 to 2003, 30 children came to our center with high-altitude illness. Of these, 10 children (aged 4-18 years; male-female ratio, 8:2) living at moderate to high altitudes (1610-3050 m) underwent cardiac catheterization after recovery from HAPE, and all were found to have chronic pulmonary hypertension (mean PAP, 38±9 mm Hg; pulmonary vascular resistance, 8.6±2.8 U×m^2). Increases in PAP and pulmonary vascular resistance to hypoxia (16% oxygen) suggest that these children have a reactive pulmonary pressor response and hence are susceptible to HAPE. Six of the 10 patients had predisposing cardiopulmonary abnormalities, and 5 of these 6 patients did not receive a diagnosis prior to the onset of HAPE. Long-term treatment with calcium channel blockers, bosentan, sildenafil citrate, and/or oxygen lowered PAP, improved symptoms, and prevented the recurrence of HAPE.

Conclusion: Children living at altitude who develop HAPE should undergo screening for diagnosis of underlying cardiopulmonary abnormalities including pulmonary hypertension.

Arch Pediatr Adolesc Med. 2004;158:1170-1176

Author Affiliations:
Department of Pediatrics, Sections of Cardiology (Drs Das, Wolfe, Chan, and Ivy) and Pulmonary Medicine (Dr Larsen), The Children's Hospital, and Section of Critical Care (Dr Reeves); University of Colorado Health Science Center, Denver.
†Deceased.

CLASSICALLY, HIGH-ALTITUDE pulmonary edema (HAPE) is a form of acute noncardiogenic pulmonary edema caused by altitude-related hypoxia. High-altitude pulmonary edema occurs in previously healthy persons on rapid ascent to altitude higher than 2450 m (nonresident-ascent HAPE).[1] Reentry (resident-reascent) HAPE affects residents of high altitude when they descend to lower altitude and then return to high altitude.[2] Although reentry HAPE is more common in children than adults,[2] little is known about the conditions predisposing to its development. Anecdotal reports suggest that some pediatric patients may develop HAPE in association with conditions that might include pulmonary hypertension (PH) such as bronchopulmonary dysplasia,[3] cystic fibrosis,[3] hypoventilation syndrome,[3] congenital heart diseases,[3] and Down syndrome.[4] However, no corroborating pulmonary artery pressure (PAP) data were presented in these reports. It is unclear whether the presence of PH should protect or predispose to the development of HAPE.

Conventional wisdom has suggested that chronic hypoxia at high altitude increases the thickness of the pulmonary arteriole walls and narrows the lumen, decreases pulmonary blood flow, and thus should protect the capillary bed from overperfusion and hence pulmonary edema. Consequently, PH and vascular remodeling should protect the lungs from developing HAPE. We identified 10 children living at moderate to high altitudes (moderate altitude defined as 1400-2400 m and high altitude >2400 m)[5] with rapid onset of HAPE. Therefore, we sought to determine under what circumstances these children living at high altitude develop HAPE. All had underlying PH, and its management is described.

METHODS

Ten patients with HAPE were identified of 30 patients who had been diagnosed with HAPE

©2004 American Medical Association. All rights reserved.
Downloaded From: http://archpedi.jamanetwork.com/ on 08/29/2014

Table 1. Summary of Demographic Data and Risk Factors of 10 Patients With High-Altitude Pulmonary Edema (HAPE) and Pulmonary Hypertension Living at Altitude*

Patient	No. of HAPE Episodes	Interval From HAPE to Catheterization, mo	Mean PAP, mm Hg	Resident Altitude, m	Change in Altitude, m	Time to Onset of HAPE, h	Risk Factors
				Reentry HAPE			
1	1	6	25	3050	1440	12	URI
2	3	12	25	3050	1620	24	NA
3	2	6	45	2750	1850	24	NA
4	2	4	41	3050	2500	24	Family history of high-altitude sickness
				Ascent HAPE			
5	1	6	31	1610	1040	12	Obstructive sleep apnea
6	1	3	31	1610	1440	12	"Absent" RPA
7	2	12	45	2000	730	12	"Absent" LPA; URI
8	>12	12	28	2450	1440	12	Atrial septal defect
9	3	12	48	1610	1220	12	COA; VSD
10	2	12	40	1610	520	12	Pulmonary vein stenosis

Abbreviations: COA, coarctation of the aorta; LPA, left pulmonary artery; NA, not applicable; PAP, pulmonary artery pressure; RPA, right pulmonary artery; URI, upper respiratory tract infection; VSD, ventricular septal defect.

*Interval from HAPE to catheterization indicates the period after the last episode of HAPE to when cardiac catheterization was done. Time to onset of HAPE indicates the hours until onset of HAPE after a visit to a new altitude or return to home altitude.

and other high-altitude related illness between 1997 and 2003 from the medical record database at The Children's Hospital, Denver, Colo. Diagnosis of HAPE was made on the basis of dyspnea, hypoxemia, infiltrates on chest radiographs consistent with pulmonary edema, and response to oxygen therapy with rapid relief of symptoms and clearing of infiltrates. Of these 30 children, 10 (the study group) were enrolled in an institutional review board–approved study entitled "A Prospective Longitudinal Study of Childhood Pulmonary Hypertension" for further evaluation. The selection criteria for patients included in the study were right ventricular hypertrophy (RVH) on electrocardiogram (ECG) and evidence of PH on echocardiogram. Echocardiographic estimates of systolic PAP used the velocity of tricuspid regurgitation jet when present.[6] Pulmonary hypertension is defined as a mean PAP higher than 25 mm Hg at rest.

CARDIAC CATHETERIZATION AND HEMODYNAMICS STUDIES

All 10 patients underwent standard right- and left-side heart catheterization at altitude of 1610 m. Aortic pressure, PAP, blood gases, pulmonary capillary wedge pressure, right atrial pressure, cardiac index, and pulmonary and systemic vascular resistance were obtained in room air (RA) and then during hypoxic challenge, breathing 16% fraction of inspired oxygen for 5 to 10 minutes. Eight of the 10 patients had repeat measurements while breathing a mixture of 100% oxygen and 20 ppm nitric oxide for 5 to 10 minutes.[7] In 8 patients, intravenous diltiazem hydrochloride (0.25 mg/kg) was administered, and in 5 of these studies, the hypoxic challenge was repeated afterward. There were no complications (**Table 1** and **Table 2**).

STATISTICAL ANALYSIS

Statistical analysis was performed using a 1-way analysis of variance. The hemodynamic data and blood gas parameters at 16% and 100% fraction of inspired oxygen and nitric oxide were compared with the corresponding parameters during RA breathing. Data are presented as mean and standard deviation. *P* values less than .05 are considered statistically significant.

PATIENT REPORTS

PATIENT 1

A 4-year-old girl living at 3050 m had an upper respiratory tract illness for 2 days and then visited an altitude of 1610 m for 48 hours. Within 12 hours of her return home, she developed cough and breathlessness and became hypoxemic (arterial oxygen saturation, 50%). High-altitude pulmonary edema was confirmed by chest x-ray film, and an echocardiogram-estimated systolic PAP of 50 mm Hg. After 48 hours of oxygen treatment, she became asymptomatic and was discharged home. Six months after hospital discharge because of persistent signs of PH, she underwent cardiac catheterization. Her PAP during RA breathing was 50/15 mm Hg, which increased to 88/31 mm Hg during hypoxic challenge and fell to 35/5 mm Hg during vasodilation. After diltiazem administration, her PAP decreased to 36/16 mm Hg, and repeat hypoxic challenge after diltiazem administration showed a rise in PAP to 72/43 mm Hg. Receiving treatment with nocturnal oxygen and calcium channel blockade, she has remained well, and after 2 years, repeat echocardiography estimated a systolic PAP of 40 mm Hg.

PATIENT 2

A 6-year-old boy, born and living at 3050 m, was referred for cardiac catheterization because of a history of 3 episodes of HAPE (each following reascent home from 1620 m, after a stay of 24 to 48 hours), RVH on ECG, and poor exercise tolerance. Cardiac catheterization was performed 1 year after the last episode of HAPE. While breathing RA, he had an elevated PAP of 60/26 mm Hg.

©2004 American Medical Association. All rights reserved.
Downloaded From: http://archpedi.jamanetwork.com/ on 08/29/2014

Table 2. Hemodynamic and Blood Gas Data of Patients 1 Through 9 During Assessment of Pulmonary Vascular Reactivity*

	Room Air (n = 9)	16% Oxygen Administration (n = 7)	100% Oxygen and Nitric Oxide Administration (n = 8)	Diltiazem Hydrochloride Administration (n = 8)	Diltiazem and 16% Oxygen Administration (n = 5)
PAP, mm Hg	38 ± 9	58 ± 7†	21 ± 6†	28 ± 9†	29 ± 9†
AOP, mm Hg	86 ± 17	84 ± 19	80 ± 12	73 ± 10	80 ± 10
PCWP, mm Hg	7 ± 1	7 ± 1	9 ± 2	NA	NA
RAP, mm Hg	6 ± 3	6 ± 3	6 ± 3	NA	NA
CI, L/min per m^2	4.1 ± 2	4.4 ± 2	4.8 ± 2	NA	NA
PVRI, U × m^2	8.6 ± 2.8	12.8 ± 3.9†	3.0 ± 0.6†	4.4 ± 1.7†	8.6 ± 3.5
SVRI, U × m^2	24.1 ± 8	23.0 ± 7.3	19.3 ± 4.8†	13.3 ± 5.4†	17.7 ± 1.6†
pH	7.36 ± 0.04	7.37 ± 0.04	7.37 ± 0.03	7.36 ± 0.03	7.38 ± 0.04
Pa_{CO_2}, mm Hg	39 ± 4	42 ± 6	41 ± 6	39 ± 8	36 ± 5
Pa_{O_2}, mm Hg	76 ± 13	47 ± 5	205 ± 111†	95 ± 31	48 ± 5

Abbreviations: AOP, aortic pressure; CI, cardiac index (cardiac output per body surface area in meters squared); NA, not applicable; PAP, pulmonary artery pressure; PCWP, pulmonary capillary wedge pressure;
PVRI, pulmonary vascular resistance index; RAP, right atrial pressure; SVRI, systemic vascular resistance index.
*All values are expressed as mean ± SD.
†$P<.05$ vs room air.

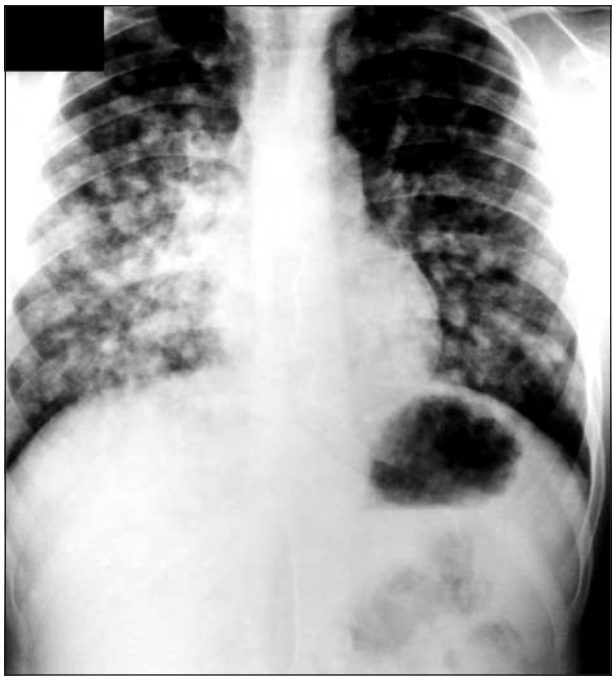

Figure 1. Chest radiograph from patient 3, showing classic "mothball" appearance suggestive of high-altitude pulmonary edema.

His pressure increased to 70/46 mm Hg during hypoxic challenge and fell to 34/11 mm Hg during administration of vasodilation. After diltiazem administration, his PAP was 36/12 mm Hg, with a blunting of the rise in PAP during repeat hypoxic challenge. The family moved to 1450 m, and receiving treatment with nocturnal oxygen and a calcium channel blocker, he has remained asymptomatic.

PATIENT 3

An 8-year-old boy, who lived at 2750 m and who had poor exercise tolerance, developed radiographic evidence of HAPE (**Figure 1**) on 2 occasions after returning home from a 36-hour visit to altitude of 1850 m. An ECG showed RVH. At cardiac catheterization 6 months after the last episode of HAPE, while breathing RA, he had an elevated PAP of 64/28 mm Hg. His pressure fell to 37/19 mm Hg during administration of vasodilation. After diltiazem administration, his PAP was 44/18 mm Hg. Fourteen months later, while living at sea level and receiving treatment with a calcium channel blocker, an echocardiogram showed an estimated PAP of 32 mm Hg. His exercise tolerance has improved.

PATIENT 4

A 10-year-old girl, living at 3050 m, was referred to The Children's Hospital because of a history of 2 episodes of HAPE, each following reascent home (3050 m) from 550 m; family history (brother and father) of high-altitude sickness; history of chest pain; and decreased exercise tolerance. The ECG showed significant RVH. An echocardiogram failed to assess the PAP owing to absence of tricuspid regurgitation. Cardiac catheterization was performed 4 months after the last episode of HAPE. While breathing RA, she had an elevated PAP of 55/21 mm Hg. Her PAP increased to 94/67 mm Hg during hypoxic challenge and fell to 28/13 mm Hg during administration of vasodilation. After diltiazem administration, her PAP was 41/15 mm Hg, with a blunting of the rise in PAP during repeat hypoxia challenge (PAP, 50/20 mm Hg). The family has moved to lower altitude, and the patient, her brother, and her father still take calcium channel blockers.

PATIENT 5

A 15-year-old boy, residing at 1610 m, went hunting at altitude of 2650 m, where during his first night he was awakened by breathlessness and cough. He was found to have hypoxemia (oxygen saturation, 60%) and radiographic signs consistent with HAPE. He was obese (108 kg), and a sleep study showed obstructive sleep apnea.

©2004 American Medical Association. All rights reserved.
Downloaded From: http://archpedi.jamanetwork.com/ on 08/29/2014

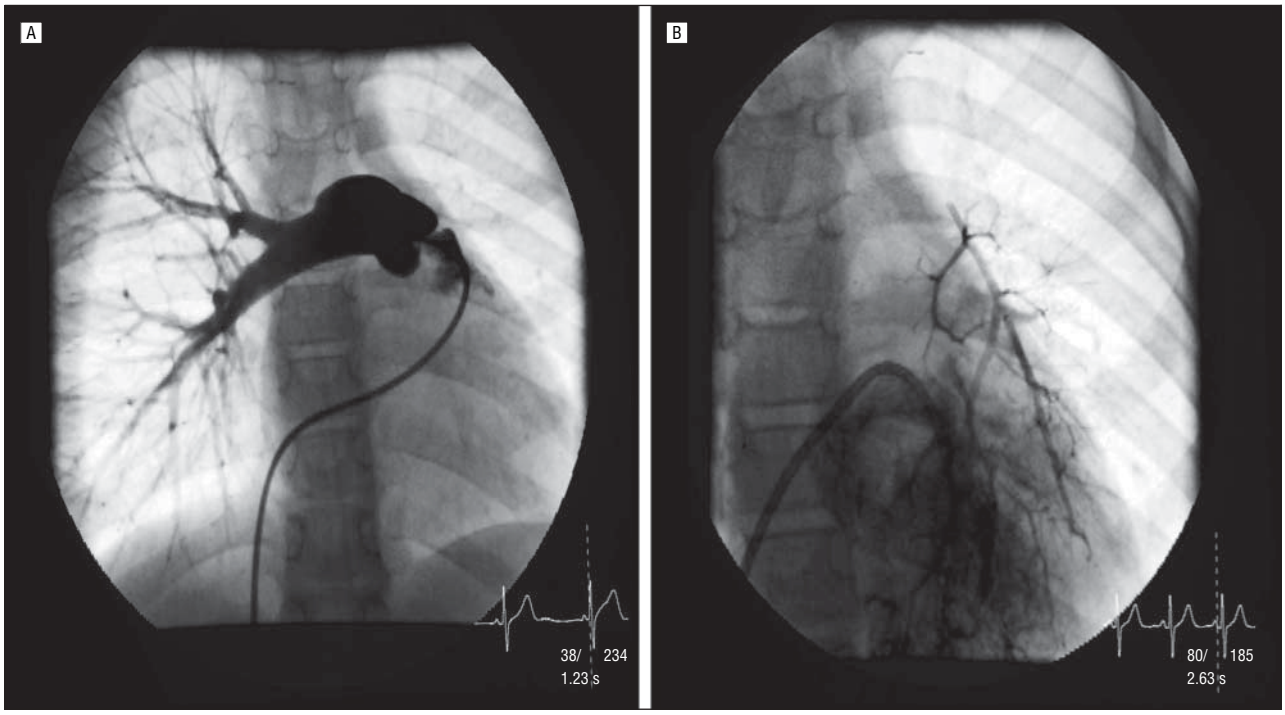

Figure 2. Pulmonary angiogram from patient 7, showing the right pulmonary artery arising normally from the main pulmonary artery (A) and the small "absent" left pulmonary artery filling from the pulmonary vein (B).

At cardiac catheterization, 6 months after HAPE, his PAP was 50/20 mm Hg during RA breathing. His pressure increased to 82/48 mm Hg during hypoxic challenge and fell to 30/12 mm Hg during administration of vasodilation. After administration of diltiazem, his PAP was 42/22 mm Hg. One year later, while receiving treatment with calcium channel blockers and nighttime oxygen, his echocardiogram showed a systolic PAP of 43 mm Hg.

PATIENT 6

A 9-year-old boy, who was healthy living at 1610 m, developed breathlessness and cough after 1 night at 3050 m. A chest radiograph was consistent with HAPE confined to the left lung. Three months later, he was referred to The Children's Hospital, where echocardiogram and angiography indicated an "absent" right pulmonary artery and a left aortic arch. His PAP was 44/18 mm Hg during RA breathing and increased to 61/27 mm Hg during hypoxic challenge. After intravenous diltiazem administration, his PAP during hypoxic challenge was 39/13 mm Hg. Eighteen months later, while being treated with an oral calcium channel blocker, his PAP was 35 mm Hg. He has visited altitude of 2500 m without recurrence of HAPE.

PATIENT 7

A 9-year-old boy, who was a competitive skier living at 2000 m, had 2 episodes of HAPE while training at 2750 m. One episode was preceded by an upper respiratory tract infection. The chest roentgenogram showed unilateral pulmonary edema confined to the right lung. The echocardiogram and a pulmonary angiogram (**Figure 2**) indicated "absent" left pulmonary artery and a right aortic arch. During RA breathing, his PAP was 65/25 mm Hg, and it decreased to 35/9 mm Hg during administration of vasodilation. With intravenous diltiazem administration, his PAP was 45/10 mm Hg. Despite treatment with an oral calcium channel blocker and a family move to 1050-m elevation for 2 years, echocardiography showed persistent PH (systolic PAP, 60 mm Hg). Oral bosentan (an endothelin receptor antagonist), and subsequently sildenafil (type-5 phosphodiesterase inhibitor), was added to the treatment regimen, and after 2 years, he reported improved exercise tolerance with an estimated systolic PAP of 50 mm Hg.

PATIENT 8

A 12-year-old boy, living at altitude of 1600 m, developed radiographically proven HAPE while collecting firewood at 3050-m elevation. He subsequently developed breathlessness and cough on each of 12 or more visits above altitude of 3000 m. At age 31 years, he moved to sea level but had breathlessness, cough, and malaise on visits to 1610 m. At age 36 years, an ECG showed evidence of RVH, not present at age 12 years. Cardiac catheterization showed an atrial septal defect, with a left-to-right shunt with pulmonary flow being 1.6 times systemic flow. During RA breathing, his PAP was 38/19 mm Hg. With hypoxic challenge, pressure increased to 63/35 mm Hg, and a right-to-left shunt through the defect developed. Following surgical closure of his atrial septal defect and treatment with an oral calcium channel blocker, his symptoms have disappeared. Furthermore, he has been symptom free on subsequent visits to ski at altitude higher than 3000 m.

©2004 American Medical Association. All rights reserved.
Downloaded From: http://archpedi.jamanetwork.com/ on 08/29/2014

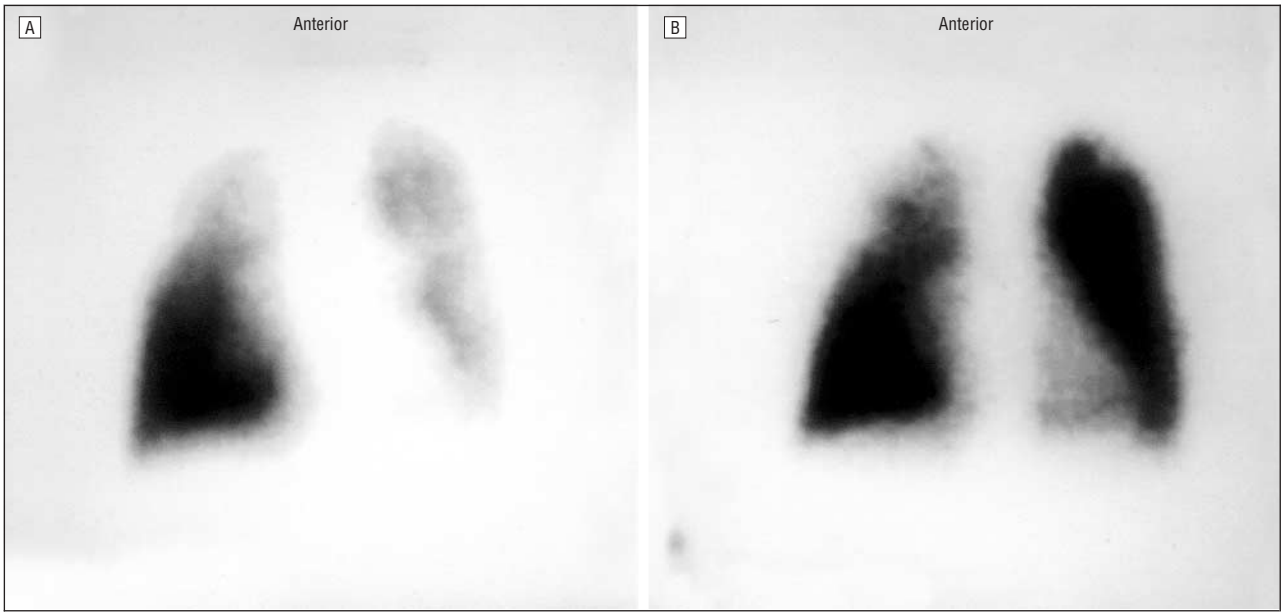

Figure 3. The perfusion scan from patient 10. A, The lung shows decreased blood flow to the left lung and right upper lobe prior to stenting of the obstructed pulmonary veins. B, Improvement in differential perfusion after stenting of the pulmonary veins.

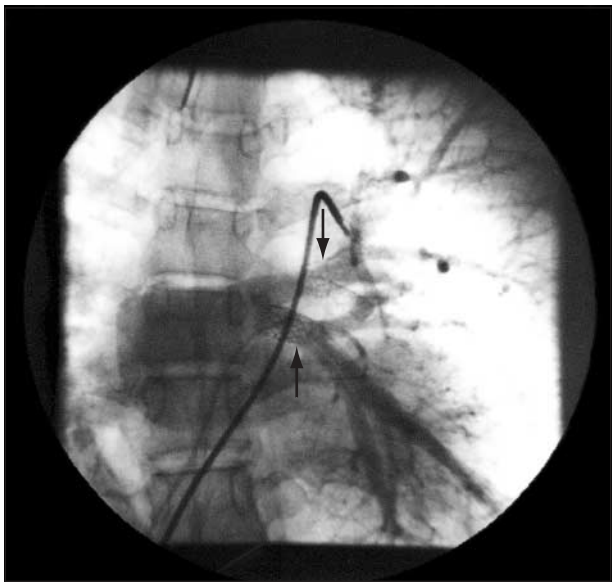

Figure 4. Pulmonary venogram from patient 10 after stenting of the left upper and lower pulmonary veins (arrows).

PATIENT 9

A 13-year-old boy, who lives at altitude of 2450 m, underwent surgical repair of a coarctation of the aorta at age 7 years. At age 8 years, he had heart catheterization with balloon dilatation of restenosis of the coarctation site and coil occlusion of the largest of several ventricular septal defects. At that time, his mean PAP was 42 mm Hg. At age 9 years, he developed HAPE 12 hours after going to altitude of 3050 m. He subsequently had 2 additional episodes of HAPE while visiting altitudes between 3000 and 3650 m. Cardiac catheterization 1 year after the last episode of HAPE showed a very small residual ventricular septal defect. During RA breathing, his PAP was 66/32 mm Hg. With hypoxic challenge, his PAP increased to 82/54 mm Hg, and with administration of vasodilation, PAP decreased to 52/22 mm Hg. Diltiazem administration changed neither the PAP nor the response to repeat hypoxic challenge. One year later, receiving treatment with oxygen and a calcium channel blocker, he has remained well, and his echocardiogram showed a systolic PAP of 50 mm Hg.

PATIENT 10

A 16-year-old boy was born at 29 weeks' gestation and received supplemental oxygen during infancy. He had a history of bronchopulmonary dysplasia and lived at altitude of 1610 m. He was apparently well until age 14 years when he noted the onset and progression of breathlessness at rest and during exercise. At ages 15 and 16 years, he developed pulmonary edema within 12 hours of going to altitude of 2130 m, and he improved promptly with oxygen treatment, consistent with clinical HAPE. Six months after the last episode, his echocardiogram indicated possible pulmonary vein stenosis. The perfusion scan showed decreased flow to the left lung and right upper lobes (**Figure 3**A). Pulmonary angiogram showed left lower, left upper, and right upper lobar pulmonary vein stenosis. He had stents implanted at catheterization to dilate the left upper and lower lobar veins, and balloon angioplasty was performed for the right upper pulmonary vein stenosis. Repeat perfusion scans showed improvement (Figure 3B). At repeat cardiac catheterization, the stents were redilated with no other pulmonary veins developing occlusion (**Figure 4**). He has been asymptomatic for 3 years after the stenting, and his breathlessness and exercise tolerance are markedly improved. Because pulmonary edema manifesting as clinical HAPE at altitude has not previously been described in pulmonary vein stenosis, we present patient 10 (**Table 3**) separately from the other patients.

©2004 American Medical Association. All rights reserved.
Downloaded From: http://archpedi.jamanetwork.com/ on 08/29/2014

Table 3. Hemodynamic and Blood Gas Data of Patient 10*

Hemodynamic and Blood Gas Data	6 mo After HAPE		14 mo After HAPE	19 mo After HAPE		42 mo After HAPE	
	Room Air	100% Oxygen and Nitric Oxide Administration	Room Air	Room Air	100% Oxygen and Nitric Oxide Administration	Room Air	100% Oxygen and Nitric Oxide Administration
PAP, S/D, mm Hg	55/25	52/28	51/29	36/16	36/12	36/11	32/11
PAP, mm Hg	40	39	40	25	26	23	20
AOP, mm Hg	87	71	72	60	70	69	67
PCWP, R, mm Hg	9	9	12	8	NA	9	10
PCWP, L, mm Hg	25	25	17	8	NA	9	9
RAP, mm Hg	8	9	12	8	10	8	7
CI, L/min per m^2	2.30	3.00	4.96	4.20	4.20	2.26	2.71
PVRI, U × m^2	17.30	13.00	8.66	5.90	6.10	6.20	3.70
SVRI, U × m^2	49.20	29.20	17.91	17.90	22.40	27.01	22.18
pH	7.41	7.38	7.39	7.39	7.38	7.39	7.38
Pa_{CO_2}, mm Hg	38	42	38	38	42	37	42
Pa_{O_2}, mm Hg	52	249	72	72	345	84	465

Abbreviations: AOP, aortic pressure; CI, cardiac index (cardiac output per body surface area in meters squared); L, left; NA, not applicable; PAP, pulmonary artery pressure; PCWP, pulmonary capillary wedge pressure; PVRI, pulmonary vascular resistance index; R, right; RAP, right atrial pressure; S/D, systolic/diastolic; SVRI, systemic vascular resistance index.

*Values are expressed as means.

RESULTS

SUMMARY OF CLINICAL FINDINGS

All 10 patients (4-18 years of age, 2 girls and 8 boys) lived between 1610- and 3050-m altitude (Table 1). The change in altitude for HAPE onset ranged from 520 to 2500 m. Four patients developed reentry HAPE within 12 to 24 hours of returning to their home altitude after a stay of only 1 to 2 days at lower altitude. One patient had an upper respiratory tract infection prior to HAPE. In the ascent group, there were 6 patients who, on ascending a mean of only 1065 m, developed HAPE within 12 hours. All 6 patients with ascent HAPE had cardiopulmonary diseases, which include 2 cases of "absent" unilateral pulmonary artery, 1 case of atrial septal defect, 1 case of coarctation of the aorta and ventricular septal defect, and 1 case of obstructive sleep apnea associated with obesity. In addition, patient 10 had pulmonary vein stenosis, recurrent pulmonary edema, and a clinical picture similar to recurrent HAPE, which responded to oxygen therapy. Except for patient 9, none of the cardiopulmonary diseases were diagnosed prior to HAPE episodes.

SUMMARY OF HEMODYNAMIC FINDINGS

At the time of catheterization at altitude of 1610 m, several months after the last HAPE episode, the mean PAP and pulmonary vascular resistance at rest were elevated, indicating presence of chronic PH. The administration of 16% oxygen increased the mean PAP and pulmonary vascular resistance significantly (Table 2). Vasodilators (100% oxygen and nitric oxide) dramatically decreased pressure and resistance. In 7 of 8 patients, diltiazem administration decreased the pressure and resistance to lower than the RA value. In the 5 who had repeat hypoxic challenge following diltiazem administration, 4 had blunting of the hypoxic pulmonary pressure response. None of these patients had hypoventilation-related hypercarbia during the study.

COMMENT

The most important finding of our study is the presence of underlying chronic PH in pediatric patients who had HAPE and were living at altitudes between 1610 and 3050 m. We allowed time (3-12 months) for resolution of pulmonary vasoconstriction secondary to HAPE. There was reasonable evidence that the PH was chronic and therefore preceded the HAPE. The clinical findings of loud second heart sound, exercise intolerance, and tiredness were suggestive of PH and supported by the presence of RVH on ECG and echocardiography.[8] Pulmonary hypertension was confirmed by cardiac catheterization. Furthermore, long-term treatment with oxygen, calcium channel blockers, sildenafil, or bosentan lowered PAP and brought improvement in exercise tolerance and prevented the recurrence of HAPE.[9,10] In addition, 6 patients (patients 5-10) had abnormal cardiopulmonary conditions (Table 1), which are known to be associated with PH.[3,4,11]

Review of published reports revealed that only 1 patient (a 56-year-old woman) had PH, documented 18 months after the HAPE episode.[12] In other published reports of patients suspected of having chronic PH, pressure was not measured, was only measured soon after the HAPE episode, or the interval was not stated.[13-16] Fasules et al[17] have shown normal PAP but with marked pulmonary vascular reactivity to hypoxia in 7 children living at altitude (3300 m) after several months of recovery from HAPE.

In our patients, HAPE occurred with a mean altitude change of only 1617 m in the reentry group and 1065 m in the ascent group (Table 1). The interval from time of arrival at an increased altitude to onset of HAPE was also unusually short, within 12 to 24 hours (mean, 14.5 hours)

©2004 American Medical Association. All rights reserved.
Downloaded From: http://archpedi.jamanetwork.com/ on 08/29/2014

What This Study Adds

Children living at altitude with PH are susceptible to recurrent HAPE, which can be life threatening. High-altitude pulmonary edema can be prevented by identifying the underlying cardiopulmonary disorders, appropriate counseling, and treatment with calcium channel blockers. Children and young adults living at altitude with a history of recurrent HAPE should be screened for underlying PH.

compared with the mean interval of 1.7±1.5 days reported in adults.[5] The relatively small altitude change, the rapid onset of HAPE, and the brief stay at low altitude in the reentry group suggested the increased susceptibility of our patients to HAPE. Both of our patients with unilateral pulmonary artery (patients 6 and 7) had chronic PH, possibly exacerbated by residence at high altitude. Multiple episodes of HAPE in patients 5, 8, and 9, who had atrial septal defect, ventricular septal defect, and obstructive sleep apnea, respectively, suggested an increased susceptibility.

The physiologic dilemma is why the pulmonary vascular remodeling associated with chronic PH[18] failed to protect these children from HAPE and may even have promoted the disorder. One possible explanation, namely, that high PAP promoted fluid leak through the vascular walls,[19] seems unlikely in these patients with thickened arteriolar walls. The possibility cannot be excluded that arteriolar obstructions were nonuniform, causing hyperperfusion edema in the less obstructed segments.[1,20-22] However, the occurrence of HAPE with pulmonary vein stenosis in patient 10 suggests that if the vasoreactivity involves not only the arterioles but also the venules, then hypoxic venoconstriction could contribute to HAPE.[23] Maggiorini et al[24] have provided evidence in susceptible humans going to altitude that hypoxic venoconstriction, by increasing pressure in the lung capillaries, may play an important role in HAPE.

Our data suggest that HAPE can be prevented with calcium channel blockade in children with demonstrable PH and pulmonary vasoreactivity. Despite our recommendation, not all families moved to lower altitude and did not refrain from returning to higher altitude. Whether PH will permanently resolve in these children is not known. The association of HAPE with complicating disorders in children at high altitude suggests that susceptible children should be screened for underlying cardiopulmonary diseases including pulmonary hypertension.

Accepted for Publication: July 8, 2004.
Correspondence: Dunbar Ivy, MD, Department of Pediatric Cardiology, The Children's Hospital, 1056 E 19th Ave, Denver, CO 80218 (ivy.dunbar@tchden.org).
Funding/Support: This study was supported by grant M01 RR00069 from the General Clinical Research Centers Program, National Center for Research, National Institutes of Health, Bethesda, Md, and by the Colorado Center for Altitude Medicine and Physiology, Denver.
Additional Information: This article is dedicated to the memory of Dr Reeves.
Acknowledgment: We thank Peter H. Hackett, MD, Department of Emergency Medicine, University of Colorado Health Science Center, Denver, for critical review of the manuscript.

REFERENCES

1. Hultgren HN. High-altitude pulmonary edema: current concepts. *Annu Rev Med*. 1996;47:267-284.
2. Sophocles AM, Bachman J. High-altitude pulmonary edema among visitors to Summit county, Colorado. *J Fam Pract*. 1983;17:1015-1017.
3. Pollard AJ, Niermeyer S, Barry P, et al. Children at high altitude: an international consensus statement by an ad hoc committee of the international society for mountain medicine, March 12, 2001. *High Alt Med Biol*. 2001;2:389-403.
4. Durmowicz AG. Pulmonary edema in 6 children with Down syndrome during travel to moderate altitudes. *Pediatrics*. 2001;108:443-447.
5. Gabry ALG, Ledoux X, Mozziconacci M, Martin C. High-altitude pulmonary edema at moderate altitude (<2,400 m; 7,870 feet): a series of 52 patients. *Chest*. 2003; 23:49-53.
6. Ivy DD. Echocardiographic evaluation of pulmonary hypertension. In: Valdes-Cruz LM, Cayre RO, eds. *Echocardiographic Diagnosis of Congenital Heart Disease: An Embryologic and Anatomic Approach*. Philadelphia, Pa: Lippincott Williams & Wilkins; 1999:537-547.
7. Atz AM, Adatia I, Lock JE, et al. Combined effects of nitric oxide and oxygen during acute pulmonary vasodilator testing. *J Am Coll Cardiol*. 1999;33:813-819.
8. Ivy D. Diagnosis and treatment of severe pediatric pulmonary hypertension. *Cardiol Rev*. 2001;9:227-237.
9. Barst RJ, Maislin G, Fishman AP. Vasodilator therapy for primary pulmonary hypertension in children. *Circulation*. 1999;99:1197-1208.
10. Barst RJ, Ivy D, Dingemanse J, et al. Pharmacokinetics, safety, and efficacy of bosentan in pediatric patients with pulmonary hypertension. *Clin Pharmacol Ther*. 2003;73:372-382.
11. Ten Harkel AD, Blom NA, Ottenkamp J. Isolated unilateral absence of a pulmonary artery: a case report and review of the literature. *Chest*. 2002;122:1471-1477.
12. Hultgren HN, Grover RF, Hartley LH. Abnormal circulatory responses to high altitude in subjects with a previous history of high-altitude pulmonary edema. *Circulation*. 1971;44:759-770.
13. Penaloza D, Sime F. Circulatory dynamics during high altitude pulmonary edema. *Am J Cardiol*. 1969;23:369-378.
14. Hackett PH, Creagh CE, Grover RF, et al. High-altitude pulmonary edema in persons without the right pulmonary artery. *N Engl J Med*. 1980;302:1070-1073.
15. Hultgren HN, Lopez CE, Einar L, Miller H. Physiologic studies of pulmonary edema at high altitude. *Circulation*. 1964;29:393-408.
16. Rios B, Driscoll DJ, McNamara DG. High-altitude pulmonary edema with "absent" right pulmonary artery. *Pediatrics*. 1985;75:314-317.
17. Fasules JW, Wiggins JW, Wolfe RR. Increased lung vasoreactivity in children from Leadville, Colorado, after recovery from high-altitude pulmonary edema. *Circulation*. 1985;72:957-962.
18. Gibbons GH, Dzau VJ. The emerging concept of vascular remodeling. *N Engl J Med*. 1994;330:1431-1438.
19. Whayne TF Jr, Severinghaus JW. Experimental hypoxic pulmonary edema with primary pulmonary hypertension. *Chest*. 1996;110:2078-2088.
20. West JB, Colice GL, Lee YJ, et al. Pathogenesis of high-altitude pulmonary edema: direct evidences of stress failure of pulmonary capillary. *Eur Respir J*. 1995; 8:523-529.
21. Staub NC. Pulmonary edema-hypoxia and overperfusion [editorial]. *N Engl J Med*. 1980;302:1085-1086.
22. Reeves JT, Tweeddale D, Noonan J, Leathers JE, Quigley MB. Correlations of microangiographic and histological findings in the pulmonary vascular bed: technique and application to pulmonary hypertension. *Circulation*. 1996;34:971-983.
23. Fred HL, Scmidt AM, Bates T, Hecht HH. Acute pulmonary edema of altitude: clinical and physiologic observation. *Circulation*. 1962;25:929-937.
24. Maggiorini M, Melot C, Pierre S, et al. High-altitude pulmonary edema is initially caused by an increase in capillary pressure. *Circulation*. 2001;103:2078-2083.

©2004 American Medical Association. All rights reserved.
Downloaded From: http://archpedi.jamanetwork.com/ on 08/29/2014