SECTION EDITOR: ENID GILBERT-BARNESS, MD

Pathological Case of the Month

R. Hubert Laeng, MD; Jody Stähelin, MD; Patrick Schaller, MD; André Arnoux, MD

A 15-MONTH-OLD girl developed a right facial nerve palsy (**Figure 1**) while receiving oral treatment with amoxicillin for a sore throat and bilateral otitis media of one week's duration. On physical examination, bilateral otomastoiditis, perforation of the left tympanic membrane, and right-sided cervical lymphadenopathy were found. Bilateral mastoidectomy/antrotomy was performed: on gross inspection, the mucosa appeared dark red, swollen, and polypoid. The diagnostic histological findings of the biopsy specimens are shown in **Figure 2** and **Figure 3**. Oral steroids were given for 5 days, and amoxicillin–clavulanic acid was administered intravenously for 14 days. At follow-up 4 months later there was complete recovery including resolution of the nerve deficit.

From the Departments of Pathology (Dr Laeng), Pediatrics (Dr Stähelin), and Otorhinolaryngology (Drs Schaller and Arnoux), Kantonsspital, Aarau, Switzerland.

Figure 1.

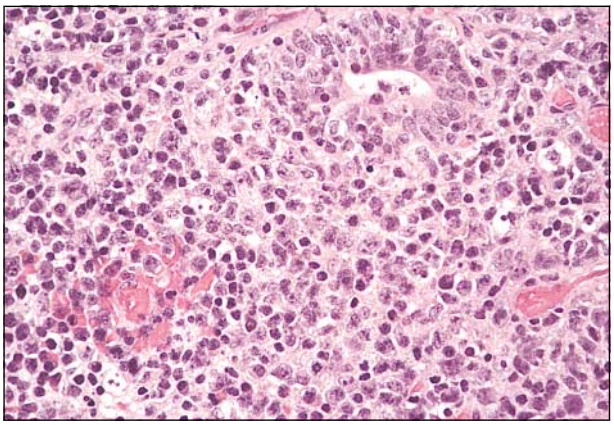

Figure 2.

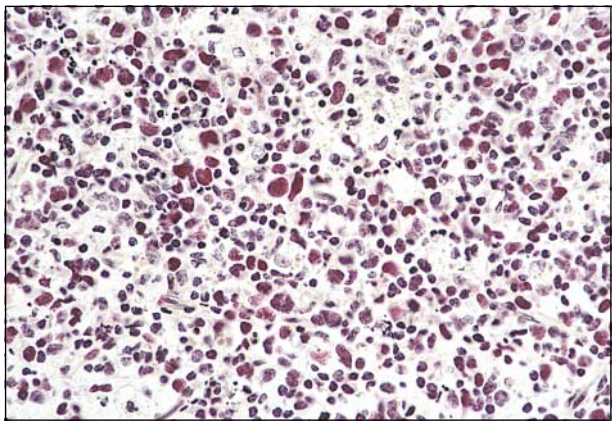

Figure 3.

©2002 American Medical Association. All rights reserved.
Downloaded From: http://archpedi.jamanetwork.com/ on 02/14/2016

Diagnosis and Discussion

Epstein-Barr Virus Otomastoiditis Associated With Peripheral Facial Nerve Palsy

Figure 1. Peripheral facial nerve palsy photographed the first postoperative day. Peripheral blood leukocyte count was 17 200 × 10^3/μL with 10 100 lymphocytes/μL, of which 17.5% were atypical. The IgG and IgM antibodies directed against the Epstein-Barr virus (EBV) capsid antigen were found to be positive, while EBV-associated nuclear antigen was not detected, indicative of recent EBV infection.

Figure 2. Dense lymphoplasmacytic infiltrate with some blastic transformed cells in a biopsy specimen from the right mastoid mucosa (hematoxylin-eosin, original magnification ×100).

Figure 3. In situ hybridization for Epstein-Barr virus–encoded RNA: the red chromogen new fuchsin stain highlights nuclear reaction products in a majority of lymphocytes in the same biopsy specimen as shown in Figure 2 (counterstain with hematoxylin, original magnification ×100).

UPPER RESPIRATORY tract viral infection is one of the most common illnesses in both children and adults. The upper respiratory tract epithelium is also the portal of entry for Epstein-Barr virus (EBV), where it is replicated. The clinical correlate of systemic EBV infection, infectious mononucleosis, is a common disorder in both children and adolescents.[1,2] Although the middle ear communicates with the oropharyngeal cavity, there is only one report presenting morphological findings suggestive of EBV-associated otitis media with facial nerve palsy.[3] Central nervous system complications in EBV infection, on the other hand, are well known but relatively uncommon, and include meningitis, encephalitis, Guillain-Barré syndrome, transverse myelitis, and cranial nerve palsy.[3-5] The pathogenesis of EBV-associated neurological complications is unknown, and their morphological correlates are ill defined.[3,4]

Unlike the neurotropic human herpesviruses (HHV) types 1, 2 and 3, EBV (HHV-4) is lymphotropic, resulting in a self-limiting lymphoproliferative reaction in the immunocompetent host.[1-6] The specific binding site of the virion envelope glycoprotein is found on the C3d component of the complement system, and displayed on nearly all B cells.[1] Since the diagnosis of acute EBV infection mainly relies on clinical and serological findings, biopsy is not commonly peformed unless the presentation is atypical.[6] Histologically, the immune response in tonsils and lymph nodes is characterized by proliferation and blastic transformation of lymphocytes in the paracortex, which may result in partial effacement of the normal nodal histoarchitecture, thus simulating malignant lymphoma.[6] In EBV-associated lymphadenopathy, however, atypical lymphoid cells are found in clusters: they lack the cytological uniformity usually found in high-grade malignant lymphomas, and there are other cells interspersed including Marschalko-type plasma cells.[6] In the present case, a similar infiltrate outside the lymphoreticular organs is seen in the biopsy specimen taken from the mastoid mucosa (Figure 2). Immunohistochemistry for light chain immunoglobulins confirmed a polyclonal B cell population.

In the present biopsy specimen, amplification by polymerase chain reaction for bacterial genomic DNA was negative. However, the majority of blastic-transformed lymphocytes and a minor fraction of small lymphocytes were reactive for the latent membrane protein of EBV (EBV-LMP), and in situ hybridization reflected the presence of EBV-mRNA in the majority of lymphocytes (Figure 3). To our knowledge, this is the first case to disclose the intralesional presence of the putative pathogenic infectious agent by in situ hybridization for EBV-encoded RNA in lymphoplasmacytic otomastoiditis.

Accepted for publication August 26, 1999.

Corresponding author: R. Hubert Laeng, MD, Department of Pathology, Kantonsspital, CH-5001 Aarau, Switzerland (e-mail: laeng@ksa.ch).

REFERENCES

1. Unger ER, Purtilo DT. Epstein-Barr virus and human diseases. In: Connor DH, Chandler FW, Schwartz DA, Manz HJ, Lack EE, eds. *Pathology of Infectious Diseases.* Stamford, Conn: Appleton & Lange; 1997:113-123.
2. Sumaya CV, Ench Y. Epstein-Barr virus infectious mononucleosis in children, I: clinical and general laboratory findings. *Pediatrics.* 1985;75:1003-1010.
3. Michel RG. Pope TH, Patterson CN. Infectious mononucleosis, mastoiditis and facial paralysis. *Arch Otolaryngol Head Neck Surg.* 1975;101:486-489.
4. Esiri MM, Kennedy PG. Viral diseases. In: Graham DI, Lantos PL, eds. *Greenfield's Neuropathology.* London, England: Arnold; 1997:35.
5. Grose C, Henle W, Henle G, Feorino PM. Primary Epstein-Barr virus infections in acute neurologic diseases. *N Engl J Med.* 1975;292:392-395.
6. Stansfeld AG. Inflammatory and reactive disorders. In: Stansfeld AG, D'Ardenne AJ, eds. *Lymph Node Biopsy Interpretation.* Edinburgh, Scotland: Churchill Livingstone; 1992:102-105.

Submissions

The Editor is seeking submissions for a new feature, *Clinical Problem Solving*, which will combine *Picture of the Month*, *Radiological Case of the Month*, and *Pathological Case of the Month*. Our aim is to demonstrate the thinking process of a master clinician involved in approaching a patient with an unknown disease. The discussion of such cases should place the clinician's expertise into the context of the prevailing medical literature on the topic. Manuscripts should be between 3000 and 4000 words and may include photographs and radiographs.

©2002 American Medical Association. All rights reserved.
Downloaded From: http://archpedi.jamanetwork.com/ on 02/14/2016