SPECIAL FEATURE

SECTION EDITOR: BEVERLY P. WOOD, MD

Radiological Case of the Month

Rivital Sela, MD; Moshe Nussinovitch, MD; Nitsa Ziv, MD; Benjamin Volovitz, MD; Jacob Amir, MD; Beverly P. Wood, MD

A 3-YEAR-OLD BOY was referred for evaluation of unilateral testicular swelling and abdominal and lower limb edema. His mother reported that he had been coughing and vomiting for 3 weeks prior to admission. Swelling began 4 weeks before admission. Physical examination showed extensive peripheral edema and ascites. There was no fever and his blood pressure was 106/56 mm Hg.

Laboratory findings were as follows: white blood cell count, 26.3×10^9 (62.7% lymphocytes); hemoglobin, 14.4 g/dL; albumin, 1.7 g/dL; potassium, 4.7 mmol/L; sodium, 132 mmol/L; glucose, 107 mg/dL (5.94 mmol/L); normal urine protein and amylase content; positive urine cytomegalovirus antigen; positive cytomegalovirus antibody, IgM and IgG; and stool α_1-antitrypsin level was 15.2 mg per gram of dry weight stool.

Abdominal ultrasound showed bilateral pleural effusions and a large quantity of intraperitoneal fluid, an enlarged liver, and markedly thickened gastric rugae (**Figure**).

The boy was treated with antibiotics for his cough, intravenous albumin and furosemide for edema, and a diet of protein-enriched food. The swelling subsided and the abdominal diameter decreased during the next several weeks.

From the Department of Paediatrics C and the Institute of Radiology, Schneider Children's Medical Centre of Israel, Sackler School of Medicine, Tel Aviv University, Petach Tikvah, Israel (Drs Sela, Nussinovitch, Ziv, Volovitz, and Amir); and the University of Southern California, Keck School of Medicine, Los Angeles (Dr Wood).

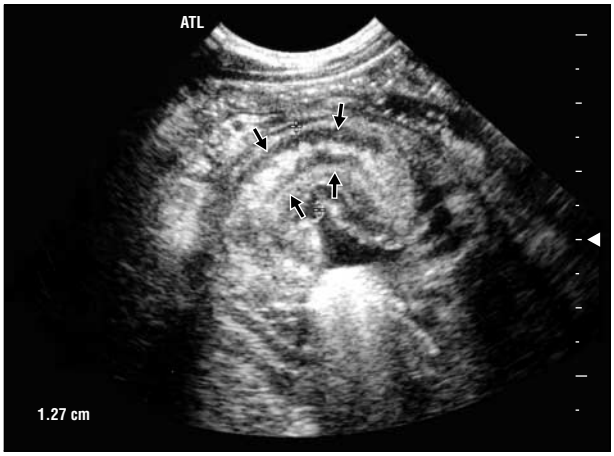

©2001 American Medical Association. All rights reserved.
Downloaded From: http://archpedi.jamanetwork.com/ on 04/25/2015

Denouement and Discussion

Hypertrophic Gastropathy With Edema

Figure. Abdominal ultasound shows marked thickening of gastric rugae.

A diagnosis of hypertrophic gastropathy with cytomegalovirus infection was made. Hypertrophic gastropathy of childhood has been reported in children with a mean age of 5 years. The initial symptoms include vomiting, diarrhea, abdominal pain, and anorexia. On physical examination, peripheral edema is usually present. Laboratory results show low serum albumin and protein-losing enteropathy proven by analysis of chromium-labeled albumin or stool α1-antitrypsin.

There are 2 diagnostic criteria for hypertrophic gastropathy: (1) giant gastric rugae by imaging, endoscopy, or laparotomy; and (2) characteristic histologic findings of foveolar hyperplasia and cystic dilation of submucosal glands.

The appearance of hypertrophic gastropathy has been analyzed by endoscopic ultrasound and endoscopy in previous studies. In the study by Hizawa et al,[1] every patient had giant gastric folds 13 to 20 mm in diameter resulting from thickening of the mucosal layer with or without cystic components. By ultrasound study, the thickened mucosa was echogenic and *Helicobacter pylori* was the causative agent in most adult patients. Approximately 55 cases of hypertropic gastropathy in children have been published. In contrast to the chronic course of Ménétrier disease in adults, the pediatric cases are generally benign, self-limited, and show complete resolution within a few weeks.[2] The benign pediatric hypertrophic gastropathies have been associated with infections, primarily cytomegalovirus[3] and occasionally *H pylori*, herpes simplex, and mycoplasma.[2,4]

Abdominal scintigraphy using technetium Tc 99m-labeled human serum albumin delivered intravenously and direct measurement of protein in gastric juice has proven that serum proteins are massively secreted in the stomach.[5] Supportive treatment with a high-protein diet and intravenous albumin transfusions is recommended. H2-receptor antagonist use may improve symptoms.[2,6]

Reprints: Moshe Nussinovitch, MD, Department of Paediatrics C, Schneider Children's Medical Centre of Israel, Petach Tikvah, Israel.

REFERENCES

1. Hizawa K, Kawasaki M, Yao T, et al. Endoscopic ultrasound features of protein-losing gastropathy with hypertrophic gastric folds. *Endoscopy*. 2000;32:394-397.
2. Kindermann A, Koletzko S. Protein-losing giant fold gastritis in childhood—a case report and differentiation from Menetrier disease of adulthood. *Z Gastroenterol*. 1998;36:165-171.
3. Eisenstat DD, Griffiths AM, Cutz E, Petric M, Drumm B. Acute cytomegalovirus infection in a child with Menetrier's disease. *Gastroenterology*. 1995;109:592-595.
4. Ben Amitai D, Zahavi I, Dinari G, Garty BZ. Transient protein-losing hypertrophic gastropathy associated with *Mycoplasma pneumoniae* infection in childhood. *J Pediatr Gastroenterol Nutr*. 1992;14:237-239.
5. Yamada M, Sumazaki R, Adachi H, et al. Resolution of protein-losing hypertrophic gastropathy by eradication of *Helicobacter pylori*. *Eur J Pediatr*. 1997;156:182-185.
6. Kaneko T, Akamatsu T, Gotoh A, et el. Remission of Ménétriér's disease after a prolonged period with therapeutic eradication of *Helicobacter pylori*. *Am J Gastroenterol*. 1999;94:272-273.

©2001 American Medical Association. All rights reserved.
Downloaded From: http://archpedi.jamanetwork.com/ on 04/25/2015