

SECTION EDITOR: ENID GILBERT-BARNES, MD

## Pathological Case of the Month

Shishir N. Sheth, MD; Carmen Gomez, MD; Gary D. Josephson, MD

**A** 6-WEEK-OLD girl with no other medical problems was brought to the otolaryngology clinic for a mass on her tongue causing mild difficulty in feeding. A history of neonatal meconium delivery was reported for which the child was hospitalized for a week.

*From the Departments of Otolaryngology–Head and Neck Surgery (Dr Sheth) and Pathology (Dr Gomez), Division of Pediatric Otolaryngology–Head and Neck Surgery (Dr Josephson), University of Miami School of Medicine, Miami, Fla. Dr Sheth is now with the Department of Otolaryngology–Head and Neck Surgery, Cleveland Clinic Florida, Ft Lauderdale. Dr Josephson is now with the Nemours Children’s Clinic, Jacksonville, Fla.*

During the hospitalization, she was noted to have a whitish, scooped-out lesion on the dorsum of the tongue in the same area as her current lesion; this was felt to be a fungal infection and was treated with antifungals. The tumor had grown in the area from the time of birth to the time of presentation. There were no associated respiratory problems.

Examination revealed a bilobed, pale, 2 × 1-cm mass on the midline dorsum of the tongue, centrally located (**Figure 1**). This was firm and rubbery in texture and had no obvious tenderness. Findings from the remainder of the head and neck examination were normal. Intraoperative biopsy findings are shown in **Figure 2**.

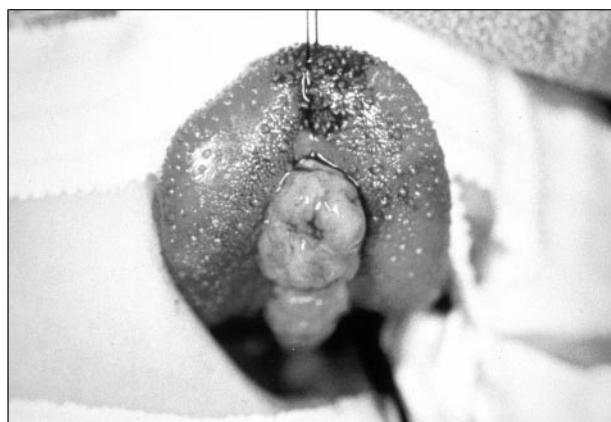


Figure 1.

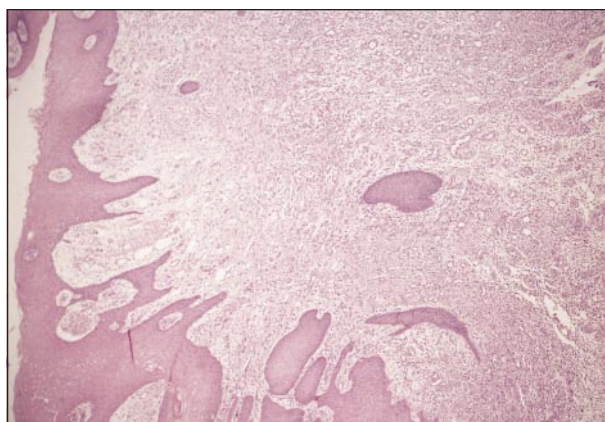


Figure 2.

# Diagnosis and Discussion

## Pyogenic Granuloma of the Tongue

**Figure 1.** A 2 × 1-cm mass on the midline of the tongue.

**Figure 2.** Endothelial proliferation with formation of vascular spaces. Note the lymphocytic infiltration of the lesion (hematoxylin-eosin, original magnification ×40).

First described in humans by Poncet and Dor,<sup>1</sup> pyogenic granuloma is relatively common and accounts for 1.85% to 7% of all biopsy findings from oral cavity lesions.<sup>2,3</sup> Females are slightly more affected than males,<sup>2-6</sup> and the age at presentation ranges from 18 months to 93 years. Our patient, at age 6 weeks, is the youngest reported case to our knowledge.

The pathogenesis of this benign lesion is not well understood. Trauma is felt to be the most common initiating event but is not always present in the history.<sup>4</sup> The occasional presence of microorganisms has led to speculation of an infectious cause. This has not been proven. There is a higher incidence of pyogenic granuloma in women during pregnancy, and this is felt to be caused by the raised levels of progesterone and estrogen; the tumor usually regresses postparturition.<sup>7,8</sup> The underlying problem seems to be an exaggerated tissue response and vascular proliferation secondary to local irritation.

The most common symptom of oral cavity pyogenic granuloma is the presence of a mass. The tumor may grow rapidly in size and then remain stable for indefinite periods of time.<sup>4,6</sup> The most common sites within the oral cavity according to several large series<sup>2,4,6</sup> are gingiva (61%), lip (14%), tongue (9%), and buccal mucosa (7%). Pain, aside from the local mass effect, may or may not be present. The tumors are often vascular and can bleed either spontaneously or in response to trauma. Adjacent bone resorption may occur.<sup>6-9</sup>

On gross examination, the tumor appears as an elevated, often lobulated and ulcerated mass that could be either sessile (as in our case; Figure 1) or pedunculated.<sup>4</sup> Some<sup>4,6</sup> feel that younger tumors are soft in consistency, progressing to a rubbery texture on maturation. The color may range from pink to bright red to purple or brown.

An extreme endothelial proliferation with formation of vascular spaces is histopathologically visible (Figure 2); renaming this lesion to *lobular capillary hemangioma* has been proposed.<sup>10</sup> The tumor is covered by a thin epithelium that is usually ulcerated.<sup>2,4</sup> There is often a lymphocytic infiltration; bacteria may be present, especially if ulcerated.

The only curative treatment is conservative local excision. Recurrence rates after excision range from 0% to 16%.<sup>2,3,5</sup> Because the pyogenic granuloma of pregnancy often regresses postparturition, they need not be excised unless symptomatic.<sup>7,8,11</sup> After complete excision, our patient has been symptom- and disease-free for a follow-up period of 1 year.

Accepted for publication August 15, 2000.

Reprints: Gary D. Josephson, MD, Division of Pediatric Otolaryngology–Head and Neck Surgery, Nemours Children’s Clinic, 807 Nira St, Jacksonville, FL 32225 (e-mail: gjoephos@nemours.org).

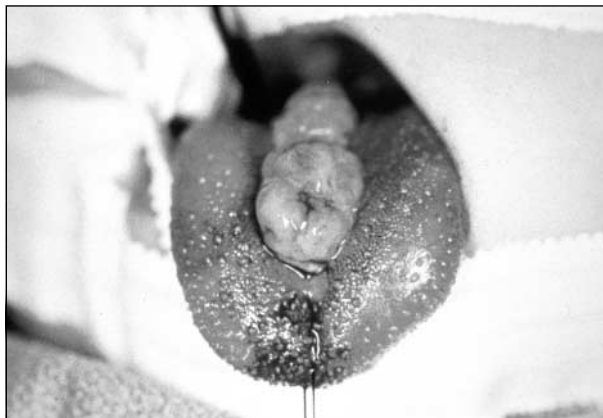### REFERENCES

1. Poncet A, Dor L. Botryomycose humaine. *Rev Chir Orthop.* 1897;18:996.
2. Bhaskar SN, Jacoway JR. Pyogenic granuloma-clinical features, incidence, histology and result of treatment: report of 242 cases. *J Oral Surg.* 1966;24:391-398.
3. Lawoyin JO, Arotiba JT, Dosumu OO. Oral pyogenic granuloma: a review of 38 cases from Ibadan, Nigeria. *Br J Oral Maxillofac Surg.* 1997;35:185-189.
4. Kerr DA. Granuloma pyogenicum. *Oral Surg.* 1951;4:158-176.
5. Leyden JJ, Master GH. Oral cavity pyogenic granuloma. *Arch Dermatol.* 1973;108:226-228.
6. Angelopoulos AP. Pyogenic granuloma of the oral cavity: statistical analysis of its clinical features. *J Oral Surg.* 1971;29:840-847.
7. Sills ES, Zegarelli DJ, Hoschander MM, Strider WE. Clinical diagnosis and management of hormonally responsive oral pregnancy tumor (pyogenic granuloma). *J Reprod Med.* 1996;41:467-470.
8. Manus DA, Sherbert D, Jackson IT. Management considerations for the granuloma of pregnancy. *Plast Reconstr Surg.* 1995;95:1045-1050.
9. Goodman-Topper ED, Bimstein E. Pyogenic granuloma as a cause of bone loss in a twelve-year-old child: report of case. *J Dent Child.* 1994;61:65-67.
10. Mills SE, Cooper PH, Fechner RE. Lobular capillary hemangioma: the underlying lesion of pyogenic granuloma. *Am J Surg Pathol.* 1980;4:471-479.
11. Goette DK, Carpenter WM. Pyogenic granuloma of the oral cavity. *South Med J.* 1977;70:1358-1360.

- genital abnormalities: recommendations for the appropriate use of folic acid during pregnancy [review]. *Paediatr Drugs*. 2000;2:437-449.
17. Ethan M, Case A. *Texas Birth Defects Registry Report of Birth Defects Among 1996 and 1997 Deliveries*. Texas Department of Health Publication, September 2000. Also available at: [http://www.tdh.state.tx.us/tbdmd/96-97texas\\_birth\\_defects\\_registry.htm](http://www.tdh.state.tx.us/tbdmd/96-97texas_birth_defects_registry.htm). Accessed April 2001.
  18. Rosenblatt DS, Fenton WA. Inherited disorder of folate and cobalamin transport an metabolism. In: Scriver CR, Beaudet AL, Sly WS, Valle D, eds. *The Metabolic and Molecular Basis of Inherited Disease*. 8th ed. New York, NY: McGraw-Hill Co; 2000:3897-3933.
  19. Rozen R. Genetic modulation of homocysteinemia [review]. *Semin Thromb Hemost*. 2000;26:255-261.
  20. Guttormsen AB, Ueland PM, Nesthus I, et al, for the Hordaland Homocysteine Study. Determinants and vitamin responsiveness of intermediate hyperhomocysteinemia ( $\geq 40$  micromol/liter). *J Clin Invest*. 1996;98:2174-2183.
  21. Centers for Disease Control and Prevention. Folate status in women of childbearing age—United States, 1999. *MMWR Morb Mortal Wkly Rep*. 2000;49:962-965.
  22. American Academy of Pediatrics Committee on Genetics. Folic acid for the prevention of neural tube defects. *Pediatrics*. 1999;104:325-327.
  23. Boushey CJ, Beresford SA, Omenn GS, Motulsky AG. A quantitative assessment of plasma homocysteine as a risk factor for vascular disease: probable benefits of increasing folic acid intakes. *JAMA*. 1995;274:1049-1057.
  24. Diaz-Arrastia R. Homocysteine and neurologic disease [review]. *Arch Neurol*. 2000; 57:1422-1427.
  25. ACOG Committee Opinion: Committee on Obstetrics: Maternal and Fetal Medicine Number 120—March 1993. Folic acid for the prevention of recurrent neural tube defects. *Int J Gynaecol Obstet*. 1993;42:75-77.
  26. Standing Committee on the Scientific Evaluation of Dietary Reference Intakes, Institute of Medicine. Dietary reference intakes for thiamin, riboflavin, niacin, vitamin B<sub>6</sub>, folate, vitamin B<sub>12</sub>, pantothenic acid, biotin, and choline. Available at: [http://books.nap.edu/html/dri\\_thiamin/index.html#Summary](http://books.nap.edu/html/dri_thiamin/index.html#Summary). Accessed April 2001.
  27. Food and Drug Administration. Frequently asked questions, Food Stamp Program. Available at: <http://www.fns.usda.gov/fsp/MENU/faqs/faqs.htm>. Accessed April 2001.
  28. Centers for Disease Control and Prevention. Knowledge and use of folic acid by women of childbearing age—United States, 1995 and 1998. *MMWR Morb Mortal Wkly Rep*. 1999;48:325-327.
  29. McDonnell R, Johnson Z, Doyle A, Sayers G. Determinants of folic acid knowledge and use among antenatal women. *J Public Health Med*. 1999;21:145-149.
  30. Morin V, Mondor M, Wilson RD. Knowledge on periconceptional use of folic acid in women of British Columbia. *Fetal Diagn Ther*. 2001;16:111-115.
  31. Canfield M, Condon K, Case A, Sever L, Tinkle M. Lower folic acid rates in Texas related to socio-economic status, but not cost. Presented as a poster at: The Fourth Annual Meeting of the National Birth Defects Prevention Network, January 29-31, 2001; San Antonio, Tex. Also available at: [http://www.tdh.state.tx.us/tbdmd/brfss\\_Folacid.html](http://www.tdh.state.tx.us/tbdmd/brfss_Folacid.html). Accessed April 2001.
  32. Pagnini DL, Reichman NE. Psychosocial factors and the timing of prenatal care among women in New Jersey's HealthStart Program. *Fam Plann Perspect*. 2000; 32:56-64.

### Correction

**Error in Figure Orientation.** In the Pathological Case of the Month published in the September issue of the ARCHIVES (2001;155:1065-1066), **Figure 1** was mistakenly presented upside down. Figure 1 is reprinted correctly here. The ARCHIVES regrets the error.



**Figure 1.** A 2 × 1-cm mass on the midline of the tongue.