SECTION EDITOR: BEVERLY P. WOOD, MD

Radiological Case of the Month

Timothy J. Porea, MD, MPH; Judith F. Margolin, MD; Murali M. Chintagumpala, MD

A 2-YEAR-OLD girl undergoing therapy for acute lymphoblastic leukemia was also receiving home treatment with intravenous (IV) antibiotics for a central line infection. A subcutaneous device (Port-A-Cath; Horizon Medical Products Inc, Manchester, Ga) was in place to facilitate chemotherapy. The acute lymphoblastic leukemia was in remission 6 months after the initial diagnosis. One week prior to this illness, the patient was hospitalized for *Escherichia coli* bacteremia and, once blood cultures were sterile, was discharged to complete a course of IV antibiotics at home. The patient's mother had received instructions on how to administer the medications through the central venous catheter (CVC) previously and again during the recent hospitalization. She had received IV treatment at home for 5 days, when, during one treatment, her mother rapidly pushed the last few milliliters of the antibiotic dose through the CVC, withdrew the plunger of the syringe, and replaced it, allowing air to enter the catheter. The child immediately complained of chest pain, lost consciousness for 2 minutes, and developed perioral cyanosis. Emergency medical services were called, and the child, appearing well, was transported to the hospital without incident.

In the emergency department she was afebrile. Findings from physical examination, including the respiratory system, were normal. Breathing room air, her oxygen saturation was 89% to 90%. Electrocardiogram findings were unremarkable, and an echocardiogram demonstrated no cardiac structural abnormalities. A chest radiograph showed intense pulmonary venous congestion with Kerley-B lines and septal thickening (**Figure 1**). The heart appeared normal. The patient was admitted for observation and oxygen therapy, and she rapidly showed oxygen saturations of 98% to 100% breathing room air. A chest radiograph repeated 16 hours after presentation showed normal pulmonary vascularity (**Figure 2**).

From the Division of Pediatric Hematology-Oncology, Texas Children's Hospital, Houston. Dr Porea is now with the Naval Medical Center in Portsmouth, Va.

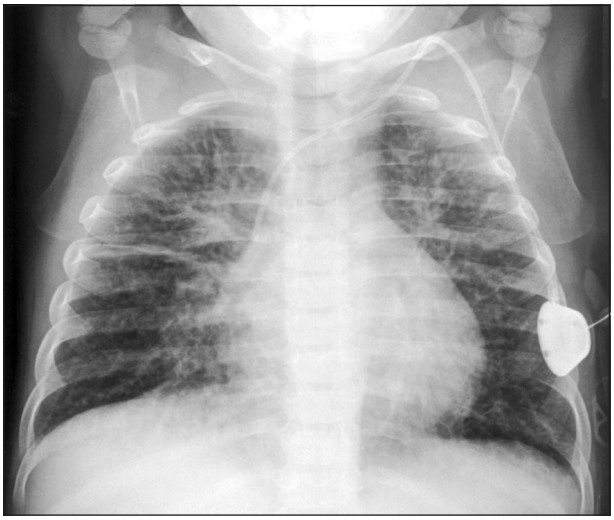

Figure 1.

Figure 2.

©2001 American Medical Association. All rights reserved.
Downloaded From: http://archpedi.jamanetwork.com/ on 10/13/2015

Denouement and Discussion

Pulmonary Air Embolus With Home Antibiotic Infusion

Figure 1. Chest radiograph showing intense pulmonary venous congestion with Kerley-B lines and septal thickening.

Figure 2. Normal pulmonary vascularity on chest radiograph repeated 16 hours later.

The patient was discharged from the hospital after maternal training in home antibiotic administration technique was reinforced. The occurrence of pulmonary embolism (PE) associated with use of CVCs is documented in the literature.[1-6] Most cases reported are related to events such as initial placement of the catheter, surgical procedures, or disconnection or breakage of the catheter. To our knowledge, no case of PE in connection with home use of a CVC has been reported. The pathophysiologic characteristics of the resulting clinical findings is a matter of debate, with the best comprehensive review of the topic by Orebaugh.[7] One insult thought to be responsible for symptoms is a block of right ventricular outflow by accumulated air bubbles. Microbubbles in the pulmonary circulation may lead to several vascular changes causing increased lymph flow in the lungs. The net effect of both mechanisms is pulmonary arterial hypertension, from which pulmonary edema may result. Mortality seems to be affected by the amount of air entering the circulation and the speed at which it enters.[8]

The clinical picture following PE can range from mild discomfort to severe cardiopulmonary collapse and death. Our patient experienced a brief episode of discomfort but was clinically well on presentation except for low oxygen saturation and abnormal findings on chest radiograph, both of which normalized rapidly. As she had had no recent pulmonary or other infectious symptoms prior to this incident, and her recovery was rapid without medical intervention other than oxygen, we surmised that her pulmonary findings were the result of an air bolus administered inadvertently by her mother, leading to pulmonary edema. Despite the relatively mild nature of her findings, she still required admission to a monitored hospital bed while the circumstances surrounding her condition were under investigation.

The medical and insurance communities are placing increasing emphasis on the use of home care options to decrease inpatient utilization and cost. A heavy burden is placed on family members who have no health care experience. This practice may place the patient at increased risk of complications that may not occur in the hospital. The risks and benefits of home care must be considered in addition to the financial implications. More importantly, family members performing medical tasks at home must be completely trained. Tasks should be reviewed periodically for optimal care of patients at home. Finally, physicians would be advised to consider a pulmonary embolus in the differential diagnosis of a patient receiving home medical care through a CVC and presenting with similar symptoms and radiographic findings.

Accepted for publication March 22, 2000.

This article was written by LCDR Timothy J. Porea, MC, US Navy, while a fellow at Texas Children's Hospital training in Pediatric Hematology-Oncology. The views expressed in this article are those of the author and do not reflect the official policy or position of the Department of the Navy, Department of Defense, or the US Government.

Reprints: Timothy J. Porea, MD, MPH, Department of Pediatrics, Naval Medical Center, 27 Effingham St, Portsmouth, VA 23708 (e-mail: tporea@mar.med.navy.mil).

REFERENCES

1. Leicht CH, Waldman J. Pulmonary air embolism in the pediatric patient undergoing central catheter placement: a report of two cases. *Anesthesiology*. 1986; 64:521-523.
2. Clark MC, Flick MR. Permeability pulmonary edema caused by venous air embolism. *Am Rev Respir Dis*. 1984;129:633-635.
3. Karr SB, Schwab FJ, Druy EM. Pulmonary air embolism: case report. *Cardiovasc Intervent Radiol*. 1991;14:250-251.
4. Waggoner SE. Case report: venous air embolism through a Groshong catheter. *Gynecol Oncol*. 1993;48:394-396.
5. Lam KK, Hutchinson RC, Gin T. Severe pulmonary oedema after venous air embolism. *Can J Anaesth*. 1993;40:964-967.
6. Fitchet A, Fitzpatrick AP. Central venous air embolism causing pulmonary oedema mimicking left ventricular failure. *BMJ*. 1998;316:604-606.
7. Orebaugh SL. Venous air embolism: clinical and experimental considerations. *Crit Care Med*. 1992;20:1169-1177.
8. Adornato DC, Gildenberg PL, Ferrario CM. Pathophysiology of intravenous air embolism in dogs. *Anesthesiology*. 1978;49:120-217.

©2001 American Medical Association. All rights reserved.
Downloaded From: http://archpedi.jamanetwork.com/ on 10/13/2015